

Marc Quirynen
Marc De Soete
Daniel van Steenberghe*

Review article

Infectious risks for oral implants: a review of the literature

Authors' affiliation:

Marc Quirynen, Marc De Soete, Daniel van Steenberghe, Catholic University of Leuven, Faculty of Medicine, Research Group for Microbial Adhesion, Department of Periodontology, School of Dentistry, Oral Pathology & Maxillo-facial Surgery, Leuven, Belgium

* Holder of the P. I. Brånemark chair for Osseointegration

Correspondence to:

Professor M. Quirynen,
Department of Periodontology
Catholic University Leuven
Kapucijnenvoer 33
B-3000 Leuven
Belgium
Tel: +32 16 33 24 07
Fax: +32 16 33 24 84
e-mail: Marc.Quirynen@med.kuleuven.ac.be

Key words: biofilm, dental plaque, implant therapy, dental implant, microbiology, oral implants, osseointegration, partial edentulism, periodontal disease, periodontal parameters, peri-implantitis, peri-mucositis, prevention, review, surface characteristics, susceptibility, microbial transmission, translocation.

Abstract: The use of oral implants in the rehabilitation of partially and fully edentulous patients is widely accepted even though failures do occur. The chance for implants to integrate can for example be jeopardised by the intra-oral presence of bacteria and concomitant inflammatory reactions. The longevity of osseointegrated implants can be compromised by occlusal overload and/or plaque-induced peri-implantitis, depending on the implant geometry and surface characteristics. Animal studies, cross-sectional and longitudinal observations in man, as well as association studies indicate that peri-implantitis is characterised by a microbiota comparable to that of periodontitis (high proportion of anaerobic Gram-negative rods, motile organisms and spirochetes), but this does not necessarily prove a causal relationship. However, in order to prevent such a bacterial shift, the following measures can be considered: periodontal health in the remaining dentition (to prevent bacterial translocation), the avoidance of deepened peri-implant pockets, and the use of a relatively smooth abutment and implant surface. Finally, periodontitis enhancing factors such as smoking and poor oral hygiene also increase the risk for peri-implantitis. Whether the susceptibility for periodontitis is related to that for peri-implantitis may vary according to the implant type and especially its surface topography.

The high clinical success rate of some implant designs in (partially) edentulous patients, as demonstrated in well-designed long-term prospective studies, has led to the widespread acceptance and use of oral implants (for review see van Steenberghe et al. 1999). Besides a number of patient-related factors such as smoking (Bain & Moy 1993), bone quality (Jaffin & Berman 1991; Hutton et al. 1995), systemic diseases or chemotherapy, surgical trauma or bacterial contamination during implant surgery are factors associated with early failures (impaired healing, i.e. during the healing

phase and thus before loading). Overload (defined as a situation in which the functional load applied to the implants exceeds the capacity of the bone-implant interface to withstand it) is another important cause of early implant failure, once the prosthesis is installed. Factors associated with late failures of implants are less well understood and seem to be related to both the peri-implant environment and host parameters. Lesions similar to those associated with teeth, such as peri-implantitis, gingival hyperplasia, fistulae and bone loss, are related to microbial plaque accumulation. The pres-

Date:

Accepted 22 January 2001

To cite this article:

Quirynen M, De Soete M, van Steenberghe D. Infectious risks for oral implants: a review of the literature
Clin. Oral Impl. Res. 13, 2002; 1–19

Copyright © Munksgaard 2002

ISSN 0905-7161

ent review will focus on peri-implantitis and the microbial factors associated with its prevalence.

Epidemiological studies from the late eighties indicated that there was no universal susceptibility to periodontitis. Only 5 to 20% of the population suffers from severe forms of periodontitis (Hugoson & Jordan 1982; Brown & Loe 1993). Late implant failures also cluster in a small subset of individuals (Tonetti 1998; Esposito et al. 1998). Weyant & Burt (1993) examined the survival rate of oral implants in a group of 598 consecutive patients from the U.S. Veterans Administration registry. Over a period of 5.5 years, a total of 81 implants out of 2098 were removed in 45 out of 598 subjects. The probability for the removal of a second implant increased by 30% in patients who had already lost one implant.

Impaired healing/early implant infection

An early implant failure or impaired healing corresponds to the inability to establish osseointegration. The latter is defined as a "direct structural and functional connection between ordered living bone and the surface of a load-carrying implant" (Brånemark 1985). Although an early failure can be caused by different factors (e.g. traumatic surgery, overheating during drilling, etc.), this paper will only deal with the role of bacteria. An early failure should however not be confused with peri-implantitis (see later), a term referred to as an "inflammatory process affecting the tissues around an osseointegrated implant in function, resulting in loss of supporting bone" (Albrektsson & Isidor 1994).

Per-operative contamination

Possible sources of direct bacterial contamination during surgery (infection of the implant or the bony socket) are: the surgical instruments, the gloves, the air in the operating room, the air expired by the patient, the saliva in the oral cavity and the peri-oral skin. Such infections can result in an abscess around an implant (Fig. 1), eventually accompanied by a fistula (Piattelli et al. 1995). The radiographic image after this type of infec-

tion, characterised by a "peri-apical" radiolucency around implants, should not be confused with scars resulting from drilling too apically or from heat-induced aseptic bone necrosis (Piattelli et al. 1998).

To prevent contamination from the oral cavity, several ideas have been proposed (Brånemark et al. 1985; Asmall 1986; Albrektsson et al. 1986; Babbush 1986; Haanaes 1990). The reduction of the salivary flow by atropine, the supine position of the patient, and the protection of the surgical plane by the orally pediculated flap can avoid contami-

nation of the wound, at least in the anterior part of the oral cavity and only if two distinct surgical aspirations are used (one for the wound and one for the oral cavity). Furthermore, the salivary microbial load can be reduced by 95% via a preoperative rinse with chlorhexidine (Altonen et al. 1976; Veksler et al. 1991). Disinfection of the peri-oral skin with a chlorhexidine-alcohol solution can only partially reduce the microbial load on this surface (van Steenberghe et al. 1997). To deal with the skin and mucosae of the nares, a perforated cap should be installed over the patient's nose (van

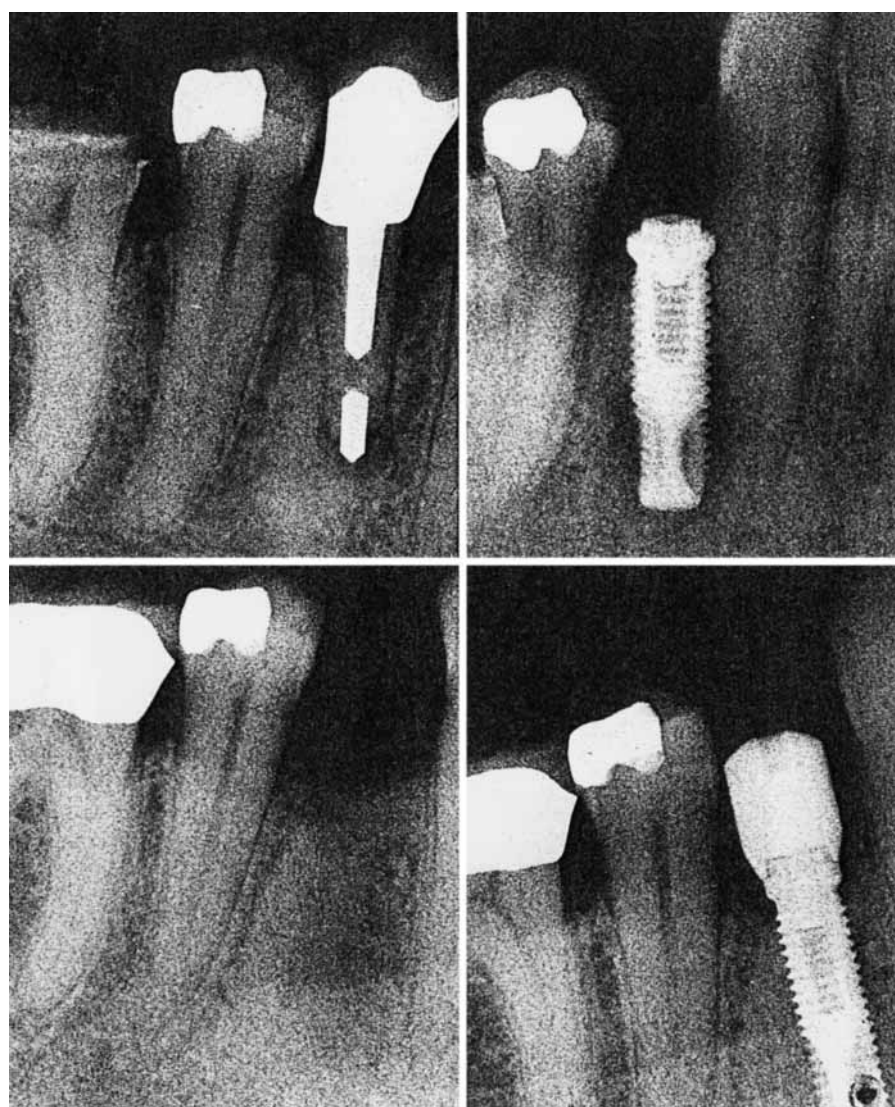


Fig. 1. An example of impaired implant healing. Some months after the extraction of premolar (upper left) with endodontic pathosis (peri-apical infection), a solitary implant was placed with good primary stability. During bone trepanation, remaining endodontic material was removed.

Six weeks after insertion (upper right) a local swelling appeared on top of the implant. The mobile implant was surrounded by granulation tissue and pus. A second trial, after proper healing (lower left), was successful (lower right).

Steenberghe et al. 1997). When all the above-mentioned precautions are taken, the administration of prophylactic antibiotics prior to implant placement (Dent et al. 1997) is no longer necessary. This is proven by our own observation that the incidence of non-integrating implants (circa 2%) or local infections did not increase when the routine administration of antibiotics was replaced by an occasional prescription (e.g. when wound contamination with saliva occurred because of uncontrolled jaw movements or coughing).

In a prospective multi-centre study on the use of osseointegrated oral implants in partially edentulous patients, the few early failures concentrated in subjects with high plaque and gingivitis indices. It was hypothesised that either per-operative contamination and/or airborne infections interfered with the osseointegration process, or that the concomitant gingivitis was responsible (van Steenberghe et al. 1990). Some people still believe that infection control during periodontal surgery is impossible, since performed in a contaminated area. This indicates confusion between contamination by eventually pathogenic commensals, and foreign (e.g. from other parts of the body) or exogenous bacteria. Therefore, even proctologic and gynaecological interventions do involve strict sterility measures.

Infected recipient site

Infections/inflammatory processes within the jawbone in the immediate vicinity of an integrating implant, such as peri-apical lesions (Sussman & Moss 1993) around neighbouring teeth, cysts and/or root remnants, or foreign bodies (e.g. endodontic material), can interfere with osseointegration. Shaffer and co-workers (1998) published a series of cases where the installation of an implant close to a tooth with endodontic pathosis (persisting or treated) resulted in a dramatic extension of that peri-apical lesion (Fig. 1) and a subsequent failure of the implant. Whether the direct extension of bacterial endotoxins, the inflammatory cells, or the bacteria themselves are responsible for the contamination of the implant remains unknown. A thorough examination of the radio-

graphs prior to implant insertion together with the evaluation of the vitality of neighbouring teeth is recommended. One should especially realise that radiographic findings do not always reflect the actual size of an inflammatory process (a peri-apical abscess, granuloma or cyst). Indeed, mechanically induced medullary defects in cadaver mandibles, for example, cannot be evidenced on traditional radiographs unless the defects reach the cortical bone (Bender & Seltzer 1961; Schwartz & Foster 1971; Regan & Mitchell 1962; Wengraf 1964; Merritt et al. 1984; Van der Stelt 1985). In a recent report, Farman and co-workers (1998) compared the accuracy of a panel of endodontists and oral diagnosticians in the estimation of the size of peri-apical radiolucencies on analogue or digital images (the latter with and without enhancement). Although better estimations were obtained with the digital/enhanced images, the underestimations still ranged from 0.5 to 2 mm (mesio-distal measurement) and from 2.5 to 4 mm (superior-inferior measurements). Finally, radiographic evaluation of peri-apical lesions is also jeopardised by the large variations in diagnostic abilities among observers (Goldman et al. 1974; Brynolf 1971). Peri-apical lesions are even missed on tomograms (Haring & Lind 1996).

Early infections

Signs of infections (swelling, fistulae and pain) during the healing period of a still submerged 2-stage implant can also be confined to the soft tissues. The most frequently reported causes are a residual suture, a poorly seated cover screw, or trauma from an inadequately relieved denture, a protruding implant or trauma by antagonistic teeth (Worthington et al. 1987; Lekholm et al. 1985; Esposito et al. 1999).

Peri-implantitis

The causal relationship between bacterial plaque accumulation and gingivitis or periodontitis is well established (Løe et al. 1965; Slots 1977; Listgarten & Helldén 1978; Slots et al. 1978). Certain bacteria have been isolated in signifi-

cantly larger quantities from diseased periodontal sites than from healthy sites (Loesche & Syed 1978), and have been called periodontopathic (Slots & Rams 1991; Socransky & Haffajee 1992; Wolff et al. 1994).

Animal studies on peri-implant mucositis and peri-implantitis

The tissue response to microbial build-up around teeth and oral implants has been investigated in several animal experiments (for review see: Schou et al. 1992; Mombelli & Lang 1998; Berglundh 1999).

Gingivitis versus peri-implant mucositis

Several papers (Berglundh et al. 1992; Leonhardt et al. 1992; Ericsson et al. 1992; Abrahamsson et al. 1998a) compared, after a period of undisturbed plaque formation, the microbiological and histological changes of the gingiva around both teeth and implants within the same animal. During plaque formation the microbial composition shifted around both abutment types towards a higher proportion of periodontopathogens, including motile organisms and spirochetes. Biopsies also indicated a similar inflammatory infiltrate around teeth and abutments (size, location, composition) (Berglundh et al. 1992; Leonhardt et al. 1992). If the period of undisturbed plaque formation was extended to 3 months, the infiltrated connective tissue in the peri-implant mucosa had a similar composition as around the teeth, but it extended further apically (Ericsson et al. 1992). Abrahamsson and co-workers (1998a) even prolonged the plaque accumulation period to 5 months and reported similar soft tissue inflammatory reactions around 3 examined implant systems (Astra Tech, Brånemark system and ITI). None of the above-mentioned studies resulted in peri-implantitis.

Pontoriero and co-workers (1994) even repeated the classical experimental gingivitis model (3 weeks of undisturbed plaque formation, Løe et al. 1965) in humans (20 partially edentulous patients rehabilitated by means of implants). During the 3-week period that the subjects refrained from oral hygiene, the degree of gingivitis increased com-

Table 1. Microbiota around successful and failing implants. Considered are: dark field microscopy data (proportions), the number of colony forming units (CFU); anaerobic and aerobic growth conditions and their ratio), the proportion of Gram-negative anaerobic rods, and culture data (detection frequency or proportion) and sorted by intra- or inter-patient comparison

Authors	Type	Number		Oral status	Info implant			Darkfield microscopy in %					CFU 10 ⁶ or %					Specific bacteria: % flora/freq.				
		sub	imp		Design	T	Cause	ppd	Cocci	Other	Motile	Spiro	Anae	Aer	% G-ve	Aa	Pg	Pi	Fn			
Mombelli et al. 1987	ITI hc	7	8	f.	intra	Fi	p, s, r	8.5	48.7	32.0	7.9	11.4	85.6%	14.4%	42.1	0% ^c	0%	5.7%	15.3%			
		6	6			S		3.0	59.5	34.4	4.8	1.3	54.5%	45.5%	23.4	0%	0%	1.1%	7.0%			
Alcoforado et al. 1990	Brå	5	10	f.	inter	S		3.8	82.1	16.6	1.3	0	51.4%	48.6%	15.4	0%	0%	0.9%	6.5%			
Mombelli & Lang 1992	ITI hc	6	10	f./p.	/	Fi	?/p, r or s						15.8			0/10 ^c	0/10	4/10	3/10			
	/B	9	9		intra	Fi	c, r, p	5.9	—	—	7/9	4/9	3.45	0.85	39.8	1/9 ^c	5/9	5/9	7/9			
Sbordone et al. 1995	?	13	18	p.	/	Fi	p, r, s/m, rr	≤3	—	—	—	0/9	0.96		19.0	0/9	5/9	4/9				
Aughthun & Conrads 1997	IMZ	12	18		/	Fi	r > 5 mm (st)	6.4	42.1	40.0	12.3	5.6			50.4	0/13 ^c	8/13	10/13	13/13			
Leonhardt et al. 1999	Brå	29	29	p.	inter	Fi	r > 3th								16/18 ^c	—	5/18	4/18				
		35	35			S									9/29 ^c	1/29	19/29					
Becker et al. 1990	Brå	8	8	f.	inter	Fi									1/35	1/35	9/35					
		16	16			S									1/8 ^c	2/8	3/8					
Rosenberg et al. 1991	Brå/ Vent	3	5		/	Fi	m, rt, E2	6.7							0	0	0					
		11	12	f./p.	intra/	Fi	s, m, rr, p, E1/2		30.3	24.0	21.5	24.2			3/12 ^c	7/12	12/12	8/12				
		20	20		inter	Tr	m, rt		52.8	43.9	1.6	1.8			0/20	1/20	5/20	2/20				
Overall mean				f./p.		S			71.3	25.1	1.6	1.8			0	0	0	<				
									45.4	36.0	10.1	8.5			26/78	11/60	41/78	20/41				

System: ITI hc=Ti plasma-coated hollow cylinder, B=Bonelit; Brå=Brånemark, Vent=Core, Screw or Swede Vent; sub=subjects, Imp=implants; Oral status: f=fully edentulous, p=partially edentulous. Implant info: Fi= failure due to infection, S= successful implant, Tr=failure due to trauma. Cause=parameters for infected implants: ?=questionable definition, c=10⁶ CFU anaerobes, m=mobility, p=ppd > 5 mm, r=radiographic detectable alveolar bone loss, rr=radiographic peri-implant radiolucency, s=suppuration, E1=implant loss before/at second stage surgery, E2=implant loss soon after prosthesis insertion (the latter should be considered as initial non-integration), st=soft tissue sample. Microbial analyses: c=culture, d=dna. Aa=Actinobacillus actinomycescomitans, Pg=Porphyromonas gingivalis, Pi=Prevotella intermedia, Fn=Fusobacterium nucleatum.

parably for both abutment types (including swelling of soft tissues; ±1 mm increase in probing depth and ±1 mm reduction in recession).

Periodontitis versus peri-implantitis

Another series of animal studies compared the clinical, histological and microbiological changes around teeth with those around implants, after enhanced plaque accumulation caused by means of subgingival ligatures (Hickey et al. 1991; Lindhe et al. 1992; Leonhardt et al. 1992; Schou et al. 1993, 1996; Lang et al. 1993; Akagawa et al. 1993; Ericsson et al. 1995; Tillmanns et al. 1997, 1998; Hanisch et al. 1997; Eke et al. 1998). The placement of these ligatures nearly always resulted in a dramatic marginal bone destruction around both teeth and implants. The respective connective tissue lesions around ligated implants extended directly into the bone, whereas around teeth intact periodontal fibres usually separated both lesion and bone. These soft and hard tissue changes (clinically characterised by increased probing depth and severe loss of “attachment”) were associated with significant shifts in the composition of the subgingival flora including:

- increase in the total viable counts (in comparison to health, for gingivitis around implants and teeth ×8 and ×30 respectively, for peri-implantitis ×60 and periodontitis ×100),
- increase in the proportion/detection frequency of *Porphyromonas gingivalis*, *Prevotella intermedia*, *Fusobacterium nucleatum* species (from below 1% to >10% respectively); the data on *Actinobacillus actinomycescomitans* are contradictory,
- decrease in the proportion of Streptococci (from 40% and 60% to 0.2% and 0.5% around implants and teeth respectively),
- decrease in the proportion of all cocci and dramatic increase in the proportion of motile organisms and spirochetes,
- increase in the proportion of Gram-negative anaerobic rods.

Between teeth and implants, however, significant differences in microbiology

could never be detected for any of the above-mentioned conditions.

Experimental marginal tissue breakdown around implants, induced by subgingival ligature placement, seems to have microbial similarities with periodontitis. This can suggest that peri-implantitis is induced and promoted by the same mechanisms as in periodontitis. It is however also possible that the deepened pockets, easily created with ligatures around implants, have favoured this microbial shift. The lack of cementum with inserting collagen fibres around implants (where they run parallel to the titanium surface, for review see Berglundh 1999), could indeed enable a more rapid down-growth of plaque and epithelium than around teeth. Moreover, the firm contact between ligatures and tissues (especially around implants) could also have induced a foreign body reaction (a non-specific inflammatory response), which is somewhat different from chronic adult periodontitis. Indeed, Rovin and co-workers (1966) reported that the periodontal breakdown in rats after ligature insertion even around teeth was partially due to the local irritation by the ligature. The latter rather mimics the acute foreign body reaction in patients after subgingival penetration of, for example, a toothpick splinter. Under these conditions also, teeth showed an extreme inflammatory process accompanied by rapid bone loss. The misleading role of ligatures is also underlined by a study of Klinge (1991), in which the installation of the ligatures was, in contrast to the above-mentioned studies, not forceful. The corresponding bone loss around Brånemark implants with ligatures in this study remained around 1 mm versus 5 mm for ligated teeth. The latter may explain the apparent discrepancy between animal studies and clinical observations. The hypothesis of a foreign body reaction is also supported by the observations of Warrer and co-workers (1995), who reported a pronounced crestal bone loss when ligatures were placed around implants without surrounding gingiva (a condition in which the resistance to an apical migration of the ligature is very low so that the chance for a foreign body reaction increases). Moreover, the similarity in subgingival load around ligated

teeth and implants, while the amount of bone loss around the implants is much higher, indicates that other factors are responsible for peri-implantitis. In nearly all animal studies, implants with ligatures showed, both clinically as well as histologically, more bone loss than implants with massive plaque accumulation but without ligatures (Schou et al. 1993; Warrer et al. 1995). Finally, one should realise that upon removal of the ligatures from the deep pockets, a distinct healing process occurs although the pathogenic species remain. This healing is characterised by a separation of the inflammatory cell infiltrate in the peri-implant mucosa from the alveolar bone by a dense, about 1 mm wide, connective tissue capsule (Marinello et al. 1995). Thus only the removal of the ligature (like after removal of a foreign body) converts the active destructive lesion in a resting non-aggressive lesion.

Clinical data

Subgingival flora around failing implants

Table 1 summarises the most significant microbiological data on failing implants. A distinction was made between early failures (implant loss within first 6 months of function, probably representing already initially non-integrated implants) and initially well-integrated implants demonstrating progressive marginal bone loss. These data should be compared to data from successful implants in both partially and fully edentulous subjects (Tables 2, 3 and 4). Healthy peri-implant pockets are colonised by high proportions of coccoid cells, a low ratio anaerobic/aerobic species, a low number of Gram-anaerobic species, and low detection frequencies for periodontopathogens (Adell et al. 1986; Lekholm et al. 1986a; Bower et al. 1989; Ong et al. 1992; George et al. 1994, see also Tables 2, 3 and 4). Mombelli and co-workers (1987) evaluated fully edentulous patients with overdentures on 2 or 4 hollow cylinder titanium implants with a plasma-sprayed surface (ITI). They compared 5 subjects with only successful implants (pockets \leq 5 mm and no marginal bone loss) with 7 subjects with both successful and failing implants (probing depth \geq 6 mm, radiographically detectable bone loss, suppuration). Failing implants harboured a higher pro-

portion of anaerobic species (6/1 ratio anaerobic/aerobic), of motile organisms (8%) and spirochetes (11.5%) and of *P. intermedia* and *Fusobacterium* species. Leonhardt and co-workers (1999) examined the microbiota around successful and failing (defined as ongoing bone loss beyond the 3rd thread) Brånemark system implants (inter-subject comparison), in both fully and partial edentulous patients. Failing implants harboured more frequently *A. actinomycetemcomitans*, *P. gingivalis* and *P. intermedia*, especially in partially edentulous patients. Similar findings were reported by Augthun & Conrads (1997) for failing IMZ implants (cylindrical, plasma-sprayed titanium) with, however, a high detection frequency for *A. actinomycetemcomitans* (16/18), by Sbordone and co-workers (1995) and Listgarten & Lai (1999) for different implant types and by Sanz and co-workers (1990) for sapphire implants.

The peri-implantitis data published by Rosenberg and co-workers (1991) or Becker and co-workers (1990) should be interpreted with some caution since most failures, including mobility assessment as a criterion (Table 1), occurred before or shortly after insertion of the final prosthesis and could represent cases of undiagnosed non-integration. Rosenberg and co-workers (1991) claim distinct differences between bacterial profiles of infected and overloaded implants. The latter were characterised by the absence of motile rods, spirochetes and classical periodontopathogens and a predominance of Gram-positive organisms similar to what is observed in periodontal health. This claim means that dark field microscopy could be a helpful tool for the differentiation between peri-implantitis and overload as the cause of implant loss. Other papers also support these observations (Quirynen & Listgarten 1990).

In a longitudinal study, a single implant with clinical signs of peri-implantitis could be followed over time (Mombelli et al. 1988). In comparison to the successful implants, the failing implant (pocket of 6 mm and pus formation) harboured shortly after installation 2 logs more anaerobic CFU (colony forming unit) species, fusiforms (>10%), motile rods (>9%), an initial increase in *Actinomyces odontolyticus* followed by

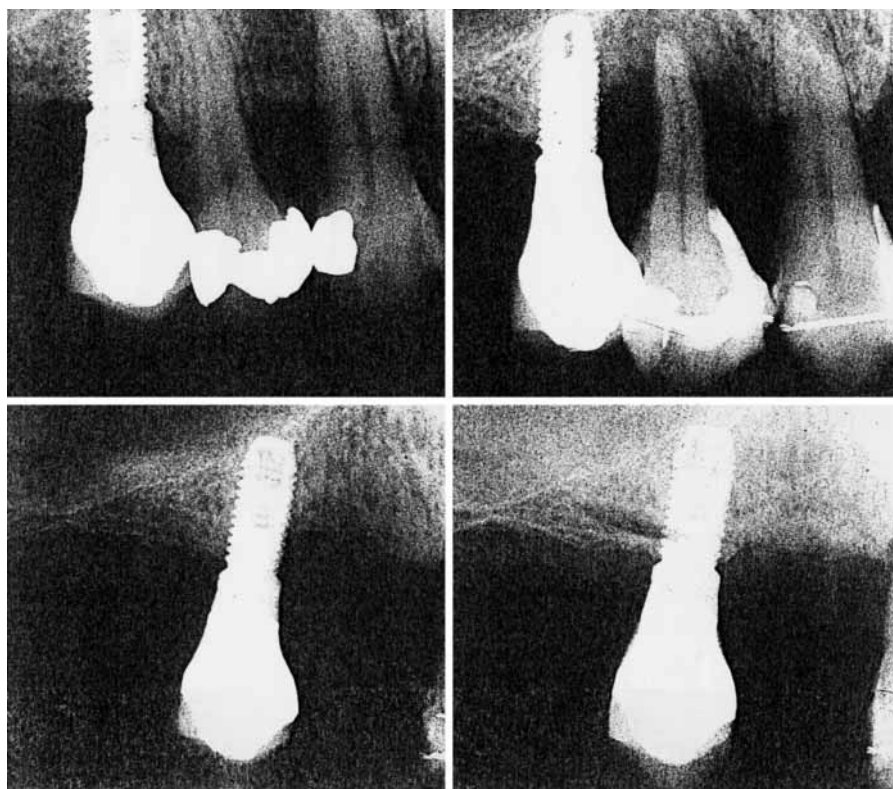


Fig. 2. An example of the resistance to peri-implantitis of screw-shaped implants with a machined surface (Brånemark system). Radiographs of a patient (partially edentulous upper jaw rehabilitated with Brånemark implant) suffering from rapidly progressing periodontitis but without signs of peri-implantitis. Upper left: radiograph from both implant (position 15) and neighbouring teeth in 1989, this is some years after

insertion. Upper right: situation in March 1997 with severe marginal bone loss around teeth and mesially of the implant (the latter however did not show an increased probing depth); the 14 had to be extracted. Lower left: detailed image from solitary implant, 6 months after extraction of neighbouring tooth. Lower right: radiograph 18 months after extraction with remineralisation of bone around implant.

an increase in *Fusobacterium* counts and spirochetes (from the moment of pus formation).

Implants with peri-implantitis thus reveal a complex microbiota encompassing conventional periodontal pathogens. They confirm the bacterial shifts detected in animal studies after the induction of experimental peri-implantitis. Species such as *A. actinomycetemcomitans*, *Peptostreptococcus micros*, *Campylobacter rectus*, *Fusobacterium* and *Capnocytophaga* are often isolated from failing sites, but can also be detected around healthy peri-implant sites (see later, Table 2). These bacteria are commonly associated with progressive periodontitis and possess virulence factors, which could be pertinent to peri-implantitis (Slots & Genco 1984). Other species such as *Pseudomonas aeruginosa*, *Enterobacteriaceae* species, *Candida*

albicans or staphylococci are also frequently detected around implants (Alcforado et al. 1990). These organisms are uncommon in the subgingival area, but have been associated with refractory periodontitis (Slots & Rams 1991). High proportions of *Staphylococcus aureus* and *Staphylococcus epidermidis* have been reported in other papers on oral implants (Rams et al. 1990). The relative resistance of these organisms to commonly utilised antibiotics (Slots et al. 1988), suggests that their presence might represent an opportunistic colonisation secondary to systemic antibiotic therapy.

The above-mentioned observations are somehow in contrast with the data of Salcetti and co-workers (1997) who were not able to detect "significant" differences in subgingival microbiota between successful and failing implants within

the same patient. Still, patients with failing implants showed higher detection frequencies for: *P. micros*, *Prevotella nigrescens* and *F. nucleatum*.

Treatment studies

The therapeutic outcomes of therapies for peri-implantitis can underline the role of specific bacteria in the aetiology of this infection. Strategies that aimed to reduce the anaerobic bacteria, either by mechanical debridement of the peri-implant pocket, or with local or systemic antibiotics indeed improved the clinical conditions (for review see Ericsson et al. 1996; Mombelli & Lang 1998; Esposito et al. 1999; Mombelli 1999). The combination of debridement with systemic use of ornidazole (Mombelli & Lang 1992), amoxicillin in combination with metronidazole (Ericsson et al. 1996) or tetracycline fibre placement (Flemmig 1994) seem very promising. These studies propose the following requirements for the treatment of peri-implantitis:

- reduction of bacterial colonisation on implant surface,
- removal of bacterial mass (mechanically),
- introduction of an ecology (more aerobic condition via pocket resection) that suppresses the anaerobic segment of the subgingival flora.

A number of reports documented the clinical and radiological assessment of successful regenerative treatment of peri-implantitis lesions (Jovanovic 1993; Lehmann et al. 1992; Hämmerle et al. 1995; Mattout et al 1995). However, histological evidence of a true re-osseointegration, i.e. the reestablishment of an intimate bone-to-implant contact, on a previously infected surface in man and in animals is still lacking (Jovanovic et al. 1993; Persson et al. 1999; Wetzel et al. 1999).

Susceptibility for peri-implantitis versus periodontitis

Malmstrom and co-workers (1990) reported on a partially edentulous patient who was rehabilitated by implants after an unsuccessful treatment of a rapidly progressive, early onset periodontitis (the anamnesis included smoking and a chemotactic defect in the patient's neu-

Table 2. Intra-subject comparison of subgingival flora around implants and teeth in partially edentulous patients. Considered are: dark field microscopy data (proportions), and culture data (detection frequency for specific bacteria)

Authors	System	Number		Abutment	Time	PPD	Bacterial morphotypes in %				Detection frequency specific bacteria				
		sub	site				Cocci	Other	Motile	Spiro	bacteria				
											Aa	Pg	Pi	Fn	
Lekholm et al. 1986a	Brå	10	10	Implant	18 m	3.3	30.7	45.0	25.0	0	0 ^c	0	0	0	0
Apse et al. 1989	Brå	10	10	Tooth		2.3	17.8	54.4	23.5	0.9	0	0	0	0	0
		15	28	Implant	16 m	3.5	87	8	3	4	1/28 ^c	5/28	1/28		
Quirynen & Listgarten 1990	Brå	19	19	Tooth		2.6	87	7.5	4	9	3/19	1/19	1/19		
		24	24	Implant	>1 y	2.9	65.8	29.8	2.3	2.1					
Koka et al. 1993	Brå	24	24	Tooth		2.7	56.6	34.9	4.9	3.6					
		4	10	Implant	1 m						–	2/4 ⁱ	2/4	1/4	
Leonhardt et al. 1993	Brå	63	63	Tooth							–	3/4	3/4	1/4	
		19	19	Implant	3 y	2.2					4/17 ^c	4/17	9/17		
Kohavi et al. 1994	Brå	29	29	Tooth		2.7					5/17	8/17	11/17		
		16	29	Implant	>6 m	3.1					9/29 ^c	20/29			
Mombelli et al. 1995	ITlb / Brå	20	20	Implant	6 m	3.5			15	25	11/29	16/29			
		80	80	Tooth					23	28	1/80	6/80	32/80	41/80	
Papaioannou et al. 1996	Brå	3 A	2	Implant		4.7	40.0	46.3	12.5	1.2	0/2 ^d	0/2	0/2	2/2	2/2
		3 R	3	Tooth		7.3	13.0	47.0	21.5	18.5	0/3	3/3	1/3	2/3	2/3
Mengel et al. 1996	Brå	5	36	Tooth		5.5	38.5	30.5	21.5	10.0	0/2 ^d	2/2	2/2	2/2	2/2
		36	36	Implant	12 m	8.3	21.5	29.5	25.0	24.0	0/3	3/3	3/3	3/3	3/3
Sbordone et al. 1999	Brå	25	42	Implant	2 y	3.3	79.9	8.2	10.7	1.3	0 ^d	0	1/5	–	–
		42	42	Tooth			80.8	9.5	9.4	0.2	0	0	1/5	–	–
Hultin et al. 2000	Brå	15	43	Implant	10 y	1.9	80.5	14.0	5.0	0.5	3/25 ^c	10/25	4/25	4/25	4/25
		43	43	Tooth		3.0	76.3	15.7	5.2	2.8	4/25	5/25	3/25	1/25	1/25
Overall mean			31	Tooth		1.5	60.3	26.0	11.4	2.7	21/181	52/185	34/156	33/96	33/96
Standard deviation				Implant			23.4	16.3	9.0	3.5					
Overall mean				Tooth			50.4	28.4	13.4	8.4	24/222	48/226	58/197	54/146	54/146
Standard deviation							32.3	18.4	9.5	9.3					

System: ITlb=Bonelit, Brå=Brånemark system; sub=subjects (A=adult, R=rapidly progressing periodontitis), Time=loading time for implants in months (m) or years (y); PPD= pocket probing depth; Bacterial morphotypes: spiro=spirochetes; Microbial analyses: ^c= culture, ^d=dna, ⁱ=immunoblot assay.

trophils). Within the first 2 months of subgingival healing, 3 maxillary and 1 mandibular implant had to be removed due to recurrent abscesses. A comparable case was presented by Fardal and co-workers (1999).

Afterwards, many authors misquoted the first paper, to prove that patients susceptible to periodontitis are also susceptible to peri-implantitis. Several other publications, however, proved the opposite. Nevins & Langer (1995) published data on the survival rate of Brånemark system® implants (with a machined surface) in a group of partially edentulous patients with a clinical diagnosis of recalcitrant periodontitis (defined as no positive response to routine periodontal therapy and continuing loss of periodontal support). In contrast to what could be expected, both the survival rate and the stability of the peri-implant tissues were comparable to what is generally reported for that implant system. Comparable observations were made in 2 papers from our group. In a first study, 5 partially edentulous patients with rapidly progressive periodontitis were rehabilitated by means of Brånemark system® implants (Fig. 2). The aggressive marginal bone loss around the teeth (0.45 mm/year) was not reflected by signs of peri-implantitis around the implants (0.05 mm bone loss/year) in the immediate vicinity (van Steenberghe et al. 1999a). Fig. 2 shows even a remarkable regeneration/remineralisation of peri-implant bone after extraction of a neighbouring tooth with terminal periodontitis. In a second study (Quiryne et al. 2001), a randomly selected group of partially edentulous patients rehabilitated with Brånemark system® implants for at least 5 years, were screened for bone loss around teeth and implants. Previous (before implant installation) or ongoing bone loss around teeth (scored clinically and/or radiographically) could not be correlated with bone loss around the implants. These data, together with the observations in long-term clinical studies (Adell et al. 1981, 1986; van Steenberghe et al. 1990, Lindquist et al. 1997), indicate that some implant configurations and surfaces may be more resistant to loss of "attachment" than teeth.

These observations are, however, in

contrast to reports on implants with a rougher surface. Ellegaard and co-workers (1997) followed Astra and ITI system implants inserted in periodontally compromised partially edentulous patients (defined as subjects with tooth loss due to progressive periodontitis but who had received a thorough periodontal therapy). About 76–86% of the implants, depending on the implant type, remained free from radiographic bone loss ≥ 1.5 mm at 36 months. After 5 years of loading, 45% of the ITI implants displayed marginal bone loss of 1.5 mm or more even though all patients participated in a periodontal supportive care program. Comparable data were reported in a recent longitudinal multi-centre study on the same implant type (Brocard et al. 2000). The comparison of these results with those obtained for a population at low risk for periodontitis and using the same implant system (Buser et al. 1997), suggests that some implant types inserted in patients prone to periodontitis may pose an increased risk for marginal soft and hard tissue problems.

Factors influencing the subgingival microbiota around implants

The presence of teeth and their periodontal status

Bacteria that normally reside in the oral cavity (i.e. the indigenous microbiota) can select from different ecosystems for their habitat. On the basis of physical and morphological criteria, the oral cavity can be divided into five major ecosystems (also called niches), each with distinct ecological determinants: the buccal epithelium, the dorsum of the tongue, the supragingival tooth surface, the periodontal pocket (with its crevicular fluid, the root cementum and the pocket epithelium) and the tonsils. Most pathogenic species (with the exception of spirochetes who limit themselves to the pocket) are able to colonise all these niches (Petit et al. 1994; von Troil-Lindén et al. 1995; Danser et al. 1994, 1996). Some periodontopathogens (*F. nucleatum* and *P. intermedia*) are involved in the aetiology of tonsillitis (Brook et al. 1997), while others can even colonise

the maxillary sinus (Wald 1998). Even in the edentulous mouth of infants or of denture wearers, the proportions of periodontopathogens – with the exception of *A. actinomycetemcomitans* and *P. gingivalis* (Könönen et al. 1992; Danser 1996) – can be high. Since most pathogens are found in more than one niche, it is reasonable to assume that transmission between these intra-oral niches (called translocation) occurs. The existence of such a translocation was illustrated by the clinical and microbiological benefits of a one-stage full-mouth disinfection or a one-stage full-mouth root planing when compared to a standard (quadrant per quadrant) periodontal therapy (Quiryne et al. 1999a; Mongardini et al. 1999; Quiryne et al. 2000). It also explains why guided tissue regeneration is more successful when performed in an oral cavity with a reduced microbial load (Nowzari et al. 1996; Slots et al. 1999) and why the application of local antibiotics is especially successful when all pathogenic pockets are involved in the therapy (Mombelli et al. 1997). In all these conditions, the elimination of most pathogenic species from the oro-pharyngeal cavity within a short period of time significantly reduced the chance for intra-oral bacterial translocations. Periodontal pockets play a crucial role as a microbial reservoir. Indeed, after a total tooth extraction, most periodontopathogens disappear from the oral cavity (Danser et al. 1994).

Such an intra-oral translocation of bacteria of course explains why pathogenic species originating from the periodontal pockets will colonise the peri-implant pockets in partially edentulous patients. Indeed, studies in the early nineties by Apse and co-workers (1989), and Quiryne & Listgarten (1990) illustrated that the remaining teeth in partially edentulous patients act as "reservoirs" for the colonisation of recently installed implants (Table 2). This similarity in microflora between teeth and implants in partially edentulous patients has since been confirmed by several studies, especially when the probing depth around both abutment types was comparable (Table 2). The proportion of spirochetes and motile organisms around both abutment types are similar as well as the number of colony forming

Table 3. Subgingival flora around implants in fully edentulous patients. Considered are: dark field microscopy data (proportions), and culture data (detection frequency for specific bacteria)

Authors	System	Number		Time	PPD	Bacterial morphotypes in %				Detection frequency specific bacteria			
		sub	imp			Cocci	Other	Motile	Spiro	Aa	Pg	Pi	Fn
Mombelli et al. 1988	ITI hc	4	8	6 m		94	6	0	0	0/8 ^c	0/8	1/8	2/8
Apse et al. 1989	Brå	6	13	44 m	3.0	84	6	8	4	0/13 ^c	0/13	0/13	
Quirynen & Listgarten 1990	Brå	11	11	>1 y	2.6	71.3	28.4	0.4	0				
Mombelli & Mericske-Stern 1990	ITI hc	18	36	>2 y	2.9	83	11	6	0	0/34 ^c	0/34	4/34	4/34
Papaoiannou et al. 1995	Brå OD	108	198	30 m	3.1	67.7	31.5	0.7	0.1				
Papaoiannou et al. 1995	Brå FFP	30	63	44 m	3.6	57.7	38.3	2.8	1.2				
Danser et al. 1997	Brå/IMZ	20	91	5.6 y	3.6					0/20 ^c	0/20	2/20	20/20
Overall mean						76.3	20.2	3.0	0.9	0/75 ^c	0/75	7/75	26/62
Standard deviation						13.1	14.2	3.3	1.6				

System: ITI hc=Ti plasma-coated hollow cylinder, Brå=Brånemark system (OD=overdenture, FFP=full fixed prostheses); sub=subjects, imp=implants; Time=loading time for implants in months (m) or years (y); PPD=pocket probing depth; Bacterial morphotypes: spiro=spirochetes; Microbial analyses: ^c=culture.

units. Even in the detection frequency of pathogenic species only minor differences between both abutment types could be detected (Table 2). This similarity appears soon after implant insertion. Leonhardt and co-workers (1993) detected periodontopathogens in the subgingival peri-implant environment, already 1 month after abutment connection. All studies in Table 2 corroborate the concept that the microflora present in the oral cavity before implant insertion determines the composition of the newly established microflora around implants. The latter was also confirmed in a study where the presence of 23 subgingival species around both teeth and implants was examined via whole genomic DNA probes in a checkerboard assay (Lee et al. 1999a).

The periodontal status of the remaining teeth influences the composition of the subgingival flora around implants (Quirynen et al. 1996a). When 31 partially edentulous patients with different periodontal conditions for natural dentition were examined, phase-contrast microscopy confirmed the transmission hypothesis. Going from healthy over chronic to refractory periodontitis, the number of coccoid cells significantly decreased in pockets around both teeth and implants, whereas the number of spirochetes and motiles significantly increased for both abutment types even above the 20% threshold level for dis-

ease (Listgarten et al. 1986). A DNA analysis showed an absence of the most suspicious periodontopathogens (*P. gingivalis*, *Treponema denticola* and *C. rectus*) in the healthy group, but a frequent detection of them around both teeth and implants in the chronic and especially in the refractory group, at least in deep pockets (Quirynen et al. 1996a). Sanz and co-workers (1990) examined partially edentulous patients rehabilitated with endosteal sapphire ceramic implants and observed significantly higher numbers and percentages of suspected periodontopathogens around implants and teeth with signs of gingival inflammation. In these diseased sites, the proportion of Gram-negative anaerobic rods increased to 40%.

When partially edentulous patients are compared to fully edentulous patients (without remaining teeth in both jaws but rehabilitated with implants), the impact of remaining teeth becomes even more striking. Rehabilitated fully edentulous patients (Table 3) are characterised by significantly lower proportions of motile organisms (3% vs. 11.4%) and spirochetes (0.9% vs. 2.7%) and very low detection frequencies for pathogenic species (Mombelli et al. 1988; Apse et al. 1989; Quirynen & Listgarten 1990; Mombelli & Mericske-Stern 1990; Papaoiannou et al. 1995; Danser et al. 1997). In these 6 studies on fully edentulous patients rehabilitated

with implants, *P. gingivalis* and *A. actinomycetemcomitans* could never be detected (0/75). The detection frequency for *P. intermedia* (7/75) seems also reduced but not for *F. nucleatum*. Lee and co-workers (1999b) examined the microbiota (using whole genomic DNA probes) of the tongue, teeth (if present) and implants, pre- and post-implantation in partially and fully edentulous patients. They observed a great similarity in plaque composition between samples from the 3 above-mentioned niches and concluded that, besides the teeth, the tongue should also be considered as an additional bacterial source. The similarity in subgingival plaque composition was the greatest between implants and neighbouring teeth. The observation that implants in fully edentulous patients harbour a subgingival flora similar to that of the adjacent mucosal surface was also confirmed by a study from Danser and co-workers (1997). Smedberg and co-workers (1993) examined 18 subjects with a removable denture in the maxilla and could not detect significant differences in the pattern of microbial composition of the peri-implant pocket and that of the biofilm on the corresponding mucosal side of the maxillary prosthesis.

All data corroborate the concept that the bacteria colonising implants in edentulous patients originate primarily from the surface of the oral mucous mem-

branes; i.e. the microbiota present in the oral cavity before implantation. Several studies indicated that, already one month after a full dental extraction, *A. actinomycetemcomitans* and *P. gingivalis* could no longer be detected (Danser et al. 1994, 1997). The data in Table 3 also suggest that, even after the replacement of the teeth by implant-supported prostheses, *A. actinomycetemcomitans* and *P. gingivalis* remain below detection level or have permanently disappeared from the oral cavity. During treatment planning this can be an argument to extract a tooth with advanced periodontitis, since the pocket could act as a reservoir for pathogenic species colonising the implants.

Probing pocket depth

During abutment installation (two-stage implants) or during implant insertion (one-stage systems), the periodontologist decides upon the future peri-implant pocket depth by trimming more or less the mucoperiosteal flap and/or by the use of a post-surgical healing pack to maintain some pressure during healing. So far, the importance of the probing pocket depth around oral implants has not received much attention. Recently, Papaioannou and co-workers (1995) examined the relationship between the subgingival flora around successful implants and their periodontal parameters. Plaque samples from 561 implants were analysed by means of differential phase-contrast microscopy (DPCM), and compared to the sample site's probing depth, bleeding tendency on probing, and plaque and gingivitis indices. From these clinical parameters only the probing depth was found to be closely related to the pathogenicity of the flora; the deeper the pocket, the higher the proportion of spirochetes and motile organisms. In an additional study, it was observed that the subgingival flora around implants in partially edentulous patients with chronic periodontitis remained apathogenic as long as the pockets were below 4 mm in depth (Quiryne et al. 1996a). These observations were consistent with studies pointing to a positive correlation between the probing depth around teeth and the proportion of spirochetes (e.g.

Listgarten & Helldén 1978; Listgarten et al. 1986).

The impact of the probing depth on the subgingival microbiota was also reported for the one-stage ITI implants by Mombelli & Mericske-Stern (1990). They observed that the relative proportion of *Capnocytophaga* and *A. odontolyticus* around implants, supporting overdentures in edentulous patients, correlated positively with the probing depth. Others reported (for different implant systems) a positive correlation between probing depth and the occurrence/proportion of spirochetes (Keyes & Rams 1983; Lekholm et al. 1986b; Palmisano et al. 1991), BANA hydrolysing bacteria (Palmisano et al. 1991) or anaerobic species (Krekeler et al. 1986; Keller et al. 1998). George and co-workers (1994) reported a positive correlation between probing depth and/or intra-oral exposure time and the presence of *P. gingivalis*, *P. intermedia* and *A. actinomycetemcomitans*. These observations should encourage the periodontologist to prevent the presence of deep peri-implant pockets during second-stage surgery, at least when aesthetics and phonetics allow. The trimming of the soft tissues should however not go beyond 3 mm since, in animals at least, the existence of a minimal biologic width has been well documented (Berglundh & Lindhe 1996).

Surface roughness of transmucosal part of the implant

Scanning electron microscopy (SEM) clearly revealed that the initial colonisation of an intra-oral hard surface starts from surface irregularities (such as cracks, grooves, or abrasion defects) and subsequently spreads out from these areas as a relatively even monolayer of cells. With time, plaque areas develop at the irregularities which alternate with less extensively colonised surrounding areas (Lie 1979; Nyvad & Fejerskov 1990). Thus initial adhesion, especially supragingivally, preferably starts at locations where bacteria are sheltered against shear forces, because the change from reversible to irreversible attachment can be established more easily and thus more frequently in these sites. Moreover, at surface irregularities and other stagnant sites, bacteria, once at-

tached, can survive longer because they are protected against naturally occurring removal forces (Newman 1974) or oral hygiene measures (Quiryne 1986). Finally, one should keep in mind that a roughening of the surface also increases the area available for adhesion by a factor $>3\times$.

Numerous *in vivo* studies examined the effect of surface roughness on plaque formation and the resulting periodontal inflammation. An overview of these studies (Quiryne & Bollen 1995; Quiryne et al. 1999b) produce the following general statements:

- Rough surfaces (crowns, implant abutments and denture bases) accumulate and retain more plaque (thickness, area and colony forming units). This is less obvious in patients with optimal oral hygiene or when plaque was scored with crude indices.
- After several days of undisturbed plaque formation, rough surfaces harbour a more mature plaque characterised by an increased proportion of motile organisms and spirochetes.
- As a consequence of the former, crowns with rough surfaces were more frequently surrounded by an inflamed periodontium, characterised by a higher bleeding index, an increased crevicular fluid production and/or an increased inflammatory infiltrate.

The same applies to plaque formation on implant abutment surfaces. A pilot study reported a faster supragingival plaque formation on titanium abutments ($R_a=0.3\ \mu\text{m}$), when compared to teeth (Quiryne 1986). In a second study, plaque formation on standard ($R_a=0.3\ \mu\text{m}$) and roughened abutments ($R_a=0.8\ \mu\text{m}$) was evaluated after 3 months of habitual oral hygiene (Quiryne et al. 1993). Supragingivally, rough abutments harboured significantly fewer cocci (64% vs. 81%), which is indicative of a more mature plaque. Subgingivally, rough surfaces harboured $25\times$ more bacteria, with a slightly lower density of coccoid organisms. Two more recent studies examined the effect of abutment smoothing. A smoothing below a $R_a=0.2\ \mu\text{m}$ showed no further significant changes, either in the total amount or in the peri-

odontal pathogenicity of adhering bacteria (Quirynen et al. 1996b; Bollen et al. 1996). The R_a value of $0.2 \mu\text{m}$ was therefore suggested as a threshold surface roughness, below which bacterial adhesion cannot be further reduced (Bollen & Quirynen 1997). These observations were confirmed by an *in vivo* study on the initial supragingival plaque formation (first 24 hours) on titanium specimens (with R_a values ranging from 0.1 to $2.4 \mu\text{m}$), intra-orally fixed in an acrylic stent (Rimondini et al. 1997). Whereas smooth surfaces hosted comparable amounts of bacteria, the rough surface harboured significantly higher numbers.

These data might be considered as contradictory to the observations of Gatewood and co-workers (1993). They glued small pieces (6.5 by 2 mm) of teeth (with a smooth enamel part and a fairly rough part of cementum) and of implants (with a smooth collar and a plasma-sprayed endosseous surface) in $\geq 6 \text{ mm}$ deep periodontal pockets (21 days post-scaling) in such a way that the smooth part remained supragingivally. The test pieces were removed surgically after several days and SEM pictures were made to analyse subgingival plaque maturation. No significant differences could be detected between the cementum and the rough implant surfaces. This could have been expected since the test pieces were inserted in pockets with an established microbiota and all 3 test surfaces were fairly rough, so that the impact of the surface smoothness disappeared.

The R_a values for the percutaneous part of most implant systems range from 0.1 to $0.3 \mu\text{m}$, which is within the range of a smooth enamel surface and/or polished restorative materials (Quirynen et al. 1994a). Scanning electron microscopy revealed that the Steri-Oss[®] abutment was highly polished with an equally smooth surface and minor irregularities. The IMZ[®], Brånemark[®], Astra Tech[®] and Core-Vent[®] abutments have clear milling marks, created during manufacturing. The Bonefit[®] has a large number of scratches. The hardness of the different implants showed some variation, the Brånemark[®] abutment having the softest surface (Vickers hardness 155 kg/mm^2) and the Steri-Oss[®]

implant the hardest (340 kg/mm^2). This limited hardness of commercially pure titanium abutments (enamel and porcelain have hardness values of more than 400 kg/mm^2 , Willems et al. 1991) explains the risk of surface roughening during habitual or professional cleaning. An *in vitro* study on IMZ[®] abutments reported a dramatic increase in surface roughness after a single episode of scaling with either titanium alloy or stainless-steel-tipped curescopes (Fox et al. 1990). The use of plastic scalers, in contrast, did not change the surface and should be advocated. An *in vitro* study on different abutments showed that a cleaning with plastic scalers, rubber cups and pumice, or with an air-powder abrasive system, resulted in a smoothening of the milling marks (McCullum et al. 1992; Mengel et al. 1998). In an animal study on 25 used Brånemark[®] abutments harbouring large amounts of calculus, ultrasonic scaling or scaling with metal instruments were found to significantly increase the surface roughness, whereas polishing with a lour of pumice, tooth brushing or scaling with plastic instruments had no effect on the surface profile (Speelman et al. 1992). A single application of a fluoride prophylactic agent can also result in a significant increase of the R_a through pitting corrosion by the hydrofluoric acid or the combination of fluoride and hydrogen ions from the acid (Pröbster et al. 1992). The use of an air-powder abrasive system cannot be advocated because it may even result in severe marginal bone loss around implants (Bergendal et al. 1990).

So far, all above-mentioned studies were dealing with the perimucosal part of the implants. It is evident that, due to marginal bone because of overload or peri-implantitis, the endosseous part of the implant will one day come into contact with the subgingival flora. From that moment on, the variety in surface roughness between implant systems becomes even more relevant (Wennerberg et al. 1993 for review, Buser 1999).

The implant surface roughness also has an impact on the quality of the soft tissue sealing. In 2 longitudinal studies in which highly polished abutments were followed over 3 months to 1 year, with regular pocket probing, it appeared that a certain surface roughness is

needed for an optimal soft tissue sealing. An intra-subject comparison showed that, while the commercially available abutments (R_a value $0.21 \mu\text{m}$) maintained a stable clinical attachment level, highly polished titanium or ceramic test abutments demonstrated a mean loss in attachment of $\geq 0.5 \text{ mm}$ in this short observation period (Quirynen et al. 1996b; Bollen et al. 1996). This difference can be explained by the interaction between surface texture and fibroblast and/or epithelial cell attachment and proliferation (Könönen et al. 1992; Chehroudi et al. 1992; Guy et al. 1993; Cochran et al. 1994; Hormia & Könönen 1994; Mustafa et al. 1998; Brunette & Chehroudi 1999). Thus, the original idea to highly polish the abutment surface to limit the bacterial adhesion could not be pursued, since this negatively affects the soft tissue attachment.

Intra-oral exposure time (Table 4)

The impact of the intra-oral exposure time on the composition of the subgingival flora around implants is different for partially and fully edentulous patients (Table 4).

Koka and co-workers (1993) followed the changes in composition of the marginal and subgingival plaque around osseointegrated implants during the first month after second-stage surgery. Already within 2 weeks, both the detection frequency and the number of different periodontopathogens in the marginal area around both implants and neighbouring teeth appeared comparable. The subgingival flora around the implants also showed a shift towards a composition similar to the one around the teeth. The latter shift only became obvious after 1 month, indicating a slower subgingival colonisation after supragingival plaque formation, as is also known for teeth.

Mombelli and co-workers (1988) followed the subgingival plaque maturation around ITI (one-part titanium plasma-coated hollow cylinder) implants supporting an overdenture in 5 fully edentulous patients (full denture wearers for many years) via subgingival samplings at weekly intervals during the first 8 weeks after implant installation, followed by monthly samplings for up to

Table 4. Longitudinal changes in subgingival flora around implants including: dark field microscopy data (proportions or frequency), and culture data (detection frequency for specific bacteria)

Authors	System	Number		Oral status	Time	Bacterial morphotypes: % (freq*)				Detection freq. specific bacteria				
		sub	imp			Cocci	Other	Motile	Spiro	Aa	Pg	Pi	Fn	
Mombelli et al. 1988	ITI hc	5	9	fully edent	1 w	88	11	1	0	0/9	0/9	0/9	0/9	0/9
			9		1 m	83	17	0	0	0/9	0/9	0/9	0/9	1/9
			9		3 m	81	19	0	0	0/9	0/9	0/9	1/9	3/9
Mombelli & Mericske-Stern 1990	ITI hc	4	8		6 m	94	6	0	0	0/9	0/9	1/8	2/8	
			36	fully edent	25-36 m	83	11	6	0	0/9 ^c	0/9	4/34	4/34	
Mombelli et al. 1995	ITIb/Brá	20	20	part edent	3 m			5/20*	3/20*	0/20 ^c	2/20	6/20	13/20	
			63	part edent	6 m			3/20*	5/20*	0/20	2/20	7/20	12/20	
Leonhardt et al. 1993	Brá	19	63		1 m					3/16 ^c	4/16	11/16		
					5 m					2/19	1/19	17/19		
					11 m					3/18	2/18	10/18		
					23 m					4/16	1/16	13/16		
Sbordone et al. 1999	Brá	25	42	part edent	12 m	81	16	2.7	0.1	1/25 ^c	6/25	3/25	4/25	
					24 m	81	14	5.0	0.5	3/25	10/25	4/25	4/25	
Mengel et al. 1996	Brá	5	36	part edent	1 m	70.1	12.3	16.6	0.8					
					4 m	76.9	9.6	12.9	0.7					
					7 m	77.6	6.4	16.0	0.1					
					10 m	85.3	5.9	6.1	2.6					
Koka et al. 1993	Brá	4	10	part edent	13 m	79.6	8.2	10.7	1.2	0/5 ^d	0/5	1/5		
					2 w						0/4 ⁱ	0/4	0/4	
					4 w						2/4	1/4		

System: ITI hc=Ti plasma-coated hollow cylinder, ITIb=Bonelit, Brá=Brånemark system;
sub=subjects (fully/part edent=fully/partially edentulous), imp=implants; Time=loading time for implants in weeks (w) or months (m);
Bacterial morphotypes: spiro=spirochetes;
Microbial analyses: ^c=culture, ^d=dna, ⁱ=immunoblot assay.

6 months. During the entire period, no significant changes were observed for successful implants (with >95% of the flora being cocci, 46% to 72% being Gram-positive facultative cocci, and a 1/1 ratio for anaerobic/aerobic species). Spirochetes and motile organisms were hardly detected. The detection frequency of *A. actinomycetemcomitans* (0), *P. gingivalis* (0) and *P. intermedia* (1/9) were also negligible. The same group published microbiological data on the same implant system and under comparable conditions, but now with follow-up data up to 5 years (Mombelli & Mericske-Stern 1990). After 2 years, still 83% of the flora consisted of cocci and still no spirochetes could be detected. At this time, motile organisms did appear (5.6%) but the ratio anaerobic/aerobic remained 1/1. Again, periodontopathogens were only infrequently detected. Nine patients (18 implants) were followed for another 3 years. The further changes over time were again insignificant. The total anaerobic and aerobic counts as well as the relative proportion of Gram-negative anaerobic rods were related to the local plaque index and the relative proportion of *Capnocytophaga* and *A. odontolyticus*, correlated with the probing depth. The same examiners also followed the early subgingival plaque formation around ITI Bonefit and Brånemark implants inserted in partially edentulous patients ($n=20$, aged 35–65 years) that previously had been successfully treated for moderate or advanced periodontitis (Mombelli et al. 1995). After 6 months exposure, a considerable number of peri-implant pockets became colonised by periodontopathogens (for *P. gingivalis* 2 out of 4, for *P. intermedia* 7 out of 13, and for spirochetes 5 out of 12 patients with these species around their teeth).

In another longitudinal study, a group of partially edentulous patients ($n=19$, aged 19–73 years), rehabilitated via the Brånemark system after relative suppression of the periodontal infection (still 25% bleeding upon probing teeth, high detection frequency of periodontopathogens), was followed (Leonhardt et al. 1993). In this group, periodontopathogens could already be detected around the implants 1 month after abutment connection. After 3 years

the implants frequently harboured periodontopathogens (4/17 *A. actinomycetemcomitans*, 4/17 *P. gingivalis* and 9/17 *P. intermedia*). The microbial load around these implants could, however, not be linked with marginal bone loss, except that 3 implant sites that lost >0.5 mm bone all harboured *P. intermedia*.

Sbordone and co-workers (1999) also examined the colonisation of Brånemark implants in partial edentulous patients with a history of periodontitis. The detection frequencies for periodontopathogens (including spirochetes) was already high after 1 year and further increased slightly during the second year. Krekeler et al. (1986) also reported an additional shift to a more anaerobic flora after the first year of loading.

From these studies one can conclude that in partially edentulous patients minor changes do occur with time, resulting in:

- an increase in the number of colony forming units,
- an increase in the proportion of motile organisms and especially of spirochetes,
- a slight additional increase in the detection frequency of other pathogenic species.

The impact of the intra-oral exposure time on the subgingival micro-flora around implants was also examined in a cross-sectional study where more than 500 implants were split into 5 categories according to different loading periods (Papaioannou et al. 1995). Changes in microbial composition over time were only observed around implants from partially edentulous patients. In the latter group, a significant shift towards a more pathogenic flora (with a higher proportion of spirochetes and motile organisms) was detected. Similar observations were made when the subgingival plaque maturation around implants was studied, in a cross-sectional design, via whole genomic DNA probes (Lee et al. 1999a).

The passive fit of implant components

The discrepancies between implant components, especially those located subgingivally, offer an ideal environ-

ment for *de novo* plaque formation and/or for plaque retention during cleaning. The size of the gap between implant and abutment of 9 different systems, including those with conical interfaces, was found to range between 1 and 10 µm (Jansen et al. 1997) and 49 µm (Binon et al. 1992) depending on whether or not the rounded edges of the abutment margin were included. Although the marginal discrepancies of these prefabricated parts are significantly smaller compared to those of other dental restorations (ranging from 50 to 150 µm), it still allows microbial leakage (Wahl et al. 1992; Quirynen & van Steenberghe 1993; Quirynen et al. 1994b; Jansen et al. 1997). This micro-leakage is comparable for different implant systems and decreases significantly when the closing torque is increased (Gross et al. 1999). As observed by Ericsson and co-workers (1995) in the Labrador dog model, such a bacterial leakage results in an inflammatory cell infiltrate (called abutment ICT) in the peri-implant mucosa at the borderline between abutment and implant, irrespective of the oral hygiene. The clinical relevance of this gap and/or leakage is very limited since many studies, both longitudinal and cross-sectional, concerning the Brånemark system prove that marginal bone loss is a rare complication (for review, see van Steenberghe et al. 1999b). The absence of a correlation between the degree of internal implant contamination and marginal bone loss (Persson et al. 1996) also refutes the concept that leakage can induce peri-implantitis. The gap between the abutment and the prosthetic supra-structure (sometimes located subgingivally in order to improve aesthetics), shows even larger discrepancies (Binon et al. 1992), especially for cemented restorations (Keith et al. 1999).

Foreign body reaction in peri-implant pocket

Peri-implantitis can be provoked by the subgingival impaction of a foreign body. Cement remnants can lead to an acute peri-implantitis process with local swelling, soreness, exudation on probing, and significant bone destruction (Pauletto et al. 1999). After the removal of the excess cement, the healing will

often be uneventful, although the bony defect might remain.

The material used as abutment portion of the implant is critical for both the location and quality of the soft tissue sealing and the underlying bone. In dogs, abutments from gold alloy or porcelain led to a significant marginal bone loss until the soft tissue barrier could be established on the titanium implant surface (Abrahamsson et al. 1998b).

Oral hygiene

The patient's oral hygiene has a significant impact on the stability of the marginal bone around osseointegrated implants. Even in fully edentulous patients, poor oral hygiene is related to increased peri-implant bone loss, especially in smokers (Lindquist et al. 1997).

Peri-implantitis versus mechanical overload

As of today, the relative importance of microbial factors and/or mechanical overload for the development and progression of bone loss around osseointegrated oral implants remains controversial. Stress concentrations in the marginal bone resulting from occlusal "overload" may cause marginal bone loss (van Steenberghe et al. 1999a). Overload is dependent on many factors, such as the load magnitude, direction, rate/frequency and the geometry of the prosthetic superstructure, the flexibility of the connecting devices and the quality of the surrounding bone. There are animal data (Hoshaw et al. 1994; Isidor 1996, 1997) and especially clinical investigations (Lindquist et al. 1988; Naert et al. 1992a,b; Quirynen et al. 1992; Esposito et al. 1997, 1998) which clearly demonstrate that marginal bone loss can become larger than the average 0.1 mm after the first year or bone remodelling when long cantilevers or para-functions (bruxing/clenching) are present.

Some authors tentatively attempted to distinguish between the morphology of bony defects resulting from unfavourable biomechanical factors and from peri-implantitis. This is not an easy task because the two-dimensional radio-

graphic picture is often a poor reflection of the real anatomy of the bony defect (Jacobs & van Steenberghe 1997). Others tried to make a distinction between both pathologies based on the subgingival flora. However, the marginal bone loss due to overload is often accompanied by attachment loss and deepening of the pockets. After some time, the newly created anaerobic environment will inevitably harbour a periopathogenic flora so that a distinction between both is no longer possible. Thus, the presence of a pathogenic subgingival flora after occlusal overload might simply reflect a surinfection of a favourable environment, which can contribute to further marginal bone loss, although the latter remains unproven.

Conclusion

The oral status, the implant configuration and surface in particular have an impact on the pathogenicity of the peri-implant flora. Whether osseointegration is at risk depends on the defence mechanism, the duration of the infection, the implant design and its surface characteristics. Indeed, some implants seem to be more at risk for occlusal overload, while other systems are more prone to plaque build-up. Basic research and long-term clinical trials are needed to obtain a better differential diagnosis of the cause of marginal bone loss. Implants in partially edentulous patients, in contrast to fully edentulous subjects, will easily be colonised by putative periodontal pathogens. It seems therefore reasonable that every partially edentulous patient receives appropriate periodontal screening and treatment prior to placement of dental implants and is maintained on an individualised recall schedule for supportive periodontal therapy afterwards. Conversely, it is still unknown whether a past history of periodontitis is a significant risk factor for implant survival in the same patient.

Résumé

L'utilisation d'implants dentaires dans la réhabilitation partielle et totale de patients édentés est bien acceptée malgré la présence d'échecs. La chance d'inté-

gration des implants peut par exemple être soumise à la présence de bactéries intra-buccales et de réactions inflammatoires concomitantes. La longévité des implants ostéointégrés peut être mise en danger par une surcharge occlusale, une paroiimplantite induite par la plaque dentaire ou les deux, dépendant de la géométrie de l'implant et des caractéristiques de sa surface. Des études chez l'animal, des observations croisées et longitudinales chez l'homme ainsi que des études d'association ont indiqué que la paroiimplantite était caractérisée par une flore comparable à celle de la parodontite (grande proportion de bâtonnets Gram négatif anaérobies, d'organismes mobiles et de spirochètes) mais ceci ne prouve pas nécessairement une relation de cause à effet. Cependant, afin de prévenir un tel changement bactérien, les mesures suivantes peuvent être prises en considération: santé parodontale dans le reste de la dentition (pour prévenir la translocation bactérienne), éviter les poches périimplantaires profondes et l'utilisation d'une surface assez lisse de l'implant et du pilier. Finalement, les facteurs augmentant le risque de la parodontite comme le tabagisme et la pauvre hygiène buccale peuvent aussi augmenter le risque de périimplantite. La susceptibilité à la parodontite pourrait être en relation avec celle de la périimplantite suivant le type d'implant et surtout suivant sa topographie de surface.

Zusammenfassung

Der Einsatz von Zahnimplantaten zur Rehabilitation von teilbezahnten oder zahnlosen Patienten ist eine weitherum anerkannte Methode, auch wenn ab und zu Misserfolge zu verzeichnen sind. Die Chance für eine Osseointegration der Implantate kann nicht zuletzt an Hand der intraoralen Bakterienflora und der begleitenden Entzündungsreaktionen abgeschätzt werden. Die Verweildauer eines osseointegrierten Implantates ist in starkem Masse von der okklusalen Überlastung und/oder der plaqueinduzierten Periimplantitis in Abhängigkeit zur Implantatgeometrie und den Oberflächencharakteristika beeinflusst. Tierstudien, Querschnitts- und Langzeitstudien am Menschen sowie Vergleichsstudien zeigen, dass die Periimplantitis eine Mikrobiota zeigt, die mit derjenigen der Parodontitis vergleichbar ist (hohe Anteile an anaeroben gramnegativen Stäbchen, beweglichen Organismen und Spirochäten). Dabei muss es aber nicht zwangenermassen einen kausalen Zusammenhang haben. Um aber eine solche bakterielle Übertragung zu verhindern, können die folgenden Massnahmen in Betracht gezogen werden: Parodontale Gesundheit in der Restdentition (um eine Verschleppung von Bakterien zu verhindern), Verhindern von tieferen periimplantären Taschen, und die Verwendung von relativ glatten Oberflächen beim Sekundärteil und dem Implantat. Schlussendlich können auch die parodontitisfördernden Faktoren wie z.B. Rauchen und schlechte Mundhygiene das Risiko für eine Periimplantitis steigern. Ob aber die Anfälligkeit für eine Parodontitis mit derjenigen für eine Periimplantitis korreliert ist, kann sich in Abhängigkeit zum Implantattyp und im Speziellen zur Oberflächentopographie verändern.

Resumen

El uso de implantes orales en la rehabilitación de pacientes parcial o totalmente edéntulos es ampliamente

te aceptado aunque existen fracasos. Las probabilidad de que los implantes se integren puede verse perjudicada por ejemplo por la presencia de bacterias intraorales y la reacción inflamatoria concomitante. La longevidad de los implantes osteointegrados se puede comprometer por la carga oclusal y/o la periimplantitis inducida por placa, dependiendo de la geometría del implante y las características de la superficie. Los estudios animales, las observaciones transverales y longitudinales en el hombre, al igual que estudios de asociación indican que la periimplantitis esta caracterizada por microbios comparables a los de la periodontitis (alta proporción de bacilos anaerobios Gram-negativos, organismos móviles y espiroquetas), pero esto no

prueba necesariamente una relación causal. De todos modos, en orden a prevenir dicho cambio bacteriano, se pueden considerar las siguientes medidas: salud periodontal en la dentición remanente (para prevenir traslocación bacteriana), evitar la profundización de bolsas periimplantarias, y el uso de un pilar y una superficie de implante relativamente suaves. Finalmente, los factores que estimulan la periodontitis tales como el tabaco y una pobre higiene oral aumentan el riesgo de periimplantitis. El que la susceptibilidad a la periodontitis esté relacionada con la de la periimplantitis puede variar de acuerdo con el tipo de implante y especialmente su topografía de superficie.

要旨

口腔インプラントは、失敗も起こるが、部分無歯顎及び完全無歯顎患者のリハビリテーション治療として広く受け入れられている。インプラントが骨性統合を達成する可能性は、例えば口内の細菌の存在やそれに伴う炎症反応によって損なわれる事がある。骨性統合したインプラントの寿命は、インプラントの形状及び表面特性によって、過剰な咬合力の荷重及び／あるいはブラークによるインプラント周囲炎によって悪影響を受けうる。動物実験、ヒトの横断的及び縦断的調査やその他の関連する研究は、インプラント周囲炎は歯周炎に相当する細菌（嫌気性グラム陰性桿状菌、運動性細菌及びスピロヘータの高い比率）によって特徴づけられていることを示唆しているが、このことは必ずしも因果関係を証明するものではない。しかし、このような細菌の推移を予防するために、残存歯列の歯周組織の健康を維持する（細菌の転位防止）、インプラント周囲に深いポケットができないようにする、比較的滑沢な表面のアパットメント及びインプラントを用いるなどの対策を考慮することができる。さらに、喫煙や不適切な口腔衛生の管理などの歯周炎を促進する要素はインプラント周囲炎のリスクを高めるものである。歯周炎に対する感受性が、インプラント周囲炎に対する感受性と関連しているかどうかは、インプラントのタイプや表面形状によって異なると思われる。

References

- Abrahamsson, I., Berglundh, T. & Lindhe, J. (1998a) Soft tissue response to plaque formation at different implant systems. A comparative study in the dog. *Clinical Oral Implants Research* **9**: 73–79.
- Abrahamsson, I., Berglundh, T., Glantz, P.-O. & Lindhe, J. (1998b) The mucosal attachment at different abutments. An experimental study in dogs. *Journal of Clinical Periodontology* **25**: 721–727.
- Adell, R., Lekholm, U., Rockler, B. & Brånemark, P.-I. (1981) A 15-year study of osseointegrated implants in the treatment of the edentulous jaw. *International Journal of Oral Surgery* **10**: 387–416.
- Adell, R., Lekholm, U., Rockler, B., Brånemark, P.-I., Lindhe, J., Eriksson, B. & Sbordone, L. (1986) Marginal tissue reactions at osseointegrated titanium fixtures. (II). A 3-year longitudinal prospective study. *International Journal of Oral and Maxillofacial Surgery* **15**: 39–52.
- Akagawa, Y., Toshikado, M., Kawamura, M. & Tsuru, H. (1993) Changes of subgingival microflora around single-crystal sapphire endosseous implants after experimental ligature-induced plaque accumulation in monkeys. *Journal of Prosthetic Dentistry* **69**: 594–598.
- Albrektsson, T. & Isidor, F. (1994) Consensus report of session IV. In: Lang N.P., Karring T., eds. *Proceedings of the First European Workshop on Periodontology*. London: Quintessence, 365–369.
- Albrektsson, T., Jansson, J. & Lekholm, U. (1986) Osseointegrated dental implants. *Dental Clinics of North America* **30**: 151–174.
- Alcoforado, G.A.P., Rams, T.E., Feik, D. & Slots, J. (1990) Microbial aspects of failing osseointegrated dental implants in humans. *Journal de Parodontologie* **10**: 11–18.
- Altonen, M., Saxén, L., Kosunen, T. & Ainamo, J. (1976) Effect of two antimicrobial rinses and oral prophylaxis on pre-operative degerming of saliva. *International Journal of Oral Surgery* **5**: 276–284.
- Apse, P., Ellen, R.P., Overall, C.M. & Zarb, G.A. (1989) Microbiota and crevicular fluid collagenase activity in the osseointegrated dental implant sulcus: a comparison of sites in edentulous and partially edentulous patients. *Journal of Periodontal Research* **24**: 96–105.
- Asmall, I.A. (1986) The mandibular staple bone plate: its use and advantage in reconstructive surgery. *Dental Clinics of North America* **30**: 175–187.
- Augthun, M. & Conrads, G. (1997) Microbial findings of peri-implant bone defects. *International Journal of Oral and Maxillofacial Implants* **12**: 106–112.
- Babbush, C.A. (1986) Titanium plasma spray screw implant system for reconstruction of the edentulous mandible. *Dental Clinics of North America* **30**: 117–131.
- Bain, C. & Moy, P. (1993) The association between the failure of dental implants and cigarette smoking. *International Journal of Oral and Maxillofacial Implants* **8**: 609–615.
- Becker, W., Becker, B.E., Newman, M.G. & Nyman, S. (1990) Clinical and microbiologic findings that may contribute to dental implant failure. *International Journal of Oral and Maxillofacial Implants* **5**: 31–38.
- Bender, I.B. & Seltzer, S. (1961) Roentgenographic and direct observation of experimental lesions in bone: II. *Journal of the American Dental Association* **62**: 708–716.
- Bergendal, T., Forsgren, L., Kvint, S. & Lowstedt, E. (1990) The effect of an airbrasive instrument on soft and hard tissues around osseointegrated implants. A case report. *Swedish Dental Journal* **14**: 219–223.
- Berglundh, T. (1999) Soft tissue interface and response to microbial challenge. In: Lang, N.P., Karring, T., Lindhe, J., eds. *Proceedings of the 3rd European Workshop on Periodontology*. Berlin: Quintessence, 153–174.
- Berglundh, T. & Lindhe, J. (1996) Dimension of the peri-implant mucosa. Biological width revisited. *Journal of Clinical Periodontology* **23**: 971–973.
- Berglundh, T., Lindhe, J., Marinello, C., Ericsson, I. & Liljenberg, B. (1992) Soft tissue reaction to *de novo* plaque formation on implants and teeth. An experimental study in the dog. *Clinical Oral Implants Research* **3**: 1–8.
- Binon, P.P., Weir, D.J. & Marshall, S.J. (1992) Surface analysis of an original Brånemark implant and three related clones. *International Journal of Oral & Maxillofacial Implants* **7**: 168–175.
- Bollen, C.M.L. & Quiryne, M. (1997) The evolution of the surface roughness of different oral hard materials in comparison to the “threshold surface roughness”. A review of the literature. *Dental Materials* **13**: 258–269.
- Bollen, C.M.L., Papaioannou, W., Van Eldere, J., Schepers, E., Quiryne, M. & van Steenberghe, D. (1996) The influence of abutment surface roughness on plaque accumulation and peri-implant mucositis. *Clinical Oral Implants Research* **7**: 201–211.
- Bower, R.C., Radny, N.R., Wall, C.D. & Henry, P.J. (1989) Clinical and microscopic findings in edentulous patients 3 years after incorporation of osseointegrated implant-supported bridgework. *Journal of Clinical Periodontology* **16**: 580–587.
- Brånemark, P.-I. (1985) Introduction to osseointegration. In: Brånemark P.-I., Zarb G.A., Albrektsson T., eds. *Tissue-Integrated Prosthesis: Osseointegration in Clinical Dentistry*. Chicago: Quintessence Publ. Co., 11–76.
- Brånemark, P.-I., Zarb, G.A. & Albrektsson, T. eds. (1985) *Tissue-Integrated Prosthesis: Osseointegration in Clinical Dentistry*. Chicago: Quintessence Publ. Co., 211–232.
- Brocard, D., Barthet, P., Baysse, E., Duffort, J.F., Eller, P., Justumus, P., Marin, P., Oscaby, F., Simonet, T., Benqué, E. & Brunel, G. (2000) A multicenter report on 1,022 consecutively placed ITI implants: a 7-year

- longitudinal study. *International Journal of Oral and Maxillofacial Implants* 15: 691–700.
- Brook, I., Foote, P.A. & Slots, J. (1997) Immune response to *Fusobacterium nucleatum*, *Prevotella intermedia* and other anaerobes in children with acute tonsillitis. *Journal of Antimicrobial Chemotherapy* 39: 763–769.
- Brown, L.J. & Löe, H. (1993) Prevalence, extent, severity and progression of periodontal disease. *Periodontology 2000* 2: 57–71.
- Brunette, D.M. & Chehroudi, B. (1999) The effects of the surface topography of micromachined titanium substrata on cell behavior *in vitro* and *in vivo*. *Journal of Biomechanical Engineering* 121: 49–57.
- Bryndolf, I. (1971) Improved viewing conditions for better roentgenodiagnosis. *Oral Surgery, Oral Medicine and Oral Pathology* 32: 808–811.
- Buser, D. (1999) Effects of various titanium surface configurations on osseointegration and clinical implant stability. In: Lang N.P., Karring T., Lindhe J., eds. *Proceedings of the 3rd European Workshop on Periodontology* pp. 88–101. Quintessence Books: Berlin.
- Buser, D., Mericske-Stern, R., Bernard, J.P., Behneke, A., Behneke, N., Hirt, H.P., Belsler, U.C. & Lang, N.P. (1997) Long-term evaluation of non-submerged ITI implants. Part I: 8-year life table analysis of a prospective multi-center study with 2359 implants. *Clinical Oral Implants Research* 8: 161–172.
- Chehroudi, B., Gould, T.R. & Brunette, D.M. (1992) The role of connective tissue in inhibiting epithelial downgrowth on titanium-coated percutaneous implants. *Journal of Biomedical Materials Research* 26: 493–515.
- Cochran, D.L., Simpson, J., Weber, H.P. & Buser, D. (1994) Attachment and growth of periodontal cells on smooth and rough titanium. *International Journal of Oral and Maxillofacial Implants* 9: 289–297.
- Danser, M.M. (1996) *The prevalence of periodontal bacteria colonizing the oral mucous membranes*. ScD Thesis, Universiteit van Amsterdam, The Netherlands.
- Danser, M.M., Van Winkelhoff, A.J., de Graaf, J., Loos, B.G. & Van der Velden, U. (1994) Short-term effect of full-mouth extraction on periodontal pathogens colonizing the oral mucous membranes. *Journal of Clinical Periodontology* 21: 484–489.
- Danser, M.M., Timmerman, M.F., van Winkelhoff, A.J. & van der Velden, U. (1996) The effect of periodontal treatment on periodontal bacteria on the oral mucous membranes. *Journal of Periodontology* 67: 478–485.
- Danser, M.M., van Winkelhoff, A.J. & van der Velden, U. (1997) Periodontal bacteria colonizing oral mucous membranes in edentulous patients wearing dental implants. *Journal of Periodontology* 68: 209–216.
- Dent, C.D., Olson, J.W., Farish, S.E., Bellome, J., Casino, A.J., Morris, H.F. & Ochi, S. (1997) The influence of preoperative antibiotics on success of endosseous implants up to and including stage II surgery: a study of 2,641 implants. *Journal of Oral and Maxillofacial Surgery* 55: 19–24.
- Eke, P.I., Braswell, L.D. & Fritz, M.E. (1998) Microbiota associated with experimental peri-implantitis and periodontitis in adult *Macaca mulatta* monkeys. *Journal of Periodontology* 69: 190–194.
- Ellegaard, B., Baelum, V. & Karring, T. (1997) Implant therapy in periodontally compromised patients. *Clinical Oral Implants Research* 8: 180–188.
- Ericsson, I., Berglundh, T., Marinello, C., Liljenberg, B. & Lindhe, J. (1992) Long-standing plaque and gingivitis at implants and teeth in the dog. *Clinical Oral Implants Research* 3: 99–103.
- Ericsson, I., Persson, L.G., Berglundh, T., Marinello, C.P., Lindhe, J. & Klinge, B. (1995) Different types of inflammatory reactions in peri-implant soft tissues. *Journal of Clinical Periodontology* 22: 255–261.
- Ericsson, I., Persson, L.G., Glantz, P.-O., Berglundh, T. & Lindhe, J. (1996) The effect of antimicrobial therapy on peri-implantitis lesions. An experimental study in the dog. *Clinical Oral Implants Research* 7: 320–328.
- Esposito, M., Thomsen, P., Mölne, J., Gretzer, C., Ericsson, L.E. & Lekholm, U. (1997) Immunohistochemistry of soft tissues surrounding late failures of Brånemark implants. *Clinical Oral Implants Research* 8: 352–366.
- Esposito, M., Hirsch, J.-M., Lekholm, U. & Thomsen, P. (1998) Biological factors contributing to failures of osseointegrated oral implants (II). Etiopathogenesis. *European Journal of Oral Sciences* 106: 721–764.
- Esposito, M., Hirsch, J., Lekholm, U. & Thomsen, P. (1999) Differential diagnosis and treatment strategies for biologic complications and failing oral implants: a review of the literature. *International Journal of Oral and Maxillofacial Implants* 14: 473–490.
- Fardal, O., Johannessen, A.C. & Olsen, I. (1999) Severe, rapidly progressing peri-implantitis. *Journal of Clinical Periodontology* 26: 313–317.
- Farman, A.G., Avant, S.L., Scafere, W.C., Farman, T.T. & Green, D.B. (1998) *In vivo* comparison of Visualix-2 and Ektasped Plus in the assessment of periradicular lesion dimensions. *Oral Surgery, Oral Medicine, Oral Pathology* 85: 203–209.
- Flemmig, T.F. (1994) Infektionen bei osseointegrierten Implantaten – Hintergründe und klinische Implikationen. *Implantologie* 1: 9–21.
- Fox, S.C., Moriarty, J.D. & Kusy, R.P. (1990) The effects of scaling a titanium implant surface with metal and plastic instruments: an *in vitro* study. *Journal of Periodontology* 61: 485–490.
- Gatewood, R.R., Cobb, C.M. & Killoy, W.J. (1993) Microbial colonization on natural tooth structure compared with smooth and plasma-sprayed dental implant surfaces. *Clinical Oral Implants Research* 4: 53–64.
- George, K., Zafropoulos, G.G., Murat, Y., Spiekermann, H. & Nisengard, R.J. (1994) Clinical and microbiological status of osseointegrated implants. *Journal of Periodontology* 65: 766–770.
- Goldman, M., Pearson, A.H. & Darzenta, N. (1974) Reliability of radiographic interpretations. *Oral Surgery, Oral Medicine, Oral Pathology* 38: 287–293.
- Gross, M., Abramovich, I. & Weiss, E.I. (1999) Microleakage at the abutment-implant interface of osseointegrated implants: a comparative study. *International Journal of Oral and Maxillofacial Implants* 14: 94–100.
- Guy, S.C., McQuade, M.J., Scheidt, M.J., McPherson, J.C., Rossmann, J.A. & Van Dyke, T.E. (1993) *In vitro* attachment of human gingival fibroblasts to endosseous implant materials. *Journal of Periodontology* 64: 542–546.
- Haanaes, H.R. (1990) Implants and infections with special reference to oral bacteria. *Journal of Clinical Periodontology* 17: 516–524.
- Hämmerle, C.H.F., Fourmousis, I., Winkler, J.R., Weigel, C., Brägger, U. & Lang, N.P. (1995) Successful bone fill in late peri-implant defects using guided tissue regeneration. A short communication. *Journal of Periodontology* 66: 303–308.
- Hanisich, O., Cortella, C.A., Boskovic, M.M., Robert, A.J., Slots, J., Wikesjö, U.M.E. (1997) Experimental peri-implant tissue breakdown around hydroxyapatite-coated implants. *Journal of Periodontology* 68: 59–66.
- Haring, J.I. & Lind, L.J. (1996) *Dental radiography: principles and techniques*. Philadelphia: WB Saunders Company.
- Hormia, M. & Könönen, M. (1994) Immunolocalization of fibronectin and vitronectin receptors in human gingival fibroblasts spreading on titanium surfaces. *Journal of Periodontal Research* 29: 146–152.
- Hoshaw, S., Brunski, J. & Cochran, G. (1994) Mechanical loading of Brånemark implants affects interfacial bone modeling and remodeling. *International Journal of Oral and Maxillofacial Implants* 9: 345–360.
- Hickey, J.S., O’Neal, R.B., Scheidt, M.J., Strong, S.L., Turgeon, D. & Van Dyke, T.E. (1991) Microbiologic characterization of ligature-induced peri-implantitis in the microswine model. *Journal of Periodontology* 62: 548–553.
- Hugoson, A. & Jordan, T. (1982) Frequency distribution of individuals aged 20–70 years according to severity of periodontal disease. *Community Dentistry and Oral Epidemiology* 10: 187–192.
- Hultin, M., Gustafsson, A. & Klinge, B. (2000) Long-term evaluation of osseointegrated dental implants in the treatment of partly edentulous patients. *Journal of Clinical Periodontology* 27: 128–133.
- Hutton, J., Heath, M., Chai, J., Harnett, J., Jemt, T., Johns, R., McKenna, S., McNamara, D. & van Steenberghe, D. (1995) Factors related to the success and failure rates at 3-year follow-up in a multicenter study of overdentures supported by Brånemark implants. *International Journal of Oral and Maxillofacial Implants* 10: 33–42.
- Isidor, F. (1996) Loss of osseointegration caused by occlusal load of oral implants. A clinical and radiographic study in monkeys. *Clinical Oral Implants Research* 7: 143–152.
- Isidor, F. (1997) Histological evaluation of peri-implant bone at implants subjected to occlusal overload or plaque accumulation. *Clinical Oral Implants Research* 8: 1–9.
- Jacobs, R. & van Steenberghe, D. (1997) *Radiographic planning and assessment of endosseous oral implants*. Berlin: Springer Verlag, 128 pp.
- Jaffin, R. & Berman, C. (1991) The excessive loss of Brånemark implants in type IV bone. A five-year analysis. *Journal of Periodontology* 62: 2–4.
- Jansen, V.K., Conrads, G. & Richter, E.-J. (1997) Microbial leakage and marginal fit of the implant-abutment interface. *International Journal of Oral and Maxillofacial Implants* 12: 527–540.
- Jovanovic, S.A. (1993) The management of peri-implant breakdown around functioning osseointegrated dental implants. *Journal of Periodontology* 64: 1176–1183.
- Jovanovic, S.A., Kenney, E.B., Carranza, F.A. & Donath, K. (1993) The regenerative potential of plaque-induced peri-implant bone defects treated by a submerged membrane technique: an experimental study. *International Journal of Oral and Maxillofacial Implants* 8: 13–18.
- Keith, S.E., Miller, B.H., Woody, R.D. & Higginbot-

- tom, F.L. (1999) Marginal discrepancy of screw-retained and cemented metal-ceramic crowns on implant abutments. *International Journal of Oral and Maxillofacial Implants* **14**: 369–378.
- Keller, W., Brägger, U. & Mombelli, A. (1998) Peri-implant microflora of implants with cemented and screw retained suprastructures. *Clinical Oral Implants Research* **9**: 209–217.
- Keyes, P. & Rams, T. (1983) A rationale for management of periodontal diseases: rapid identification of microbial therapeutic targets with phase-contrast microscopy. *Journal of the American Dental Association* **106**: 803–812.
- Klinge, B. (1991) Implants in relation to natural teeth. *Journal of Clinical Periodontology* **18**: 482–487.
- Kohavi, D., Greenberg, R., Raviv, E. & Sela, M.N. (1994) Subgingival and supragingival microbial flora around healthy osseointegrated implants in partially edentulous patients. *International Journal of Oral and Maxillofacial Implants* **9**: 673–678.
- Koka, S., Razzoog, M.E., Bloem, T.J. & Syed, S. (1993) Microbial colonization of dental implants in partially edentulous subjects. *Journal of Prosthetic Dentistry* **70**: 141–144.
- Könönen, M., Hormia, M., Kivilahti, J., Hautaniemi, J. & Thesleff, I. (1992) Effect of surface processing on the attachment, orientation, and proliferation of human gingival fibroblasts on titanium. *Journal of Biomedical Materials Research* **26**: 1325–1341.
- Könönen, E., Jousimies-Somer, H. & Asikainen, S. (1992) Relationship between oral Gram-negative anaerobic bacteria in saliva of the mother and the colonization of her edentulous infant. *Oral Microbiology and Immunology* **7**: 273–276.
- Krekeler, G., Pelz, K. & Nelissen, R. (1986) Mikrobielle Besiedlung der Zahnfleischtaschen am künstlichen Titanpfeiler. *Deutsche Zahnärztliche Zeitschrift* **41**: 569–572.
- Lang, N.P., Brägger, U., Walther, D., Beamer, B. & Kornman, K.S. (1993) Ligature-induced peri-implant infection in cynomolgus monkeys. I. Clinical and radiographic findings. *Clinical Oral Implants Research* **4**: 2–11.
- Lee, K.H., Maiden, M.F.J., Tanner, A.C.R. & Weber, H.P. (1999a) Microbiota of successful osseointegrated dental implants. *Journal of Periodontology* **70**: 1311–1318.
- Lee, K.H., Tanner, A.C.R., Maiden, M.F.J. & Weber, H.P. (1999b) Pre- and post-implantation microbiota of the tongue, teeth, and newly-placed implants. *Journal of Clinical Periodontology* **26**: 822–832.
- Lehmann, B., Brägger, U., Hämmerle, C.H.F., Fourmousis, I. & Lang, N.P. (1992) Treatment of an early implant failure according to the principles of guided tissue regeneration (GTR). *Clinical Oral Implants Research* **3**: 42–48.
- Lekholm, U., Adell, R. & Brånemark, P.-I. (1985) Complications. In: Brånemark, P.-I., Zarb, G.A., Albrektsson, T., eds. *Tissue-integrated prostheses*. Chicago: Quintessence, 233–240.
- Lekholm, U., Adell, R., Lindhe, J., Brånemark, P.-I., Eriksson, B., Rockler, B., Lindvall, A.-M. & Yoneyama, T. (1986a) Marginal tissue reactions at osseointegrated titanium fixtures. (II). A cross-sectional retrospective study. *International Journal of Oral and Maxillofacial Surgery* **15**: 53–61.
- Lekholm, U., Ericsson, I., Adell, R. & Slots, J. (1986b) The condition of the soft tissues at tooth and fixture abutments supporting fixed bridges. *Journal of Clinical Periodontology* **13**: 558–562.
- Leonhardt, A., Renvert, S., Ericsson, I., Dahlén, G. (1992) Putative periodontal pathogens on titanium implants and teeth in experimental gingivitis and periodontitis in beagle dogs. *Clinical Oral Implants Research* **3**: 112–119.
- Leonhardt, A., Adolfsen, B., Lekholm, U., Wikström, M. & Dahlén, G. (1993) A longitudinal microbiological study on osseointegrated titanium implants in partially edentulous patients. *Clinical Oral Implants Research* **4**: 113–120.
- Leonhardt, A., Renvert, S. & Dahlén, G. (1999) Microbial findings at failing implants. *Clinical Oral Implants Research* **10**: 339–345.
- Lie, T. (1979) Morphologic studies on dental plaque formation. *Acta Odontologica Scandinavica* **37**: 73–85.
- Lindhe, J., Berglundh, T., Ericsson, I., Liljeborg, B., Marinello, C. (1992) Experimental breakdown of peri-implant and periodontal tissues. A study in the beagle dog. *Clinical Oral Implants Research* **3**: 9–16.
- Lindquist, L.W., Rockler, B. & Carlsson, G.E. (1988) Bone resorption around fixtures in edentulous patients treated with mandibular fixed tissue-integrated prostheses. *Journal of Prosthetic Dentistry* **59**: 59–63.
- Lindquist, L.W., Carlsson, G.E. & Jemt, T. (1997) Association between marginal bone loss around osseointegrated mandibular implants and smoking habits: a 10-year follow-up study. *Journal of Dental Research* **76**: 1667–1674.
- Listgarten, M.A. & Hellén, L. (1978) Relative distribution of bacteria at clinically healthy and periodontally diseased sites in humans. *Journal of Clinical Periodontology* **5**: 115–132.
- Listgarten, M.A. & Lai, C.-H. (1999) Comparative microbiological characteristics of failing implants and periodontally diseased teeth. *Journal of Periodontology* **70**: 431–437.
- Listgarten, M.A., Levin, S., Schifter, C.C., Sullivan, P., Evian, C.L., Rosenberg, E.S. & Laster, L. (1986) Comparative longitudinal study of 2 methods of scheduling maintenance visits, 2-year data. *Journal of Clinical Periodontology* **13**: 692–700.
- Löe, H., Theilade, E. & Jensen, S.B. (1965) Experimental gingivitis in man. *Journal of Periodontology* **36**: 177–187.
- Loesche, W.J. & Syed, S.A. (1978) Bacteriology of human experimental gingivitis: effect of plaque and gingivitis score. *Infection and Immunity* **21**: 830–839.
- Malmstrom, H.S., Fritz, M.E., Timmis, D.P. & Van Dyke, T.E. (1990) Osseo-integrated implant treatment of a patient with rapidly progressive periodontitis. A case report. *Journal of Periodontology* **61**: 300–304.
- Marinello, C.P., Berglundh, T., Ericsson, I., Klinge, B., Glantz, P.O. & Lindhe, J. (1995) Resolution of ligature-induced peri-implantitis lesions in the dog. *Journal of Clinical Periodontology* **22**: 475–479.
- Mattout, P., Nowzari, H. & Mattout, C. (1995) Clinical evaluation of guided bone regeneration at exposed parts of Brånemark dental implants with and without bone allograft. *Clinical Oral Implants Research* **6**: 189–195.
- McCollum, J., O'Neal, R.B., Brennan, W.A., Van Dyke, T.E. & Horner, J.A. (1992) The effect of titanium implant abutment surface irregularities on plaque accumulation *in vivo*. *Journal of Periodontology* **63**: 802–805.
- Mengel, R., Stelzel, M., Hasse, C. & Flores-de-Jacoby, L. (1996) Osseointegrated implants in patients treated for generalized severe adult periodontitis. An interim report. *Journal of Periodontology* **67**: 782–787.
- Mengel, R., Buns, C.E., Mengel, C. & Flores-de-Jacoby, L. (1998) An *in vitro* study of the treatment of implant surfaces with different instruments. *International Journal of Oral and Maxillofacial Implants* **13**: 91–96.
- Merritt, G., Farman, A., George, D., Chu, A. & Blair, R. (1984) Computed tomography, panoramic dental radiography, and lateral oblique projections for mandibular cortical and medullary defects: a comparative study. *Dentomaxillofacial Radiology* **13**: 21–26.
- Mombelli, A. (1999) Prevention and therapy of peri-implant infections In: Lang, N.P., Karring, T., Lindhe, J., eds. *Proceedings of the 3rd European Workshop on Periodontology*. Berlin: Quintessence Books, 281–303.
- Mombelli, A. & Lang, N.P. (1992) Antimicrobial treatment of peri-implant infections. *Clinical Oral Implants Research* **3**: 162–168.
- Mombelli, A. & Lang, N.P. (1998) The diagnosis and treatment of peri-implantitis. *Periodontology 2000* **17**: 63–76.
- Mombelli, A. & Mericske-Stern, R. (1990) Microbiological features of stable osseointegrated implants used as abutments for overdentures. *Clinical Oral Implants Research* **1**: 1–7.
- Mombelli, A., Van Oosten, M.A.C., Schürch, E. & Lang, N.P. (1987) The microbiota associated with successful or failing osseointegrated titanium implants. *Oral Microbiology and Immunology* **2**: 145–151.
- Mombelli, A., Buser, D. & Lang, N.P. (1988) Colonization of osseointegrated titanium implants in edentulous patients. Early results. *Oral Microbiology and Immunology* **3**: 113–120.
- Mombelli, A., Marxer, M., Gaberthüel, T., Grunder, U. & Lang, N.P. (1995) The microbiota of osseointegrated implants in patients with a history of periodontal disease. *Journal of Clinical Periodontology* **22**: 124–130.
- Mombelli, A., Lehmann, B., Tonetti, M. & Lang, N.P. (1997) Clinical response to local delivery of tetracycline in relation to overall and local periodontal conditions. *Journal of Clinical Periodontology* **24**: 470–477.
- Mongardini, C., van Steenberghe, D., Dekeyser, C. & Quirynen, M. (1999) One stage full- vs. partial-mouth disinfection in treatment of chronic adult or early onset periodontitis. I: Long-term clinical observations. *Journal of Periodontology* **70**: 632–645.
- Mustafa, K., Silva Lopez, B., Hultén, K., Wennerberg, A. & Arvidson, K. (1998) Attachment and proliferation of human oral fibroblasts to titanium surfaces blasted with TiO₂ particles. A scanning electron microscopic and histomorphometric analysis. *Clinical Oral Implants Research* **9**: 195–207.
- Naert, I., Quirynen, M., van Steenberghe, D. & Darius, P. (1992a) A six-year prosthodontic study on 509 consecutively inserted implants for the treatment of partial edentulism. *Journal of Prosthetic Dentistry* **67**: 236–245.
- Naert, I., Quirynen, M., van Steenberghe, D. & Darius, P. (1992b) A study of 589 consecutive implants supporting complete fixed prostheses. Part II: Prosthetic aspects. *Journal of Prosthetic Dentistry* **68**: 949–956.

- Nevins, M. & Langer, B. (1995) The successful use of osseointegrated implants for the treatment of the recalcitrant periodontal patient. *Journal of Periodontology* **66**: 150–157.
- Newman, H.N. (1974) Microbial films in nature. *Microbios* **9**: 247–257.
- Nowzari, H., MacDonald, E.S., Flynn, J., London, R.M., Morison, J.L. & Slots, J. (1996) The dynamics of microbial colonization of barrier membranes for guided tissue regeneration. *Journal of Periodontology* **67**: 694–702.
- Nyvad, B. & Fejerskov, O. (1990) An ultrastructural study of bacterial invasion and tissue breakdown in human experimental root-surface caries. *Journal of Dental Research* **69**: 1118–1125.
- Ong, E.S.-M., Newman, H.N., Wilson, M. & Bulman, J.S. (1992) The occurrence of periodontitis-related microorganisms in relation to titanium implants. *Journal of Periodontology* **63**: 200–205.
- Palmisano, D.A., Mayo, J.A., Block, M.S. & Lancaster, D.M. (1991) Subgingival bacteria associated with hydroxylapatite-coated dental implants: morphotypes and trypsin-like enzyme activity. *International Journal of Oral & Maxillofacial Implants* **6**: 313–318.
- Papaoiannou, W., Quirynen, M., Nys, M. & van Steenberghe, D. (1995) The effect of periodontal parameters on the subgingival microbiota around implants. *Clinical Oral Implants Research* **6**: 197–204.
- Papaoiannou, W., Quirynen, M. & van Steenberghe, D. (1996) The influence of periodontitis on the subgingival flora around implants in partially edentulous patients. *Clinical Oral Implants Research* **7**: 405–409.
- Pauletto, N., Lahiffe, B.J. & Walton, J.N. (1999) Complications associated with excess cement around crowns on osseointegrated implants: a clinical report. *International Journal of Oral and Maxillofacial Implants* **14**: 865–868.
- Persson, L.G., Lekholm, U., Leonhardt, A., Dahlén, G. & Lindhe, J. (1996) Bacterial colonization on internal surfaces of Brånemark® system implant components. *Clinical Oral Implants Research* **7**: 90–95.
- Persson, L.G., Araújo, M.G., Berglundh, T., Gröndahl, K. & Lindhe, J. (1999) Resolution of peri-implantitis following treatment. An experimental study in the dog. *Clinical Oral Implants Research* **10**: 195–203.
- Petit, M.D.A., Van Steenberghe, T.J.M., Timmerman, M.F., De Graaff, J. & Van der Velden, U. (1994) Prevalence of periodontitis and suspected periodontal pathogens in families of adult periodontitis patients. *Journal of Clinical Periodontology* **21**: 76–85.
- Piattelli, A., Scarano, A. & Piattelli, M. (1995) Abscess formation around the apex of a maxillary root form implant: clinical and microscopical aspects. A case report. *Journal of Periodontology* **66**: 899–903.
- Piattelli, A., Scarano, A., Piattelli, M. & Podda, G. (1998) Implant peri-apical lesions: clinical, histologic, and histochemical aspects. A case report. *International Journal of Periodontics and Restorative Dentistry* **18**: 181–187.
- Pontoriero, R., Tonelli, M.P., Carnavale, G., Mombelli, A., Nyman, S.R. & Lang, N.P. (1994) Experimentally induced peri-implant mucositis. A clinical study in humans. *Clinical Oral Implants Research* **5**: 254–259.
- Pröbster, L., Lin, W. & Hütteman, H. (1992) Effect of fluoride prophylactic agents on titanium surfaces. *International Journal of Oral and Maxillofacial Implants* **7**: 390–394.
- Quirynen, M. (1986) *Anatomical and inflammatory factors influence bacterial plaque growth and retention in man*. Thesis, Leuven, Belgium.
- Quirynen, M. & Bollen, C.M.L. (1995) The influence of surface roughness and surface free energy on supra- and subgingival plaque formation in man. A review of the literature. *Journal of Clinical Periodontology* **22**: 1–14.
- Quirynen, M. & Listgarten, M.A. (1990) The distribution of bacterial morphotypes around natural teeth and titanium implants *ad modum* Brånemark. *Clinical Oral Implants Research* **4**: 8–12.
- Quirynen, M. & van Steenberghe, D. (1993) Bacterial colonisation of the internal part of two-stage implants. An *in vivo* study. *Clinical Oral Implants Research* **4**: 158–161.
- Quirynen, M., Naert, I. & van Steenberghe, D. (1992) Fixture design and overload influence marginal bone- and fixture loss in the Brånemark® system. *Clinical Oral Implants Research* **3**: 104–111.
- Quirynen, M., Van der Mei, H.C., Bollen, C.M.L., Schotte, A., Marechal, M., Doornbusch, G.I., Naert, I., Busscher, H.J. & van Steenberghe, D. (1993) An *in vivo* study of the influence of surface roughness of implants on the microbiology of supra- and subgingival plaque. *Journal of Dental Research* **72**: 1304–1309.
- Quirynen, M., Bollen, C.M.L., Willems, G. & van Steenberghe, D. (1994a) Comparison of surface characteristics of six commercially pure titanium abutments. *International Journal of Oral and Maxillofacial Implants* **9**: 71–76.
- Quirynen, M., Bollen, C.M.L., Eysen, H. & van Steenberghe, D. (1994b) Microbial penetration along the implant components of the Brånemark system®. *Clinical Oral Implants Research* **5**: 239–244.
- Quirynen, M., Papaoiannou, W. & van Steenberghe, D. (1996a) Intraoral transmission and the colonization of oral hard surfaces. *Journal of Periodontology* **67**: 986–993.
- Quirynen, M., Bollen, C.M.L., Papaoiannou, W., Van Eldere, J. & van Steenberghe, D. (1996b) The influence of titanium abutments surface roughness on plaque accumulation and gingivitis. Short term observations. *International Journal of Oral and Maxillofacial Implants* **11**: 169–178.
- Quirynen, M., Mongardini, C., Pauwels, M., Bollen, C. M. L., Van Eldere, J. & van Steenberghe, D. (1999a) One stage full- vs. partial mouth disinfection in the treatment of patients with chronic adult or early onset periodontitis. Part II: Long-term impact on microbial load. *Journal of Periodontology* **70**: 646–656.
- Quirynen, M., De Soete, M. & van Steenberghe, D. (1999b) Intra-oral plaque formation on artificial surfaces. In: Lang, N.P., Karring, T., Lindhe, J., eds. *Proceedings of the 3rd European Workshop on Periodontology*. Berlin: Quintessence Books, 102–129.
- Quirynen, M., Mongardini, C., De Soete, M., Pauwels, M., Coucke, W., Van Eldere, J. & van Steenberghe, D. (2000) The role of chlorhexidine in the one stage full-mouth disinfection treatment of patients with adult periodontitis. Long-term clinical & microbiological observations. *Journal of Clinical Periodontology* **27**: 578–589.
- Quirynen, M., Peeters, W., Naert, I., Coucke, W. & van Steenberghe, D. (2001) Peri-implant health around screw-shaped c.p. titanium machined implants in partially edentulous patients with or without ongoing periodontitis. *Clinical Oral Implants Research* **12**: 589–594.
- Rams, T.E., Feik, D. & Slots, J. (1990) Staphylococci in human periodontal diseases. *Oral Microbiology and Immunology* **5**: 29–32.
- Regan, J.E. & Mitchell, D.F. (1962) Evaluation of periapical radiolucencies found in cadavers. *Journal of the American Dental Association* **66**: 529–533.
- Rimondini, L., Fare, S., Brambilla, E., Felloni, A., Consonni, C., Brossa, F. & Carrassi, A. (1997) The effect of surface roughness on early *in vivo* plaque colonization on titanium. *Journal of Periodontology* **68**: 556–562.
- Rosenberg, E.S., Torosian, J.P. & Slots, J. (1991) Microbial differences in two clinically distinct types of failures of osseointegrated implants. *Clinical Oral Implants Research* **2**: 135–144.
- Rovin, S., Costich, E.R. & Gordon, H.A. (1966) The influence of bacteria and irritation in the initiation of periodontal disease in germfree and conventional rats. *Journal of Periodontal Research* **1**: 193–203.
- Salcetti, J.M., Moriarty, J.D., Cooper, L.F., Smith, F.W., Collins, J.G., Socransky, S.S. & Offenbacher, S. (1997) The clinical, microbial, and host response characteristics of the failing implant. *International Journal of Oral and Maxillofacial Implants* **12**: 33–42.
- Sanz, M., Newman, M.G., Nachnani, S., Holt, R., Stewart, R. & Flemmig, T. (1990) Characterization of the subgingival microbial flora around endosteal sapphire dental implants in partially edentulous patients. *International Journal of Oral and Maxillofacial Implants* **5**: 247–253.
- Sbordone, L., Barone, A., Ramaglia, L., Ciaglia, R.N. & Iancono, V.J. (1995) Antimicrobial susceptibility of periodontopathic bacteria associated with failing implants. *Journal of Periodontology* **66**: 69–74.
- Sbordone, L., Barone, A., Ciaglia, R.N., Ramaglia, L. & Iancono, V.J. (1999) Longitudinal study of dental implants in a periodontally compromised population. *Journal of Periodontology* **70**: 1322–1329.
- Schou, S., Holmstrup, P., Hjørting-Hansen, E. & Lang, N.P. (1992) Plaque induced marginal tissue reactions of osseointegrated oral implants: a review of the literature. *Clinical Oral Implants Research* **3**: 149–161.
- Schou, S., Holmstrup, P., Stoltz, K., Hjørting-Hansen, E. & Korman, K.S. (1993) Ligature-induced marginal inflammation around osseointegrated implants and ankylosed teeth. Clinical and radiographic observations in cynomolgus monkeys (*Macaca fascicularis*). *Clinical Oral Implants Research* **4**: 12–22.
- Schou, S., Holmstrup, P., Keiding, N. & Fiehn, N.-E. (1996) Microbiology of ligature-induced marginal inflammation around osseointegrated implants and ankylosed teeth in cynomolgus monkeys (*Macaca fascicularis*). *Clinical Oral Implants Research* **7**: 190–200.
- Schwartz, S.F. & Foster, J.K. (1971) Roentgenographic interpretation of experimentally produced bony lesions. *Oral Surgery, Oral Medicine, Oral Pathology* **32**: 606–612.
- Shaffer, M.D., Jurua, D.A. & Haggerty, P.C. (1998) The effect of periradicular endodontic pathosis on the apical region of adjacent implants. *Oral Surgery, Oral Medicine, Oral Pathology* **86**: 578–581.
- Slots, J. (1977) The predominant cultivable microflora in advanced periodontitis. *Scandinavian Journal of Dental Research* **12**: 112–121.
- Slots, J. & Genco, R.J. (1984) Black-pigmented *Bacteroides* species, *Capnocytophaga* species and *Actino-*

- bacillus actinomycetemcomitans* in human periodontal disease: virulence factors in colonization, survival, and tissue destruction. *Journal of Dental Research* **63**: 412–421.
- Slots, J. & Rams, T. E. (1991) New views on periodontal microbiota in special patient categories. *Journal of Clinical Periodontology* **18**: 411–420.
- Slots, J., Moenbo, D., Langenbeck, J. & Frandsen, A. (1978) Microbiota of gingivitis in man. *Scandinavian Journal of Dental Research* **86**: 174–181.
- Slots, J., Rams, T.E. & Listgarten, M.A. (1988) Yeasts, enteric rods and pseudomonads in the subgingival flora of severe adult periodontitis. *Oral Microbiology and Immunology* **3**: 47–52.
- Slots, J., Smith MacDonald, E & Nowzari, H. (1999) Infectious aspects of periodontal regeneration. *Periodontology* **2000** **19**: 164–172.
- Socransky, S.S. & Haffajee, A.D. (1992) The bacterial etiology of destructive periodontal disease: current concepts. *Journal of Periodontology* **63**: 322–331.
- Smedberg, J.L., Beck, C.B. & Embery, G. (1993) Glycosaminoglycans in peri-implant sulcus fluid from implants supporting fixed or removable prostheses. *Clinical Oral Implants Research* **4**: 137–143.
- Speelman, J.A., Collaert, B. & Klinge, B. (1992) Evaluation of different methods to clean titanium abutments. A scanning electron microscopic study. *Clinical Oral Implants Research* **3**: 120–127.
- Sussman, H.I. & Moss, S.S. (1993) Localized osteomyelitis secondary to endodontic-implant pathosis. A case report. *Journal of Periodontology* **64**: 306–310.
- Tillmanns, H.W.S., Hermann, J.S., Cagna, D.R., Burgess, A.V. & Meffert, R.M. (1997) Evaluation of three different dental implants in ligature-induced peri-implantitis in the beagle dog. Part I. Clinical evaluation. *International Journal of Oral and Maxillofacial Implants* **12**: 611–620.
- Tillmanns, H.W.S., Hermann, J.S., Tiffée, J.C., Burgess, A.V. & Meffert, R.M. (1998) Evaluation of three different dental implants in ligature-induced peri-implantitis in the beagle dog. Part II. Histology and microbiology. *International Journal of Oral and Maxillofacial Implants* **13**: 59–68.
- Tonetti, M. (1998) Risk factors for osseodisintegration. *Periodontology* **2000** **17**: 55–62.
- Van der Stelt, P.F. (1985) Experimentally produced bone lesions. *Oral Surgery, Oral Medicine, Oral Pathology* **59**: 306–312.
- van Steenberghe, D., Lekholm, U., Bolender, C., Folmer, T., Henry, P., Herrmann, I., Higuchi, K., Laney, W., Lindén, U. & Åstran, P. (1990) The applicability of osseointegrated oral implants in the rehabilitation of partial edentulism: a prospective multicenter study on 558 fixtures. *International Journal of Oral and Maxillofacial Implants* **5**: 272–282.
- van Steenberghe, D., Yoshida, K., Papaioannou, W., Bollen, C.M.L., Reybrouck, G. & Quirynen, M. (1997) Complete nose coverage to prevent airborne contamination via nostrils is unnecessary. *Clinical Oral Implants Research* **8**: 512–516.
- van Steenberghe, D., Naert, I., Jacobs, R. & Quirynen, M. (1999a) Influence of inflammatory reactions vs. occlusal loading on peri-implant marginal bone level. *Advances in Dental Research* **13**: 130–135.
- van Steenberghe, D., Quirynen, M. & Naert, I. (1999b) Survival and success rates with oral endosseous implants. In: Lang, N.P., Karring, T., Lindhe, J., eds. *Proceedings of the 3rd European Workshop on Periodontology*. Berlin: Quintessence Books, 242–254.
- Veksler, A.E., Kayrouz, G.A. & Newman, M.G. (1991) Reduction of salivary bacteria by pre-procedural rinses with chlorhexidine 0.12%. *Journal of Periodontology* **62**: 649–651.
- von Troil-Lindén, B., Torkko, H., Alaluusua, S., Wolf, J., Jousimies-Somer, H. & Asikainen, S. (1995) Periodontal findings in spouses: a clinical, radiographic and microbiological study. *Journal of Clinical Periodontology* **22**: 93–99.
- Wahl, G., Muller, F. & Schaal, K.P. (1992) The microbial colonization of implant elements made of plastics and titanium. *Schweizer Monatsschrift für Zahnmedizin* **102**: 1321–1326.
- Wald, E.R. (1998) Microbiology of acute and chronic sinusitis in children and adults. *American Journal of the Medical Sciences* **316**: 13–20.
- Warrer, K., Buser, D., Lang, N.P. & Karring, T. (1995) Plaque-induced peri-implantitis in the presence or absence of keratinized mucosa. An experimental study in monkeys. *Clinical Oral Implants Research* **6**: 131–138.
- Wengraf, A. (1964) Radiologically occult bone cavities: an experimental study and review. *British Dental Journal* **117**: 532–536.
- Wennerberg, A., Albrektsson, T. & Andersson, B. (1993) Design and surface characteristics of 13 commercially available oral implant systems. *International Journal of Oral and Maxillofacial Implants* **8**: 622–633.
- Wetzel, A.C., Vlassis, J., Caffesse, R.G., Hämmerle, C.H.F. & Lang, N.P. (1999) Attempts to obtain reosseointegration following experimental peri-implantitis in dogs. *Clinical Oral Implants Research* **10**: 111–119.
- Weyant, R.J. & Burt, B.A. (1993) An assessment of survival rates and within-patient clustering of failures for endosseous oral implants. *Journal of Dental Research* **72**: 2–8.
- Willems, G., Lambrechts, P., Braem, M., Vuylsteke-Wauters, M. & Vanherle, G. (1991) The surface roughness of enamel-to-enamel contact areas compared with the intrinsic roughness of dental resin composites. *Journal of Dental Research* **70**: 1299–1305.
- Wolff, L., Dahlén, G. & Aeppli, D. (1994) Bacteria as risk markers for periodontitis. *Journal of Periodontology* **65** (Suppl): 498–510.
- Worthington, P., Bolender, C.L., & Taylor, T.D. (1987) The Swedish system of osseointegrated implants: problems and complications encountered during a 4-year trial period. *International Journal of Oral and Maxillofacial Implants* **2**: 77–84.