

See discussions, stats, and author profiles for this publication at: <https://www.researchgate.net/publication/307012348>

Fungal esophagitis in a child with insulin dependent diabetes mellitus

Article in *Journal of the College of Physicians and Surgeons--Pakistan: JCPSP* · August 2016

CITATIONS

0

READS

28

1 author:



[Anjum Saeed](#)

The Children's Hospital and the Institute of Child Health

23 PUBLICATIONS 29 CITATIONS

SEE PROFILE

Fungal Esophagitis in a Child with Insulin Dependent Diabetes Mellitus

Anjum Saeed^{1,2}, Asaad Assiri^{1,2}, Zafar Zaidi¹ and Abdulmalik Alsheikh³

ABSTRACT

Esophagitis in children is not uncommon, mostly due to gastro-esophageal reflux. Other conditions like eosinophilic and infective esophagitis need to be elucidated in differential diagnoses. Fungal or *Candida esophagitis* usually occurs in high risk children who are immune-compromised, malnourished, on steroid therapy or have uncontrolled diabetes mellitus. An eleven-year girl presented with uncontrolled type I diabetes mellitus and recurrent epigastric pain with vomiting. Her oral intake was satisfactory. There was no dysphagia and odynophagia. Physical examination was normal with good oral hygiene. Failure in responding to conventional medications led to endoscopic evaluation, which revealed white patches and esophageal inflammation and diagnosed as fungal esophagitis on histopathology. Although infective esophagitis is encountered sporadically in pediatric age group, but it should always be considered in high risk individuals and when conventional medication fails to resolve the symptoms.

Key Words: *Diabetes mellitus. Fungal esophagitis. Children. Candidiasis. Recurrent epigastric pain.*

INTRODUCTION

Esophagitis of myriad origin is not an uncommon entity in children. Infective esophagitis is one of the rare causes of esophagitis in pediatric age group affecting mainly the immune-compromised individuals.¹ Local and invasive candidiasis is one of the most common opportunistic infections within the spectrum of impaired immune functions. In adults, *Candida esophagitis* is seen in acquired immune deficiency syndrome (AIDS)² but in children it afflicts those who are malnourished, broad spectrum antibiotics recipients, on steroids, immune-suppressed or have uncontrolled diabetes mellitus. The common presentation is with epigastric pain, dysphagia and heart burn with or without vomiting. Diagnosis rests on isolating fungal spores and *Candida* in the biopsy specimen. Treating with antifungal agents has a good response in relief of symptoms as well as in curing invasive disease.³

CASE REPORT

An 11-year girl, a known case of poorly controlled insulin dependent diabetes mellitus (IDDM) since the age of 5 years, was referred with abdominal pain, mainly in the epigastric region with heart burns for 9 months. The pain

worsened after meals. She had off and on vomiting of food contents without any hematemesis or melena. She denied having any dysphagia, odynophagia, abdominal distension, diarrhea, constipation, and weight loss although her mother was concerned about her growth. Her diabetes was badly controlled due to poor compliance to diet. She was given multiple medications for abdominal pain including antacid, proton pump inhibitor (PPI), antispasmodic and an empirical trial of triple therapy for *Helicobacter pylori* infection (Amoxicillin, clarithromycin and pantoprazole) without an effective response. Her physical examination was unremarkable except mild tenderness in the epigastric area. She did not have oral thrush.

Due to chronic nature of her symptoms, she was advised a battery of tests which included CBC, celiac markers, liver function tests (LFTs), ultrasound abdomen; all being unremarkable. She underwent upper gastrointestinal (GI) endoscopic evaluation, which showed severe esophagitis with extensive white patches in the middle and lower esophagus. There was moderate to severe gastritis without any antral nodularity. Duodenum was unremarkable. Histopathology confirmed chronic esophagitis and gastritis without any evidence of *Helicobacter pylori* and celiac disease. There were multiple fungal spores identified in the esophageal biopsies, which were later confirmed as *Candida* as shown in Figure 1. She was treated with fluconazole for 2 weeks and PPI for 8 weeks thus her symptoms disappeared in 3 - 4 weeks after the institution of therapy.

DISCUSSION

Fungal esophagitis in diabetics has been reported in adults⁴ but data for pediatric patients are very limited. To

¹ Department of Pediatric / Histopathology³, King Khalid University Hospital, King Saud University, Riyadh, Saudi Arabia.

² Prince Abdullah Bin Khalid Celiac Disease Research Chair, King Saud University Medical City, Riyadh, Saudi Arabia.

Correspondence: Dr. Anjum Saeed, Department of Pediatric # 39, King Khalid University Hospital, King Saud University, Riyadh, Saudi Arabia.

E-mail: anjum2002@hotmail.com

Received: May 25, 2015; Accepted: March 21, 2016.

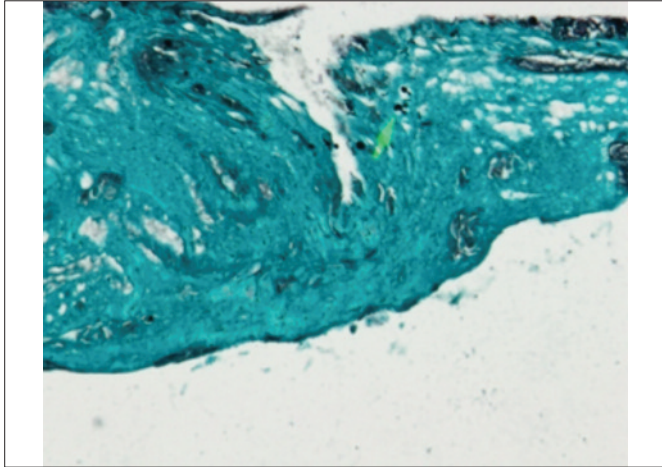


Figure 1: Spores and hyphae in esophageal biopsy specimen. (Grocott Methanamine Silver (GMS) stain, original magnification x400).

the best of our knowledge, this is the first case report from Saudi Arabia regarding this association or complication in a diabetic child. *Candida esophagitis* and other fungal infections, though not very uncommon in immune-compromised children but seeing in diabetics, need consideration to look for possible non-compliance to diet or medicine or both.⁵

Presentation of esophageal candidiasis in children includes odynophagia, dysphagia and retrosternal discomfort.⁶ Concomitant oral thrush may or may not be present. Oral thrush does not predict involvement of esophagus in immune-compromised children and severe esophagitis can be present without oral thrush or candidiasis.⁷ Esophageal candidiasis is found in uncontrolled diabetics only in those who are either non-compliant to diet or medication as in this case. Complications of fungal esophagitis include systemic candidiasis, esophageal dysmotility, stricture, fistulae and perforation.

Diagnosis of esophageal candidiasis mainly depends upon endoscopic findings confirmed by histopathology. *Candida* gives classical appearance to mucosa in the form of white plaques, which are difficult to wash and even brushing makes the mucosa bleeds but does not wash it away. The colour of these plaques can be pale or white.⁷ Allergic esophagitis like eosinophilic esophagitis can have similar appearance and can only be confirmed by histopathology. Hyphae or spores presence in the biopsy specimen are diagnostic for candidal infection,⁸ as shown in the Figure 1.

Reassurance regarding proper compliance to diet and medications for primary disease like diabetes is the cornerstone of management. Nystatin is a good choice in immune-competent children. Other more effective and convenient anti-fungals are fluconazole and amphotericin in immune compromised children.^{9,10} Two to six weeks institution of anti-fungal is sufficient for clearing the infection. Necrotizing esophageal candida infection may need surgical resection with diversion. Failure to respond to conventional medications should prompt the physicians to look for other causes and investigate further to avoid the morbidities associated with this condition.

Acknowledgement: This case report was financially supported by King Saud University through Vice Deanship of scientific research chairs, Riyadh, KSA.

REFERENCES

1. Braegger CP, Albisetti M, Nadal D. Extensive esophageal candidiasis in the absence of oral lesions in pediatric AIDS. *J Pediatr Gastroenterol Nutr* 1995; **21**:104-6.
2. Laine L, Boncini M. Esophageal disease in human immunodeficiency virus infection. *Arch Intern Med* 1994; **154**: 1577-82.
3. Darouiche RO. Oropharyngeal and esophageal candidiasis in immunocompromised patients: Treatment issues. *Clin Infect Dis* 1998; **26**:259.
4. Yakoob J, Jafri W, Abid S. Candida esophagitis: Risk factors in non-HIV population in Pakistan. *World J Gastroenterol* 2003; **9**: 2328-31.
5. Danielle PCM, Neiva TO, Aline MAF. Esophagitis caused by *Candida guilliermondii* in diabetes mellitus: First reported case. *Med Mycol* 2010; **48**:862-5.
6. Riestra S, Sleiman H, Suárez A. Esophagitis caused by *Candida albicans*. *Rev Esp Enferm Apar Dig* 1989; **76**:188-93.
7. Boncini M, Young T, Laine L. The causes of esophageal symptoms in human immunodeficiency virus infection: A prospective study of 110 patients. *Arch Intern Med* 1991; **151**:1567-72.
8. Mathieson R, Dutta SK. *Candida esophagitis*. *Dig Dis Sci* 1983; **28**:365-70.
9. Committee on Infectious Diseases. Candidiasis. In: 2006 Red Book: Report of the Committee on Infectious Diseases. *American Academy of Pediatrics*; 2006: 242-6.
10. Committee on Infectious Diseases. Antifungal drugs for systemic fungal infection. In: 2006 Red Book: Report of the Committee on Infectious Diseases. 27th ed. *American Academy of Pediatrics*; 2006: 774-6.

....☆....