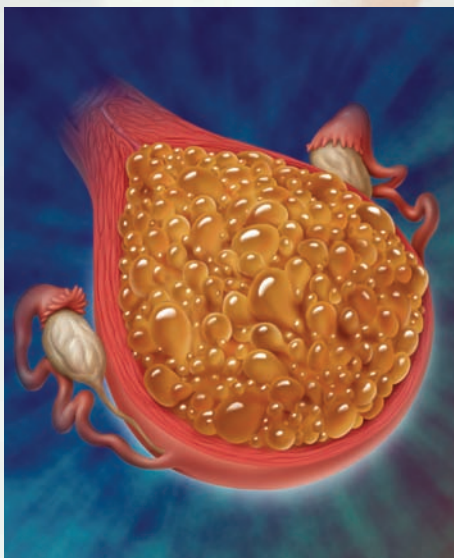


MARY DiGIULIO, DNP, APN, SUSAN WIEDASECK, DNP, CNM,  
RUTH MONCHEK, MSN, CNM

# UNDERSTANDING HYDATIDIFORM MOLE



Brian Evans / Science Photo Library

## Abstract

Hydatidiform mole (often referred to as molar pregnancy) is the most common disorder in a category of pathologies known as Gestational Trophoblastic Diseases that are associated with abnormal fertilization in pregnancy. Current practices in screening and monitoring during early pregnancy allow for better identification of hydatidiform mole, sometimes prior to the onset of significant symptoms.

Once a diagnosis is established, a thorough physical examination and laboratory testing are necessary. Initial treatment includes uterine evacuation. Serial monitoring of serum human chorionic gonadotropin levels is warranted until levels become nondetectable and continues for another 6 months. Reliable contraception is necessary until it has been determined that no trophoblastic tissue persists.

Pregnancy is usually a joyful time, with maternal attachment to the developing fetus beginning early in the pregnancy. The woman who experiences hydatiform mole, however, must face the inability to maintain this pregnancy, the possible health consequences of the mole, and then be allowed the time to grieve. Nurses can be the first-line in providing compassionate, empathetic care for women in these circumstances.

**Keywords:** Gestational trophoblastic disease; Hydatidiform mole; Molar pregnancy; Pregnancy loss.

For most women, pregnancy is a normal event with a healthy baby and a happy outcome. However, the nurse who specializes in obstetrics needs to be aware of not only the progression of normal pregnancy but also needs to have an understanding of the pathological conditions that can occur in pregnant women. A knowledge of the various pathologies helps the nurse to participate as an effective member of the health-care team. Hydatidiform mole (HM) is one of these conditions. Although the incidence of HM is low, ranging from 0.6 to 1.1 per 1,000 pregnancies in Europe and North America, respectively (Batorfi et al., 2004; Berkowitz & Goldstein, 2009a). When obstetric nurses are faced with a patient with this diagnosis, they need to have a plethora of information at their fingertips in order to administer comprehensive care to these high-risk women.

HM is one of the conditions in a category of pathologies known as Gestational Trophoblastic Disease (GTD) that are associated with abnormal fertilization in pregnancy. GTD encompasses HM, invasive mole, and choriocarcinoma. These pathologies range from relatively benign to invasive neoplasia. These conditions had a high rate of fatal outcomes in the past, but currently have a 98% cure rate with proper diagnosis and treatment (Seckl, Sebire, & Berkowitz, 2010). HM is the most common form of GTD and can be easily treated if properly identified. Prior molar pregnancy increases subsequent risk of recurrence (Seckl et al., 2010). However, there is a 10% risk that a woman who has a molar pregnancy will develop one of the malignant gestational trophoblastic conditions such as choriocarcinoma, placental site trophoblastic tumor, or invasive mole (Sebire, 2006; Sebire & Seckl, 2008). There is a possibility of gestational trophoblastic neoplasia (GTN) following any pregnancy, including spontaneous miscarriage, elective abortion, or ectopic pregnancy. Therefore, it is important that the nurse who works in women's health should be knowledgeable about these conditions, the method of diagnosis, and usual treatments.

A prior history of HM increases the risk of a recurrent molar pregnancy. There are conflicting reports, however, about whether a partial or complete HM poses a greater risk for future pregnancies. Garner, Lipson, Bernstein, Goldstein, & Berkowitz (2002) found that the risk of a recurrent molar pregnancy was 1 in 100 pregnancies compared with the 1 in 1,000 risk found in the rest of the population. By contrast, Soper, Mutch, and Schink (2004) found the recurrence rate to be as high as 2% after a prior molar pregnancy. The greatest risk for recurrence appears to be within the first 6 months after the initial treatment (Garner et al., 2002; Paul et al., 2010).

The majority of molar pregnancies occur in women between the ages of 20 and 40, as the greatest overall number of pregnancies occurs in this age group. However, there is a disproportionately higher risk of molar pregnancy in younger and older women. Teenagers' risk of molar pregnancy is six times higher than in women older than 19, and women over 40 have a risk that is 10 times higher than the risk to women between the ages of 20 and 40 (Cunningham et al., 2010; Masterson, Chan, & Bluhm, 2009).

## Pathophysiology of Hydatidiform Mole

HM is the result of a defect in the fertilization process, and can be either partial or complete. A complete mole (CM) usually has a paternal chromosomal component but no maternal chromosomal component because there has been fertilization of an ovum that does not have a nucleus (an empty egg), resulting in the sperm duplicating solely from its own chromosomes. In CM there is no evidence of fetal development, only a proliferation of the trophoblastic tissue.

In a partial mole (PM), there is overgrowth of the trophoblastic tissue and abnormal fetal development (Moore, Hernandez, & Roth, 2008). PM pregnancy will typically have a triploid karyotype most commonly consisting of one maternal set of 23 chromosomes (haploid) and two paternal haploids, resulting in 69 chromosomes (Jain, 2005; Soper, 2006). In some instances, there will be a tetraploid karyotype, consisting of three paternal and one maternal haploids (Seckl et al., 2010), leading to early pregnancy loss (Cunningham et al., 2010; Jain, 2005; Soper, 2006). On rare occasions, a woman can have a coexisting normal fetus and molar pregnancy in a multiple gestation (Cunningham et al., 2010; Jain, 2005; Soper, 2006).

The abnormal fertilization in both CM and PM allows the trophoblastic tissue to proliferate, eventually filling the uterine cavity. The increase in trophoblastic tissue causes excessive secretion of human chorionic gonadotropin (HCG) that causes the nausea and vomiting associated with this condition. As some of the trophoblastic tissue deteriorates, there may be formation of blood clots between the trophoblastic villi and the endometrial lining. These blood clots eventually disintegrate, resulting in vaginal bleeding. The trophoblastic tissue may also release chemical substances that will cause maternal vasospasm and signs of preeclampsia (Cunningham et al., 2010). The elevated levels of HCG may cause hyperstimulation of the ovaries; this in turn will lead to the development of multiple cysts on the ovaries, known as theca lutein cysts.

HCG is one of the major hormones produced in early pregnancy primarily by the syncytiotrophoblast. It begins to enter the maternal blood stream 5 days after implantation of the fertilized ovum in the uterine lining. In a normal pregnancy, the nurse can expect that the level of HCG will double every 48 hours for the first 100 days of the pregnancy to a level of approximately 100,000 mIU/mL, after which the HCG should decline to a lower level that will remain constant for the duration of the pregnancy. The serum levels of HCG in a woman with HM will be substantially higher than expected (Berkowitz & Goldstein, 2009a, 2009b; Cunningham et al., 2010).

## Clinical presentation

Women with HM may be asymptomatic, or they may experience multiple symptoms such as:

- *Vaginal Bleeding.* Vaginal bleeding is often one of the first symptoms of HM (Berkowitz & Goldstein, 2009a; Sebire & Seckl, 2008). Bleeding can range



THE ABILITY TO DIAGNOSE HYDATIDIFORM MOLE EARLY IN PREGNANCY HAS IMPROVED GREATLY OVER THE PAST TWO DECADES DUE TO THE USE OF ULTRASOUND EARLY IN PREGNANCY.

from scant brownish discharge to bright red vaginal bleeding. Often the healthcare provider (physician, midwife, nurse practitioner, or physician assistant) will suspect that an impending miscarriage is occurring and order an ultrasound and an HCG level. It is at this point that the tests will reveal an HM. If bleeding is prolonged or severe, anemia may occur in the patient.

- *Greater Than Expected Nausea and Vomiting (Hyperemesis)*. The elevated HCG levels may cause severe nausea and vomiting; this can lead to dehydration and weight loss for the pregnant woman. Although some nausea and vomiting are normal in early pregnancy. The nausea and vomiting associated with the HM is more severe and lasts longer than in normal pregnancy (Berkowitz & Goldstein, 2009a; Cunningham et al., 2010; Sebire & Seckl, 2008; Soper, 2006).
- *Increased Pelvic Pressure* due to the greater than expected uterine enlargement.
- *Anemia* secondary to bleeding.
- *Maternal Hypertension*, which may present as signs and symptoms of preeclampsia before 20 weeks of gestation, is also a possible presentation of HM. This early development of maternal hypertension should raise suspicion of possible HM (Berkowitz & Goldstein, 2009a; Cunningham et al., 2010; Sebire & Seckl, 2008; Soper, 2006).

Physical examination remains an important part of the assessment of the woman who has a suspected HM. In HM, this examination will reveal a uterus that is larger than expected for the stated gestational age, and the ovaries may be enlarged due to the presence of theca lutein cysts. These changes are responsible for a sensation of increased pelvic pressure. There will be absence of fetal heart tones (Soper, 2006). With the widespread use of ultrasound in the first trimester, the HM may be diagnosed before any clinical signs are present.

### Diagnosis

Molar pregnancy can be confined to the uterus or progress into a systematic disease that has profound effects on the health of the woman. The potential ramifications, metastatic malignancy due to choriocarcinoma, might be avoided with early diagnosis and intervention. The healthcare provider may suspect molar pregnancy when there are complications of vaginal bleeding, presence of continued vaginal bleeding after miscarriage, or unexplained amenorrhea after vaginal delivery (Berkowitz & Goldstein, 2009a). Physical examination may reveal an

enlarged uterus or ovaries. Diagnosis cannot be made on the basis of the patient's symptoms and physical examination alone, but also ultrasound and a serum HCG level. These tests can reveal a molar pregnancy at an earlier stage, thus allowing for prompt treatment.

HCG testing is utilized in the first trimester as an indicator that pregnancy is progressing normally. If the level is lower than expected it could suggest that the gestational age is inaccurate or that there may be a risk of impending miscarriage. If the level is higher than expected it may indicate an inaccurate gestational age, a multiple gestation, or an HM. HCG testing may be ordered when the healthcare provider suspects HM based on the patient's history, symptoms, and physical examination. After evacuation of a molar pregnancy, the HCG levels are expected to return to nondetectable levels within 8 weeks (Seckl et al., 2010). A hallmark of persistent trophoblastic disease is that there is a continuing level of HCG. The nurse can expect that the healthcare provider will order serial HCG levels to monitor the expected decrease in the levels of HCG. These levels should decrease and eventually become nondetectable. If the level of HCG does not decrease, then further evaluation of the patient will be needed.

The ability to diagnose HM early in a pregnancy has improved greatly over the past two decades due to the use of ultrasound. In a normal pregnancy, the ultrasound will reveal the fetus, placenta, and the amniotic fluid. In a woman with a CM, the ultrasound will reveal a uterine cavity that is filled with small cysts. These cysts are sometimes referred to as "grape-like clusters" (Jain, 2005). There are no identifiable fetal parts in CM. The ovaries will appear to be enlarged as a result of the presence of theca lutein cysts. The quality of a transvaginal ultrasound image allows for diagnosis of some molar pregnancies in an asymptomatic patient. There is some variation in the efficacy of ultrasound for diagnosis, with a greater ability to accurately detect a CM (Berkowitz & Goldstein, 2009a, 2009b; Masterson et al., 2009). Up to 60% of CM may be detected by routine ultrasound. However, in Seckl et al's study, 10% of the sonogram results thought to be molar pregnancy were, in fact, hydropic nonviable pregnancies (Seckl et al., 2010).

A partial hydatidiform molar pregnancy is diagnosed in the same manner as a CM. The symptoms at time of presentation, however, tend to be milder. There is also a histologic difference in the genetic material of the PM versus the CM (Berkowitz, 2010).

## Management

Once a diagnosis is established, the patient should have a thorough physical examination and laboratory testing. Anemia, hyperthyroidism, and gestational hypertension are all potential complications related to the molar pregnancy. Determination of blood type is necessary if not already known. Women who are Rh negative will need Rh immune globulin in cases where the father is Rh positive or his Rh status cannot be determined (Berkowitz & Goldstein, 2009a). The nurse can anticipate that the healthcare provider will order the following laboratory studies: a complete blood count, coagulation studies, type and RH, a complete metabolic profile as well as serial HCG levels. Initial treatment involves suction evacuation of the uterine contents with Dilation and Evacuation (D&E). In some cases, hysterectomy may be necessary based on the extent of the pathology (Berkowitz & Goldstein, 2009a).

HCG levels need to be monitored after uterine evacuation in order to determine if all trophoblastic tissue has been removed. The nurse can expect that initial quantitative HCG determination will be ordered within the first 2 days after D&E. Weekly monitoring of quantitative serum HCG levels continues until three successive nondetectable levels are achieved. At this point, testing becomes monthly and is continued for the next 6 months (Batorfi et al., 2004; Berkowitz & Goldstein, 2009a; Soper, Mutch & Schink, 2004; Soper, 2006). It is important to prevent another pregnancy until it has been determined that no trophoblastic disease persists, for HCG levels will be compromised during the early stages of pregnancy, and treatment options also become far more complex if the woman conceives and then learns that surgical intervention or chemotherapy will be necessary. Therefore, reliable contraception is recommended through the completion of this 6-month follow-up period. As always, it is important to consider potential contraindications to any particular method of contraception (Cunningham et al., 2010; Seckl et al., 2010). If HCG levels persist, GTN is suspected. GTN may include several different malignant conditions including choriocarcinoma or placental site trophoblastic tumor (Aghajanian, 2011). GTN occurs in 15% to 29% of the women who have a CM (Berkowitz & Goldstein, 2009a, 2009b; Soper, 2006). The trophoblastic cells may enter the blood stream and metastasize to other areas of the body, and can be fatal if left untreated. If the woman develops GTN, she will be referred to gynecologic oncologist for evaluation and chemotherapy.

## Psychosocial Implications

The untimely end of a pregnancy, whether it is due to a miscarriage, stillbirth, or a condition such as HM, is a profoundly sad experience for a woman. Pregnancy is usually a time of joyful anticipation for most women as they sense the growth of a new life within their bodies and start to dream of a life with their child. Maternal attachment to a developing fetus has been shown to develop early in the gestational period (Alhusen, 2008). When a woman experiences a pregnancy loss, she must face not only the premature end of her pregnancy but also the loss of the anticipated life with her child.

Although much has been written about perinatal bereavement in general, very little attention has been paid to the psychosocial needs of women who have experienced molar pregnancy. Their unique condition as an obstetrical pathology is not the loss of an embryo but an aberrant growth of trophoblastic tissue. However, while those in the medical field will classify this disease as unfortunate twist of fate in a doomed pregnancy, women who suffer this condition still experience the loss of an anticipated baby. When nurses encounter these patients, it becomes important to acknowledge their condition as a pregnancy loss (Thorstensen, 2000). It is crucial that these women be allowed to grieve the passing of their child.

Women with molar pregnancy or GTD must cope with an unsuccessful pregnancy as well as contend with the possibility of a serious illness. They face the devastating task of having to absorb information about the diagnosis and treatment of a possibly life-threatening cancer while they are brokenhearted about an unsuccessful pregnancy (Peterson, Ung, Holland, & Quinlivan, 2005). Nurses play a critical role in providing care for these women by offering clear, factual information and offering supportive, empathetic care.

Peterson, Ung, Holland, and Quinlivan (2005) demonstrated that women with a diagnosis of molar pregnancy felt a sense of isolation because of the unusual nature of their condition and the fact that its cause is not well understood by both the general public and healthcare providers. Women dealing with these uncertainties commonly face the additional burden of depression and anxiety (Garner, Goldstein, Berkowitz, & Wenzel, 2003; Peterson et al., 2005).

The fact that women who have had molar pregnancy must be medically monitored for an extended period of time for the potential development of cancer can adversely affect a woman's perceptions of her sexuality and future fertility (Bess & Wood, 2006). Patients who receive chemotherapy for persistent GTN often feel defective after treatment (Garner et al., 2003). These women must also handle the disappointment of delaying future fertility as they go through a lengthy monitoring and/or treatment phase. The timing of their next pregnancy will most likely be recommended by their OB/GYN provider or GYN oncologist (Thorstensen, 2000).

Having had a molar pregnancy does not negatively impact future fertility and even women who have received chemotherapy for GTN can expect that their fertility will be preserved (Garner et al., 2003). Côté-Arsenault (2007) found that there is an increased incidence of "pregnancy anxiety" about subsequent pregnancies after a prenatal loss related to the apprehension of a new pregnancy and concern over a subsequent reoccurrence the condition. Women who have dealt with molar pregnancy or GTD have the additional stress of worrying about the recurrence of this disease and its medical treatment in any future pregnancies. This fear of recurrence has been shown to persist for many years in women who have survived this diagnosis (Garner et al., 2003).

Attendance at a support group for grieving patients who have experienced a molar pregnancy has been demonstrated to assist with successful coping after this perinatal loss (Peterson et al., 2005). There may be a low availability of support groups specifically for those patients who have

dealt with molar pregnancy or GTD, but traditional bereavement support groups for perinatal loss are more plentiful. D'Marco, Menke, and McNamara (2001) published evidence that support groups were useful, but group participants did feel that they were better able to voice their emotions with people who had been through similar experiences than with a well-meaning healthcare provider. Garner et al. (2003) found that 74% of those who had experienced a diagnosis of molar pregnancy or GTD stated that they would probably have joined a support group if one had been available to them.

## Implications for Nursing Practice

Nurses who work in obstetrics could eventually find themselves caring for a woman with a molar pregnancy, and be on the front line in providing care that is informed and compassionate. It is imperative that obstetric nurses keep current on this pathology so they can educate women about the condition, the required ongoing management and follow-up, as well the possible impact on future pregnancies.

Nurses should be aware of the required diagnostic testing and follow-up for women experiencing GTD. Scheduling of tests within the appropriate time frame is important to not only identify but also monitor disease progression. Monitoring patients' compliance with the recommended course of therapy can help to reduce the likelihood of patients being lost to follow-up.

Coping with perinatal loss is a task that nurses find themselves involved with on a regular basis. It has been shown that RNs must be comfortable with the bereavement process in order to provide effective care for women experiencing a pregnancy loss (Roehrs, Masterson, Alles, Witt, & Rutt, 2008). The experience of molar pregnancy is eventually a grieving experience, and when obstetric nurses are familiar with the literature on grief and grieving, they have an opportunity to provide the best evidence-based care. Patient participation in a bereavement group is a personal decision. Nurses should be aware of the available resources in the region in order to refer patients who are interested in participating.

## Conclusion

The nurse caring for a woman who has HM needs to be aware of the pathophysiology, methods of diagnosis, and treatment for this condition. The patient should be counseled on the need for early treatment, serial HCG testing, and continued surveillance by the healthcare provider. She needs to be supported in her grief over her loss and encouraged to be optimistic about future health and fertility options. In conclusion, it is a knowledgeable and empathetic nurse who can positively impact the medical and emotional recovery of a woman who has gone through the overwhelming ordeal of GTD or molar pregnancy. ❖

Mary DiGiulio is an Assistant Professor at the University of Medicine & Dentistry of New Jersey.

Susan Wiedaseck is an Assistant Professor at the University of Medicine & Dentistry of New Jersey. She can be reached via e-mail at [wiedassa@umdnj.edu](mailto:wiedassa@umdnj.edu).

Ruth Monchek is an Associate Professor at the University of Medicine & Dentistry of New Jersey.

The authors note no conflict of interest.

DOI:10.1097/NMC.0b013e31823853c4

## References

- Aghajanian, C. (2011). Treatment of low-risk gestational trophoblastic neoplasia. *Journal of Clinical Oncology*, 29(7), 786-788. doi: 10.1200/JCO.2010.31.0151.
- Alhusen, J. L. (2008). A literature update on neonatal-fetal attachment. *Journal of Obstetric, Gynecologic, and Neonatal Nursing*, 37(3), 315-328. doi: 10.1111/j.1552-6909.2008.00241.x
- Batorfi, J., Vegh, G., Szepesi, J., Szigetvari, I., Doszpod, J., & Fulop, V. (2004). How long should patients be followed after molar pregnancy? Analysis of serum hCG follow up data. *European Journal of Obstetrics & Gynecology and Reproductive Biology*, 112(2004), 95-97.
- Berkowitz, R. S., (2010) Gestational trophoblastic disease. Presentations from the XVth World Congress on gestational trophoblastic diseases. *Journal of Reproductive Medicine*. 2010 May-Jun;55(5-6):182-3
- Berkowitz, R. S., & Goldstein, D. P. (2009a). Current management of gestational trophoblastic disease. *Gynecologic Oncology*, 112, 654-662. doi: 10.1016/j.ygyno.2008.90.005
- Berkowitz, R. S., & Goldstein, D. P. (2009b). Molar pregnancy. *New England Journal of Medicine*, 360(16), 1639-1645.
- Bess, K. A., & Wood, T. L. (2006). How nurses can help those dealing with a diagnosis. *AWHONN Lifelines*, 10(4) 320-326. doi: 10.1111/j.1552-6356.2006.00055.x
- Côté-Arsenault, D. (2007). Threat appraisal, coping, and emotions across pregnancy subsequent to perinatal loss. *Nursing Research*, 56(2) 108-116. doi: 10.1097/01.NNR.0000263970.08878.78
- Cunningham, F. G., Leveno, K. L., Bloom, S. L., Hauth, J. C., Gilstrap, L. C. III, & Westrom, K. D., (2010) Gestational Trophoblastic Disease (chapter 11) in *Williams Obstetrics* (23rd ed). Retrieved from <http://accessmedicine.com/content.aspx?ald721538>
- D'Marco, M. A., Menke, E. M., & McNamara, T. (2001). Evaluating a support group for perinatal loss. *The American Journal of Maternal and Child Care*, 26(3), 135-140.
- Garner, E. L., Lipson, E., Bernstein, M. R., Goldstein, D. P., & Berkowitz, R. S. (2002). Subsequent pregnancy experience in patients with molar pregnancy and gestational trophoblastic tumor. *Journal of Reproductive Medicine*, 47(5), 380-386.
- Garner, E., Goldstein, D. P., Berkowitz, R. S., & Wenzel, L. (2003). Psychosocial and reproductive outcomes of gestational trophoblastic diseases. *Best Practice & Research Clinical Obstetrics and Gynecology*, 17(6), 959-968. doi: 10.1016/S1521-6934(03)00093-2
- Jain, K. (2005). Gestational trophoblastic disease. *Ultrasound Quarterly*, 21(4), 245-253.
- Masterson, L., Chan, S. B., & Bluhm, B. (2009). Molar pregnancy in the emergency department. *Western Journal of Emergency Medicine*, 10(4), 295-296.
- Moore, L. E., Hernandez, E., & Roth, A. (2008). *Hydatidiform mole*. Retrieved from <http://emedicine-medscape.com/article/254657-overview>
- Paul, M., Goodman, S., Felix, J., Lewis, R., Hawkins, M., & Drey, E. (2010). Early molar pregnancy: Experience in a large abortion service. *Contraception*, 81(2010), 150-156.
- Peterson, R. W., Ung, K., Holland, C., & Quinlivan, J. A. (2005). The impact of molar pregnancy on psychological symptomatology, sexual function, and the quality of life. *Gynecologic Oncology*, 97(2005), 535-542. doi: 10.1016/j.ygyno.2005.01.015
- Roehrs, C., Masterson, A., Alles, R., Witt, C., & Rutt, P. (2008). Caring for families coping with perinatal loss. *Journal of Obstetric, Gynecologic, and Neonatal Nursing*, 37(6). 631-639. doi:10.1111/j.1552-6909.2008.00290.x
- Sebire, N. J. (2006). Hydatidiform mole and medical management of miscarriage. *British Medical Journal*, 332(7555), 1454. doi: 10.1136/bmj.332.7555.1454.
- Sebire, N. J., & Seckl, M. J. (2008). Clinical Review: Gestational trophoblastic disease: current management of hydatidiform mole. *British Medical Journal*, 337, a1193. doi: 10.1136/bmj.a1193
- Seckl, M. J., Sebire, N. J., & Berkowitz, R. S. (2010). Gestational trophoblastic disease. *Lancet*, 376, 717-729. doi: 10.1016/S0140-6736(10)60280-2
- Soper, J. T. (2006). Gestational trophoblastic disease. *Obstetrics and Gynecology*, 108(1), 176-187.
- Soper, J. T., Mutch, D. G., & Schink, J. C. (2004). Diagnosis and treatment of gestational trophoblastic disease ACOG Practice Bulletin No 53. *Gynecologic Oncology*, 93(2004), 575-585. doi: 10.1016/j.ygyno.2004.05.013
- Thorstensen, K. A. (2000). Midwifery management of first trimester bleeding and early pregnancy loss. *Journal of Nurse-Midwifery*, 45(6), 481-497.