

# A practical, algorithmic approach to diagnosing hair shaft disorders

Paradi Mirmirani<sup>1,2,3</sup>, MD, Kathie P. Huang<sup>4</sup>, MD, and Vera H. Price<sup>3</sup>, MD, FRCP(C)

<sup>1</sup>Department of Dermatology, The Permanente Medical Group, Vallejo, CA, <sup>2</sup>Department of Dermatology, Case Western Reserve University, Cleveland, OH, <sup>3</sup>Department of Dermatology, University of California, San Francisco, CA, and <sup>4</sup>Department of Dermatology, Brigham and Women's Hospital, Boston, MA, USA

## Correspondence

Dr. Paradi Mirmirani, MD  
Kaiser Permanente Vallejo Medical Center  
Department of Dermatology  
975 Sereno  
Drive Vallejo  
CA 94589  
USA  
E-mail: paradi.mirmirani@kp.org

Conflicts of interest: None.

Funding: None.

## Introduction

The production of the hair shaft in humans occurs through a complex orchestration of biological signals in the pilosebaceous unit. These signals result in cyclic periods of growth and rest in the hair follicle. Many different cell types are incorporated during the hair cycle to form the inner root sheath, hair cuticle, cortex and, in large fibers, the medulla. This cell differentiation results from the expression of major hair keratin genes. During the growth phase of the follicle, or anagen, the actively dividing cells of the matrix start the process of hair shaft formation. The main structural component of the hair shaft, the hair cortex, is composed of interdigitating keratinocytes oriented in a parallel fashion, and held together by the intercellular matrix protein. The hair shaft is protected by the cuticle layer with its overlapping cells that resemble shingles on a roof. If there is damage to the cuticle, the exposed hair cortex still holds together but is more susceptible to environmental damage and fracture.

The hair shaft is a unique structure in terms of its strength, resilience, flexibility, and resistance to the environment. Any defects in this normal structure due to

## Abstract

The hair shaft is a unique structure composed of an inner cortex and a protective outer cuticle. Any defects in this normal structure due to genetics or the environment can lead to variations in physical properties. Thus one should suspect a hair shaft disorder if a patient presents with an abnormality or change in hair texture, appearance, manageability or ability to grow hair long. A key feature of the clinical evaluation is to determine whether there is hair breakage (increased fragility) by looking for broken hairs and performing a tug test. Once this determination is made, an algorithmic approach can be used to narrow the differential diagnosis: hair shaft disorders with and without fragility. A hair mount along with other directed questions and examination will almost always allow the clinician to make an in-office diagnosis. Common case scenarios, photographs, and practical tips are provided to illustrate the use of this algorithmic approach in the diagnosis of hair shaft disorders. We have also included a summary of the molecular defects where known, which can be helpful in providing a correlation with clinical findings, in counseling patients, and potentially offering treatment options.

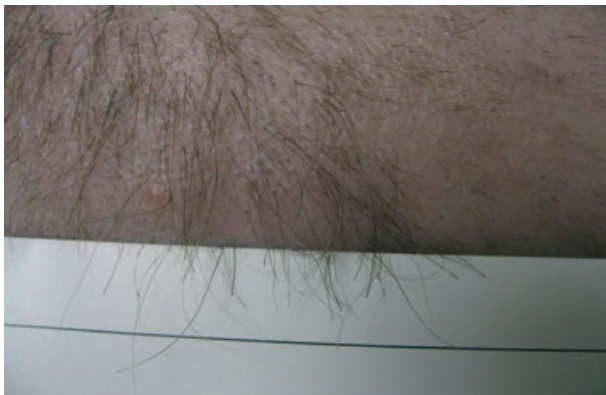genetics or the environment can lead to variations in physical properties, such as optics, shape, and strength. An alteration in these properties is clinically noticed as a change in strength (fragility, or inability to grow hair long), texture, appearance, and manageability. Thus, when a patient presents in the clinic with a chief complaint of "hair loss", the possible causes may be vast, but a thoughtful and stepwise approach will quickly uncover clues that will lead the clinician to suspect a hair shaft disorder.

## Approach to patients

- When should one suspect that a patient has a hair shaft disorder? Patients with hair shaft disorders will often present with one of the following complaints:
  - "My hair (or my child's hair) does not grow long" or "My child has never had a haircut."
  - "My hair (or my child's hair) has an unusual appearance and/or texture."
  - "My hair (or my child's hair) suddenly started breaking."
- What are pertinent questions to ask the patient? Directed questions will help the clinician narrow the differential diagnosis.

- When did the problem first start (has the problem been present since birth or was it acquired later in life)?
- Are there any problems with the nails or teeth?
- How does the patient style or process the hair? Ask about brushing technique, frequency of shampooing, use of heat and chemicals.
- Do other family members have similar findings?
- What is the best way to examine the hair?
  - Evaluate for “general appearance”, length, luster, curl, and color.
  - Note the “distribution” of the hair abnormality – diffuse or focal.
  - Determine if there is hair breakage: for the close-up examination of individual hair shafts, a contrasting paper (white for dark hair, black for light hair) can be used to improve visibility. By placing the card near the scalp and behind the hair being examined, one can determine if there are blunt or broken hair distal tips that would suggest breakage. These broken hairs can be differentiated from newly growing hairs that have tapered or pointed distal tips (Fig. 1). If fragility or breakage is suspected, it can be confirmed by performing a tug test (Fig. 2). This test consists of holding the hair several centimeters from the hair tip then tugging at the ends. If the hair is fragile, short 2–4mm hair fragments will easily break off. When these small fragments of hair are mounted on a glass slide with a mounting medium and cover slip (Fig. 3), characteristic changes of hair shaft disorders may be seen.
  - The scalp and the rest of the skin should also be examined for any changes.

If a clinician determines that a hair shaft disorder is likely, further classification and diagnosis can often be done in the office with a hair mount. An algorithmic



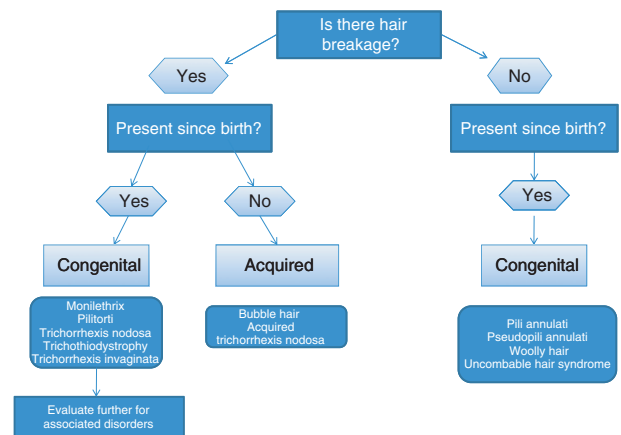
**Figure 1** Using a hair card can help determine if there are broken (blunt) hairs or tapered (new) hairs



**Figure 2** A tug test can be used to assess for hair fragility



**Figure 3** A hair mount can be used to evaluate the hair shaft using a glass slide, mounting medium, and a cover slip. Black and white contrasting backgrounds are used for ease of examining different colored hair



**Figure 4** An algorithmic approach to hair shaft disorders

**Table 1** Classification of hair shaft disorders

Hair shaft disorders with increased fragility	
Acquired	Bubble hair
	Acquired trichorrhexis nodosa
Congenital	Congenital trichorrhexis nodosa (arginosuccinic aciduria)
	Monilethrix
	Pili torti (Björnstad, Menkes)
	Trichorrhexis invaginata (Netherton syndrome)
	Trichothiodystrophy
Hair shaft disorders without increased fragility	
Congenital	Pili annulati
	Pseudopili annulati
	Woolly hair
	Uncombable hair syndrome

approach to making the diagnosis of a hair shaft disorder is presented (Fig. 4). This algorithm should be used as a guide and not an absolute, as variations and overlaps in hair shaft disorders are seen. Disorders of the hair shaft are typically segregated by those that are congenital or acquired; further classification is based on the presence or absence of hair shaft fragility that can lead to breakage (Table 1). A review of the most common hair shaft disorders is presented below. Although our emphasis is on the clinical presentation and diagnosis of the hair shaft disorder, we have included a summary of the molecular defects where known. Not only is an understanding of these molecular defects critical in understanding and correlating clinical findings, it is helpful in counseling patients and potentially offering treatment options.

### Acquired hair shaft disorders with increased fragility and breakage

#### Bubble hair and acquired trichorrhexis nodosa (TN)

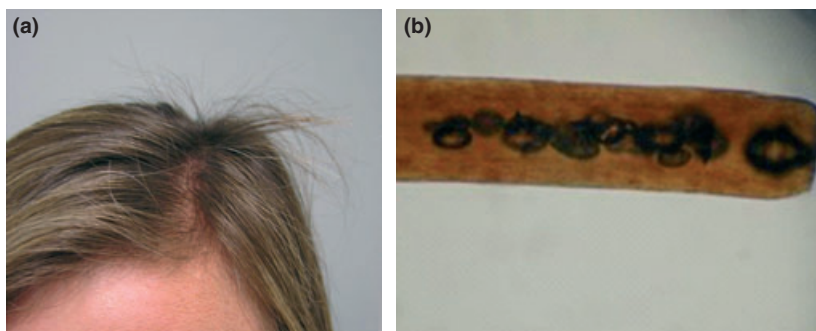
*Bubble hair clinical scenario: a young woman presents to clinic with a focal area of unruly and fly-away hair in the*

*vertex area of the scalp of a few months' duration (Fig. 5a). She regularly uses a hair dryer to style her hair. A tug test done on the affected hair is positive, indicating increased hair fragility. A hair mount reveals bubbles within the hair shaft, confirming a diagnosis of bubble hair (Fig. 5b).<sup>1</sup>*

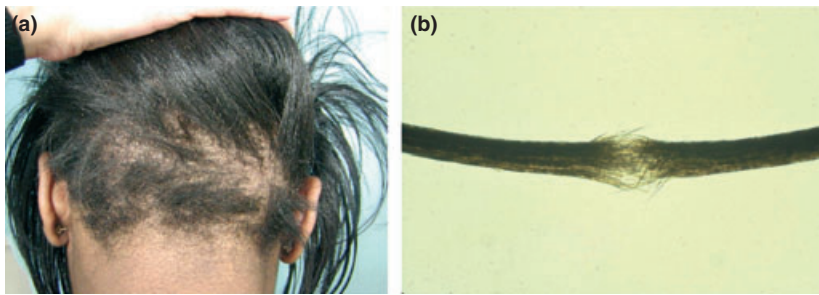
Bubble hair occurs when bubbles form within the hair cortex due to high temperatures from styling with blow dryers or curling irons.<sup>2</sup> This leads to hair breakage and alterations in hair texture and manageability as seen in this representative case.<sup>3</sup> Hair dryers may cause this deformity when they overheat, especially when excess lint and hair are blocking the air intake of the hair dryer.<sup>4</sup> In a prior study, a temperature of 175–215 °C for 5 min was sufficient to create these bubbles; however, if the heat is applied to damp hair, the threshold could be even lower.<sup>1,5</sup> Treatment consists of avoidance of cutting or growing out the affected hair and then avoiding heat and using gentle hair care to prevent further formation of bubbles.

*TN clinical scenario: a young African-American woman presents with a several-month history of hair that does not grow long in the occipital scalp. She has styled her hair with regular permanents and recently started hair coloring as well. Although she has now stopped these hair care practices, her hair has not started to grow longer (Fig. 6a). Upon further questioning, she does brush and massage her scalp to help “stimulate” hair growth. A tug test on the affected hair yields multiple fragments of short hair. A hair mount of these short hairs confirms the diagnosis of TN (Fig. 6b).*

TN refers to a hair shaft fracture that resembles the two brooms or brushes in opposition. This hair fragility is thought to result from a combination of chemical, thermal and mechanical damage to the hair shaft, which then breaks easily with brushing. Because the “nodes” or fracture sites can form anywhere along the hair shaft, the hair will often be of various lengths and may have a dull appearance. Acquired TN is classified into proximal and distal types depending whether the breakage is proximal to the scalp, as seen in patients of African ancestry, or



**Figure 5** (a) Bubble hair. Focal area of unruly hair at the vertex. (b) A hair mount reveals bubbles within the hair shaft (40× magnification)



**Figure 6** (a) Trichorrhexis nodosa. Localized area of short hair – blunt ends with positive tug test. (b) Hair mount reveals brush-like ends in opposition (20× magnification)

near the distal ends of the hair, as seen in Caucasian and Asian patients.

Acquired TN can develop as a result of use of heat,<sup>6</sup> chemicals (hair dyes, permanents), and/or mechanical trauma from brushing or rubbing.<sup>7</sup> There is difficulty in defining “improper use” or “over-use” as different hair types will have a highly variable tolerance for weathering. Hair damage is usually noticed as a change in the quality of the hair or as “dry ends” or “hair that won’t grow” or “has stopped growing”. When this occurs, patients may cause more damage in their efforts to stimulate their hair to grow, for example, by brushing. Patients are advised to practice gentle hair care and to minimize physical and chemical trauma to the hair.<sup>8</sup> Full recovery may take 2–4 years.

### Congenital hair shaft disorders without increased fragility

#### Uncombable hair syndrome (UHS), pili annulati, pseudopili annulati, and woolly hair

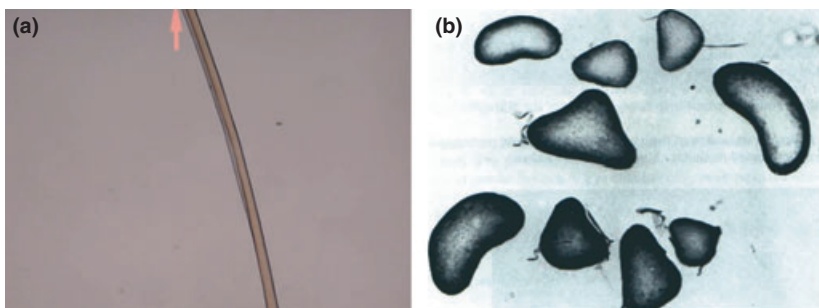
*UHS clinical scenario: a 4-year-old girl is brought in to the clinic by her parents for hair that is unmanageable and difficult to style. On exam, her hair is shoulder length, appears to stand away from the scalp, and has a frizzy appearance. There is no evidence of hair fragility on exam.*

UHS presents with characteristic unruly hair that is difficult to style and has the appearance of standing away from the scalp.<sup>9</sup> These changes are typically noted in

childhood, but acquired UHS has been reported.<sup>10</sup> UHS usually occurs without any other associations, although ocular, dental, or ectodermal defects<sup>11</sup> have been reported in the setting of UHS.<sup>12,13</sup> On light microscopic examination of mounted hair, the shaft may have a canal-like longitudinal groove along one or two facets; however, this finding is subtle and difficult to detect (Fig. 7a).<sup>9</sup> When hair cross-sections are examined (not an office procedure), the characteristic triangular or kidney-shaped appearance of the hair shaft is diagnostic (Fig. 7b). The irregular and changing shapes of the hair cross-section prevent adjacent hairs from lying flat or forming locks, and this accounts for the stand away appearance. To deal with this problem, the hair should be trimmed to reduce its volume, and the use of a silicone-based leave-in conditioner may aid in managing the hair. The etiology of this hair shaft disorder is unknown.

*Pili annulati clinical scenario: the patient usually has no hair complaints. The hair may be incidentally noted by an astute dermatologist to have a glittery or spangled appearance (Fig. 8a). The hair is not fragile and does not break.*

Pili annulati is a rare hair shaft disorder characterized by bright and dark bands when viewed with reflected light (Fig. 8b). This banded appearance is attractive and can affect the entire scalp, as well as the axillae, beard, and pubic areas.<sup>14,15</sup> There is no fragility, and the hair can grow long. The bright bands correspond to abnormal air-filled cavities within the hair cortex.<sup>16–18</sup> On a hair mount, these bright bands appear dark because



**Figure 7** Uncombable hair syndrome. (a) Hair mount reveals longitudinal groove along hair shaft (10× magnification; figure courtesy of Dr. Sarah Chamlin). (b) Cross-section of hair shaft reveals triangular or kidney bean-shaped formation (40× magnification)



**Figure 8** (a) Pili annulati. The hair has a shiny appearance. (b) A close-up of the hair shafts reveals a spangled appearance. (c) Dark and light bands on a hair mount (upper), and comparison to normal hair shaft (lower; 20× magnification)

transmitted light is not permitted to pass through (Fig. 8c). This differs from pseudopili annulati in which there are no air-filled cavities, and instead the banded appearance is an optical effect stemming from the partial twisting of the hair shaft in an oscillating manner.<sup>19</sup>

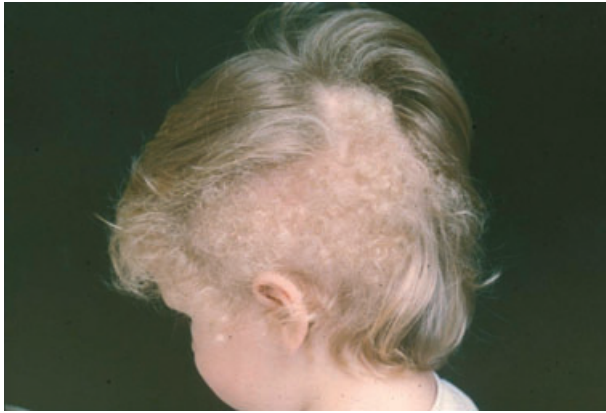Pili annulati is inherited in an autosomal dominant fashion. Initial theories that pili annulati was due to a keratin defect have not been borne out. Immunohistochemical studies of epithelial cytokeratins and linkage studies of keratin gene clusters among families with pili annulati have been found to be normal.<sup>19</sup> Recently, the gene for pili annulati has been localized to the telomeric region of chromosome 12q.<sup>20</sup> Candidate genes include regulatory proteins involved in the normal formation or degradation of the basement membrane zone of the lamina densa and sublamina densa layers of the hair follicle.<sup>14</sup>

*Woolly hair clinical scenario: a 3-year-old girl presents with fine, tightly curled hair that is very different in texture from the rest of the family. The hair does not exhibit breakage, and there are no notable changes on hair mount. Upon examination of the skin, keratoderma is noted on the soles. Based on the hair findings, the patient is referred for further specialty evaluation and testing.*

The term “woolly” stems from sheep’s wool; the cortex of wool fibers consists of two cell types, the orthocortex and paracortex, which have differing reactivity and expand unequally. This structural asymmetry causes the coiling and crimping of wool.<sup>21</sup> Human hair may also at times have a woolly appearance even though it consists

mainly of paracortex, and the explanation of the woolly appearance is incomplete. Woolly hair can involve the entire scalp<sup>22</sup> or just an isolated patch seen as a woolly hair nevus. Woolly hair can occur as an isolated finding or in association with various genetic syndromes.<sup>23,24</sup> These include palmar/plantar keratoderma,<sup>25</sup> keratosis pilaris atrophicans faciei,<sup>26</sup> Noonan’s syndrome,<sup>27</sup> Carvajal syndrome,<sup>28</sup> cardiofaciocutaneous syndrome,<sup>29</sup> and Naxos disease.<sup>24</sup> Woolly hair has also been described with cardiac defects<sup>30</sup> and keratosis follicularis spinulosa decalvans.<sup>31</sup> Thus, patients with woolly hair should have a full examination to evaluate for abnormalities, such as facial dysmorphism, cutaneous abnormalities, cardiac abnormalities, and other findings in order to investigate if it is part of a larger genetic syndrome.

Woolly hair nevus is characterized by a discrete area of tightly curled hair in an otherwise normal scalp, and it occurs sporadically (Fig. 9). The woolly hair can grow at a normal rate<sup>32</sup> or slower<sup>22</sup> than normal hair. Woolly hair nevus typically presents at birth or develops before 18 months of age.<sup>33</sup> In about half the reported cases, woolly hair nevus is associated with linear nevi. The pigmented or epidermal nevi are usually on the neck, arms, or trunk, and not on the scalp. In general, it is an isolated finding, but woolly hair nevus has been reported to occur with neurological defects, ocular abnormalities,<sup>34</sup> bone disorders, and other mesodermal defects.<sup>33</sup> Hair mount of woolly hair does not have any distinguishing findings.<sup>35</sup> No treatment has been shown to help this condition. If straightening the hair with chemicals or heat is



**Figure 9** Woolly hair nevus. A discrete patch of tightly curled hair that is distinctly different from the hair on the rest of the scalp

contemplated, care must be taken as this hair may be more fragile than normal. Woolly hair nevus might darken and become less curly with time.<sup>32,36</sup>

### **Congenital hair shaft disorders with increased fragility and breakage**

#### **Congenital TN, trichothiodystrophy (TTD), pili torti, trichorrhexis invaginata and monilethrix**

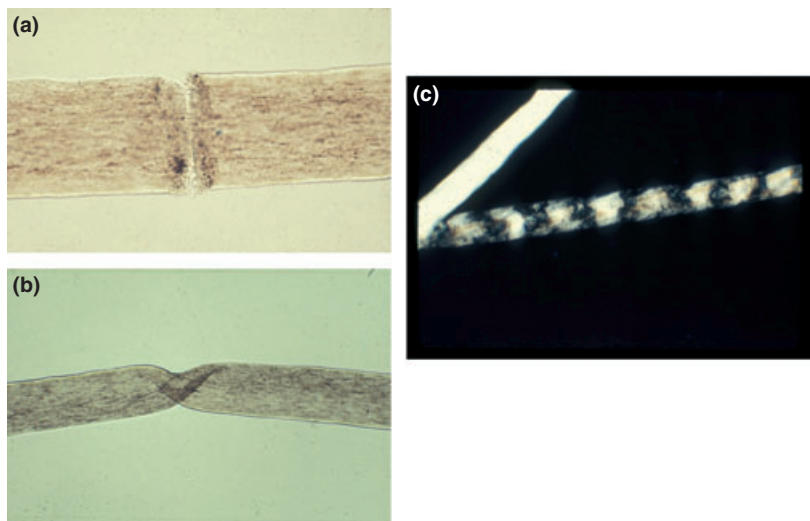
Congenital TN may occur as the sole clinical abnormality in a sporadic case, or in families, with the abnormal fragility of the hair becoming evident shortly after birth. There are no abnormal laboratory findings in these patients. More commonly, TN is noted as an incidental finding in patients with other hair shaft disorders associated with fragility, such as pili torti, monilethrix, or TTD.

Congenital TN in patients with arginosuccinic aciduria:<sup>7</sup> arginosuccinic aciduria is an inborn error of urea synthesis which can cause mental retardation. This rare syndrome is caused by a deficiency of the enzyme argininosuccinic lyase, and large amounts of argininosuccinic acid are found in the urine, blood, and cerebrospinal fluid. This abnormality is now tested for and diagnosed in infancy. If unrecognized, neonates present with failure to thrive that can lead to lethargy and coma.<sup>37</sup> The hair defect was historically an important diagnostic clue to this systemic disease.

*TTD clinical scenario:* a 5-year-old boy presents with his mother, who reports that whenever he has a fever and has to lie in bed for a few days, his hair breaks off from friction of his head lying on the pillow. Following a recent febrile episode, he comes in with short, uneven, broken hair. His mother also reports that he has always had dry skin and “does not do well” in the sun. The patient’s medical history includes mild mental and developmental impairment. A tug test is positive, indicating hair fragility. With polarizing microscopy (in the position of extinction or darkness) the hair has a banded or “tiger tail” appearance (Fig. 10c). The hair is sent for amino acid analysis.

TTD is a term that describes cystine-deficient brittle hair.<sup>38</sup> Hair is an important clinical marker for this rare inherited disorder with a wide variety of phenotypes: these phenotypes range from brittle hair only to a neuroectodermal symptom complex with severe intellectual and developmental impairment.

Diagnosis of TTD can be made by examination of the hair. The diagnosis is suspected with a hair mount and light microscopy, which shows hair shafts with an undulating, wavy outline rather than the usual straight outline.<sup>39</sup>



**Figure 10** Trichothiodystrophy. (a) Light microscopy reveals trichoschisis (40× magnification), and (b) ribboning (20× magnification). (c) Polarizing microscopy reveals tiger tail banding (20× magnification)

There may be trichoschisis fractures<sup>40</sup> (Fig. 10a), TN-like fractures, and ribboning, which describes the flattened hair shaft folded over itself like a ribbon<sup>41</sup> (Fig. 10b). Polarizing microscopy further supports the diagnosis, with hair shafts showing alternating bright and dark (tiger tail) bands,<sup>38</sup> in the position of darkness. Amino acid analysis of the hair confirms the diagnosis with a cystine content reduced to less than half of normal values. The wide variety of clinical phenotypes ranges from short, fragile hair alone to a variety of symptoms including, but not limited to, photosensitivity, ichthyosis, brittle hair, intellectual impairment, decreased fertility, and short stature. Neurological abnormalities, developmental delay, and immunodeficiency may also be present.

TTD is an autosomal recessive disorder, and mutations in three different genes have been implicated in its pathogenesis. These genes, XPD, XPB, and TTDA, are components of the transcription factor IIIH, a multiprotein complex that is involved in the nucleotide excision repair pathway.<sup>40</sup> Mutations in these genes are associated not only with TTD but also with the rare genetic diseases xeroderma pigmentosum and Cockayne syndrome.

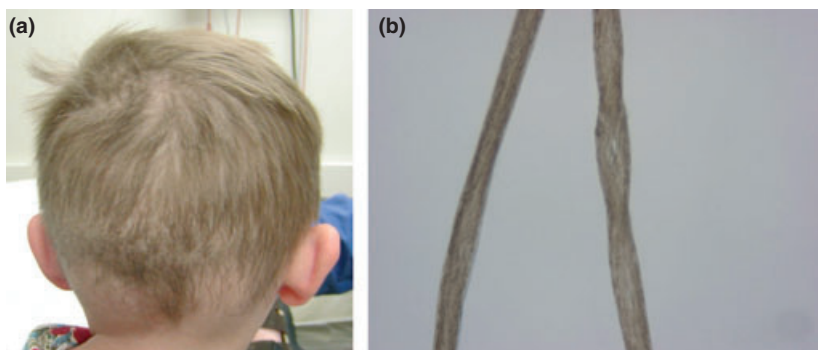
*Pili torti clinical scenario: a 4-year-old blond boy is brought to clinic by his parents for short hair that never requires a haircut. On exam, his hair is short, especially over the occipital scalp, and has a spangled appearance (Fig. 11a). A tug test is positive, and in a hair mount twisting is noted (Fig. 11b). He is otherwise healthy. It was subsequently determined that he had mild sensorineural hearing loss.*

Pili torti is characterized by hair that does not grow long and is easily broken; the hair often has a “spangled” appearance due to the unequal reflection of light from the twisted surface. Patchy hair breakage and coarse stubble are typically seen in the occiput and temporal areas due to friction. Pili torti can also involve the eyebrows and eyelashes. A diagnosis is made by light microscopic observation of flattened hair twisted at 180° along its axis and occurring in groups of 3–10. Sometimes this twisting can be difficult to visualize with a hair mount due to the

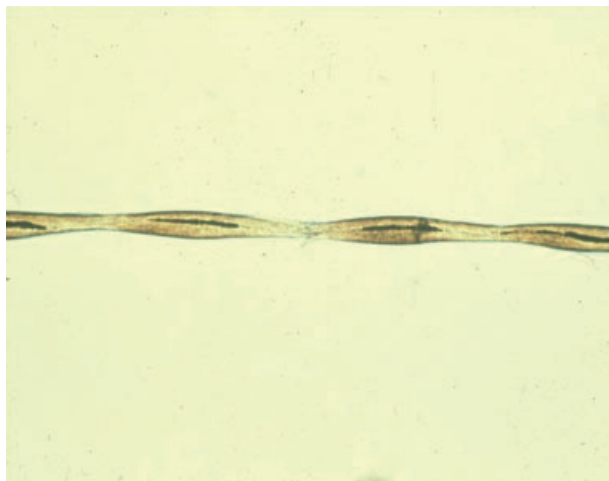
flattening of the hair; thus, if the diagnosis is suspected, the hair may be viewed by light microscopy without mounting media. Although pili torti may be seen in isolation, it is commonly associated with other congenital defects and therefore, if identified, further evaluation for possible neurological and ectodermal disorders is an important part of the clinical evaluation.<sup>42</sup> The twisting of the hair is likely due to irregularities in the inner root sheath, which may induce an uneven molding of the hair shaft.<sup>43</sup> New research suggests that these alterations may occur in the face of mitochondrial dysfunction, and may be influenced by the presence of reactive oxygen species.<sup>44</sup>

Björnstad syndrome is an autosomal recessive condition characterized by pili torti and bilateral congenital sensorineural hearing loss.<sup>45</sup> These features usually present before the second year of life,<sup>45</sup> and the severity of hair involvement correlates with the degree of hearing loss.<sup>45</sup> A mutation in the BCS1L gene on chromosome 2q34–36<sup>46</sup> disrupts the assembly of mitochondrial respirasomes in human mitochondria and leads to production of reactive oxygen species.<sup>44</sup> BCS1L had been previously reported to cause two pediatric syndromes with profound multisystem organ failure: complex III deficiency and the GRACILE syndrome.<sup>44</sup> However, the specific mutation in BCS1L that leads to the highly restricted pili torti and sensorineural hearing loss of Björnstad syndrome results in a much more mild functional disruption of mitochondria.<sup>44</sup> This seems to illustrate how ear and hair tissues are exquisitely sensitive to mitochondrial function, specifically to the production of reactive oxygen species.<sup>44</sup> The natural course is improvement of pili torti with age, especially after puberty.<sup>47–48</sup> Management of this syndrome is limited to genetic counseling, early identification, and treatment of the hearing loss with assisted hearing devices.

Menkes disease (MD) is a multisystemic lethal disorder due to impaired copper transport and metabolism with pili torti.<sup>49,50</sup> Patients have defective activity of copper-dependent enzymes leading to severe developmental and



**Figure 11** Björnstad syndrome; pili torti. (a) Short hair in the occipital scalp with a spangled appearance. (b) Hair mount reveals flattened and twisted hair on the long axis (20× magnification)



**Figure 12** Monilethrix. Hair mount reveals beaded nodes at regular intervals with absence of the central dark medulla in the areas of constriction (20x magnification)

neurological impairment, connective-tissue abnormalities, tortuous blood vessels, and hair changes.<sup>49</sup> After the

normal-appearing newborn hair is shed, patients develop stubby, coarse, sparse, and hypopigmented hair.<sup>51</sup> The hair has been described as “steel wool” as it is unruly and easily fractures with friction.<sup>51</sup> Severe neurological deterioration leads to a decerebrate, vegetative state.<sup>52</sup> MD is due to a mutation in the X-linked ATP7A gene, which encodes a copper-transporting ATPase.<sup>49,53-57</sup> It had been presumed that because normal copper transportation is essential to formation of disulfide bonds in hair keratin, defective keratin production was the cause of twisted hair. However, because impaired copper transport is also known to lead to reactive oxygen species and mitochondrial dysfunction, this may be the explanation for pili torti in MD as well.<sup>58</sup>

*Trichorrhexis invaginata clinical scenario: a 4-year-old girl presents for treatment of severe dermatitis and hair that does not grow long. On exam, the erythematous eruption consists of unusual serpiginous scaling lesions with a characteristic double-edged scale at the advancing borders. She has short hair, which is most notable in the occipital scalp; her brows are also sparse. A tug test of the scalp hair is positive and a hair mount reveals*

**Table 2** Hair shaft disorders with their inheritance pattern and characteristic hair mount findings

Hair shaft disorder	Inheritance	Hair mount
Acquired hair shaft disorder with increased fragility		
Bubble hair	–	Air bubbles within hair shaft
Trichorrhexis nodosa	–	Brush-like ends in opposition
Congenital hair shaft disorders without increased fragility		
Uncombable hair syndrome	AD or sporadic	Longitudinal grooves may be seen with hair mount without mounting medium. Triangular or kidney bean shape on cross-section (not an office procedure)
Pili annulati	AD	Alternating light and dark bands due to air cavities (seen with the naked eye by reflected light). In a hair mount, with transmitted light, air cavities appear dark when empty and clear when fluid-filled
Woolly hair	Sporadic or inherited	No characteristic findings
Congenital hair shaft disorders with increased fragility		
Trichorrhexis nodosa		
Arginosuccinic aciduria	AR	Brush-like ends in opposition
Trichothiodystrophy	AR	Clean fracture through the cortex and the cuticle (trichoschisis), ribboning, irregular outline of the hair shaft, trichorrhexis-nodosa-like fractures. Tiger tail: with polarizing microscopy (in position of darkness, crossed polarizers) see bright and dark alternating domains
Pili torti		
Björnstad	AR	Closely grouped twists, seen in hair mount without mounting medium
Menkes	X-linked recessive	Closely grouped twists, seen in hair mount without mounting medium
Trichorrhexis invaginata		
Netherton syndrome	AR	Bamboo-like invaginations
Monilethrix	AD or AR	Nodes alternating with constrictions. Nodes have a normal diameter hair with a medulla, whereas constrictions lack a medulla and may show evidence of fracture

AD, autosomal dominant; AR, autosomal recessive.



*trichorrhexis invaginata, leading to a diagnosis of Nether-ton syndrome (NS).*

NS is characterized by the triad of trichorrhexis invaginata, ichthyosis linearis circumflexa, and an atopic diathesis.<sup>59</sup> Patients are born with a dry, scaly erythroderma, which is considered a variant of ichthyosis, either a form of lamellar ichthyosis or congenital ichthyosiform erythroderma.<sup>60</sup> Neonatal dehydration, failure to thrive, and recurrent infections may also be present.<sup>61</sup> Ichthyosis linearis circumflexa consists of migratory, erythematous, polycyclic, serpiginous lesions with a characteristic double-edged scale at the advancing borders.<sup>62</sup> An atopic diathesis may include eczema-like eruptions, atopic dermatitis, asthma, pruritus, allergic rhinitis, angioedema, urticaria, elevated serum IgE, and/or hypereosinophilia.<sup>61</sup> All hair is affected, but it is often easier to find the characteristic invaginations that resemble bamboo in eyebrow or limb hair.<sup>63</sup> On a hair mount, the intussusceptions that resemble the ball-and-cup joints of bamboo joints are easily seen; the cup portion of the defect is proximal, and the ball portion is distal.<sup>64</sup> Hair shafts show various degrees of change from minimal wrinkling, twisting of the shaft, to well-formed invaginations.

NS is an autosomal recessive disorder due to a genetic mutation of the SPINK5 gene, which is on chromosome 5q31-32, and encodes a serine protease inhibitor LETKI.<sup>65,66</sup> LEKTI contributes to the balance of serine proteases/inhibitors in the skin, and influences skin barrier function and desquamation in the epidermis.<sup>67</sup> Although the role of serine proteases in the hair follicle is not fully described, enzyme activity has been demonstrated at sites of keratinization, such as the inner root sheath and the uppermost follicle.<sup>68</sup> Thus, SPINK5 mutations may affect the integrity of the hair shaft as it is forming as opposed to being caused by keratin defects.

There is no specific treatment for trichorrhexis invaginata, but the hair often improves with age and can resolve with time.<sup>61</sup> Treatment for NS is aimed at improving the dermatitis and barrier dysfunction with emollients.

*Monilethrix clinical scenario: a 5-year-old boy presents with short, stubbly hair that does not grow beyond 1-2 cm. The patient is otherwise healthy. A tug test is positive and a hair mount reveals a beaded appearance to the hair.*

Monilethrix is a distinctive rare hair shaft disorder named after the resemblance of the affected hair to a string of beads. The beaded appearance of the hair can be visualized by the naked eye, or with a dermatoscope, as alternating wide and constricted segments along the hair shaft. The hair breaks spontaneously or as a result of friction. A hair mount shows the distinctive “nodes”, or wide segments, which have the diameter of normal hair and are medullated; these alternate with the “internodes”

or constrictions that have no medulla and are the sites of fracture<sup>69</sup> (Fig. 12). The scalp is the main site affected, but hair all over the body may be affected.<sup>70-72</sup> Keratosis pilaris is always associated with monilethrix and is commonly on the upper back and shoulders. Other ectodermal features may include koilonychia, brittle nails, syndactyly, juvenile cataracts, decreased visual fields, and dental lesions.<sup>72</sup>

Monilethrix is an autosomal dominant keratin mutation of the type II basic hair keratins hHb1 and hHb6 on chromosome 12q13, which leads to alterations in the hair cortex.<sup>70,71,73-76</sup> An autosomal recessive variant has been described due to desmoglein 4 mutation.<sup>77,78</sup> Desmoglein 4 is a transmembrane cell adhesion molecule expressed in the hair cortex and upper cuticle, which is also associated with localized autosomal recessive hypotrichosis.<sup>75</sup> In this variant, affected hair of the scalp, chest, arms, and legs has perifollicular papules caused by ingrown hairs.<sup>79</sup>

Monilethrix may improve with puberty, with pregnancy or with oral contraceptives, but usually it persists in some degree into adulthood. There is no known treatment. Patients are advised to protect the fragile hair from excessive combing, styling, or friction.

## Conclusions

Patients with hair shaft disorders should be examined with a methodical approach (Fig. 4; Table 2). One should suspect a hair shaft disorder if a patient presents with an abnormality or change in texture, quality, or breakage of one's hair. After taking a full history, performing an exam, and examining the hair mount, the hair should be categorized as “without increased fragility” or “with increased fragility”. With proper examination techniques and a systematic approach, hair shaft disorders can be satisfying to evaluate and diagnose.

## Questions

### A practical, algorithmic approach to diagnosing hair shaft disorders questions

(See answers on page 12)

1. What is the best way to assess for hair fragility?
  - a. Pull test.
  - b. Polarizing microscopy.
  - c. Tug test.
  - d. Hair mount.
2. Which of the following regarding monilethrix is true?
  - a. Ichthyosis linearis circumflexa is an associated finding.
  - b. The sulfur content of the hair is low.
  - c. The mutation involves hHb1 and hHb6, which encode hair keratins.

- d. Patients do not have increased hair fragility.
3. Which of the following hair shaft disorders will demonstrate increased fragility on tug test?
  - a. Pili annulati.
  - b. Woolly hair.
  - c. Uncombable hair syndrome.
  - d. Monilethrix.
4. Which of the following hair shaft disorders tend to be found in isolation without other significant medical problems?
  - a. Trichorrhhexis invaginata.
  - b. Pili torti.
  - c. Bubble hair.
  - d. Trichothiodystrophy.
5. Which of the following can be associated with sensorineural hearing loss?
  - a. Björnstad syndrome.
  - b. Bubble hair.
  - c. Netherton syndrome.
  - d. Uncombable hair syndrome.
6. Which of the following is false regarding trichothiodystrophy?
  - a. It is caused by a mutation in nucleotide excision repair.
  - b. Light microscopy reveals light and dark bands.
  - c. There are characteristic alternating light and dark bands on polarizing microscopy.
  - d. Amino acid analysis of the hair demonstrates low sulfur content.
7. Which of the following hair shaft disorders can result from heat injury caused by a hair dryer?
  - a. Bubble hair.
  - b. Trichorrhhexis invaginata.
  - c. Pili torti.
  - d. Trichothiodystrophy.
8. Which of the following hair shaft disorders is characterized by a triangular hair shaft on cross-section?
  - a. Uncombable hair syndrome.
  - b. Trichothiodystrophy.
  - c. Pili annulati.
  - d. Trichorrhhexis nodosa.
9. Which of the following is false regarding woolly hair?
  - a. In Naxos disease, it is associated with non-epidermolytic palmoplantar keratoderma and cardiomyopathy.
  - b. In Carvajal syndrome, it is associated with epidermolytic palmoplantar keratoderma and left ventricular cardiomyopathy.
  - c. Woolly hair nevus is often associated with other medical problems.
  - d. Often presents in infancy.
10. Which of the following hair shaft disorders is due to air-filled cavities in the cortex of the hair shaft?

- a. Pili annulati.
- b. Pseudopili annulati.
- c. Trichothiodystrophy.
- d. Monilethrix.

## References

- 1 Mirmirani P. What is your diagnosis? Bubble hair. *Cutis* 2008; 82: 176.
- 2 Krasnoff J, Glusac E, Bologna JL. Bubble hair – a possible explanation for its distribution. *Int J Dermatol* 1998; 37: 380–382.
- 3 Brown VM, Crouse RG, Abele DC. An unusual new hair shaft abnormality: “bubble hair”. *J Am Acad Dermatol* 1986; 15: 1113–1117.
- 4 Detwiler SP, Carson JL, Woosley JT, et al. Bubble hair. Case caused by an overheating hair dryer and reproducibility in normal hair with heat. *J Am Acad Dermatol* 1994; 30: 54–60.
- 5 Gummer CL. Bubble hair: a cosmetic abnormality caused by brief, focal heating of damp hair fibres. *Br J Dermatol* 1994; 131: 901–903.
- 6 Mirmirani P. Ceramic flat irons: improper use leading to acquired trichorrhhexis nodosa. *J Am Acad Dermatol* 2010; 62: 145–147.
- 7 Rogers M. Hair shaft abnormalities: Part I. *Australas J Dermatol* 1995; 36: 179–184.
- 8 Fichtel JC, Richards JA, Davis LS. Trichorrhhexis nodosa secondary to argininosuccinic aciduria. *Pediatr Dermatol* 2007; 24: 25–27.
- 9 Ravella A, Pujol RM, Noguera X, de Moragas JM. Localized pili canaliculi and trianguli. *J Am Acad Dermatol* 1987; 17: 377–380.
- 10 Kuhn CA, Helm TN, Bergfeld WF, McMahon JT. Acquired uncombable hair. *Arch Dermatol* 1993; 129: 1061–1062.
- 11 Shelley WB, Shelley ED. Uncombable hair syndrome: observations on response to biotin and occurrence in siblings with ectodermal dysplasia. *J Am Acad Dermatol* 1985; 13: 97–102.
- 12 Schena D, Germi L, Zamperetti MR, et al. Uncombable hair syndrome, mental retardation, single palmar crease and arched palate in a patient with neurofibromatosis type I. *Pediatr Dermatol* 2007; 24: E73–E75.
- 13 Jarell AD, Hall MA, Sperling LC. Uncombable hair syndrome. *Pediatr Dermatol* 2007; 24: 436–438.
- 14 Giehl KA, Ferguson DJ, Dean D, et al. Alterations in the basement membrane zone in pili annulati hair follicles as demonstrated by electron microscopy and immunohistochemistry. *Br J Dermatol* 2004; 150: 722–727.
- 15 Cady L. A study of ringed hair. *Arch Derm Syph* 1922; 6: 301–317.
- 16 Giehl KA, Ferguson DJ, Dawber RP, et al. Update on detection, morphology and fragility in pili annulati in three kindreds. *J Eur Acad Dermatol Venereol* 2004; 18: 654–658.

- 17 Price VH, Thomas RS, Jones FT. Pili annulati. Optical and electron microscopic studies. *Arch Dermatol* 1968; 98: 640-647.
- 18 Gummer CL, Dawber RP. Pili annulati: electron histochemical studies on affected hairs. *Br J Dermatol* 1981; 105: 303-309.
- 19 Giehl KA, Dean D, Dawber RP, et al. Cytokeratin expression in pili annulati hair follicles. *Clin Exp Dermatol* 2005; 30: 426-428.
- 20 Green J, Fitzpatrick E, de Berker D, et al. A gene for pili annulati maps to the telomeric region of chromosome 12q. *J Invest Dermatol* 2004; 123: 1070-1072.
- 21 Lantis SD, Pepper MC. Woolly hair nevus. Two case reports and a discussion of unruly hair forms. *Arch Dermatol* 1978; 114: 233-238.
- 22 Ormerod AD, Main RA, Ryder ML, Gregory DW. A family with diffuse partial woolly hair. *Br J Dermatol* 1987; 116: 401-405.
- 23 Tursten U, Kaya TI, Ikingoglu G, et al. Genetic syndrome with ichthyosis: congenital ichthyosis, follicular atrophoderma, hypotrichosis, and woolly hair; second report. *Br J Dermatol* 2002; 147: 604-606.
- 24 Chien AJ, Valentine MC, Sybert VP. Hereditary woolly hair and keratosis pilaris. *J Am Acad Dermatol* 2006; 54: S35-S39.
- 25 Tosti A, Misciali C, Piraccini BA, et al. Woolly hair, palmoplantar keratoderma, and cardiac abnormalities: report of a family. *Arch Dermatol* 1994; 130: 522-524.
- 26 McHenry PM, Nevin NC, Bingham EA. The association of keratosis pilaris atrophicans with hereditary woolly hair. *Pediatr Dermatol* 1990; 7: 202-204.
- 27 Neild VS, Pegum JS, Wells RS. The association of keratosis pilaris atrophicans and woolly hair, with and without Noonan's syndrome. *Br J Dermatol* 1984; 110: 357-362.
- 28 Carvajal-Huerta L. Epidermolytic palmoplantar keratoderma with woolly hair and dilated cardiomyopathy. *J Am Acad Dermatol* 1998; 39: 418-421.
- 29 Roberts A, Allanson J, Jadico SK, et al. The cardiofaciocutaneous syndrome. *J Med Genet* 2006; 43: 833-842.
- 30 Zandi S, Farajzadeh S. A new cardiac manifestation associated with woolly hair: report of two cases of woolly hair, palmoplantar keratoderma, and mitral valve regurgitation. *Int J Dermatol* 2007; 46: 952-954.
- 31 Lacarrubba F, Dall'Oglio F, Rossi A, et al. Familial keratosis follicularis spinulosa decalvans associated with woolly hair. *Int J Dermatol* 2007; 46: 840-843.
- 32 Kumaran S, Dogra S, Handa S, Kanwar AJ. Woolly hair nevus. *Pediatr Dermatol* 2004; 21: 609-610.
- 33 Goldin HM, Bronson DM, Fretzin DF. Woolly-hair nevus: a case report and study by scanning electron microscopy. *Pediatr Dermatol* 1984; 2: 41-44.
- 34 Taylor AE. Hereditary woolly hair with ocular involvement. *Br J Dermatol* 1990; 123: 523-525.
- 35 Mortimer PS. Unruly hair. *Br J Dermatol* 1985; 113: 467-473.
- 36 Amichai B, Grunwald MH, Halevy S. A child with a localized hair abnormality. Woolly hair nevus. *Arch Dermatol* 1996; 132: 573-574.
- 37 Urea Cycle Disorders Conference group. Consensus statement from a conference for the management of patients with urea cycle disorders. *J Pediatr* 2001; 138: S1-S5.
- 38 Price VH, Odom RB, Ward WH, Jones FT. Trichothiodystrophy: sulfur-deficient brittle hair as a marker for a neuroectodermal symptom complex. *Arch Dermatol* 1980; 116: 1375-1384.
- 39 Sperling LC, DiGiovanna JJ. "Curly" wood and tiger tails: an explanation for light and dark banding with polarization in trichothiodystrophy. *Arch Dermatol* 2003; 139: 1189-1192.
- 40 Itin PH, Sarasin A, Pittelkow MR. Trichothiodystrophy: update on the sulfur-deficient brittle hair syndromes. *J Am Acad Dermatol* 2001; 44: 891-920; quiz 921-924.
- 41 Liang C, Morris A, Schlucker S, et al. Structural and molecular hair abnormalities in trichothiodystrophy. *J Invest Dermatol* 2006; 126: 2210-2216.
- 42 Richards KA, Mancini AJ. Three members of a family with pili torti and sensorineural hearing loss: the Bjornstad syndrome. *J Am Acad Dermatol* 2002; 46: 301-303.
- 43 Maruyama T, Toyoda M, Kanei A, Morohashi M. Pathogenesis in pili torti: morphological study. *J Dermatol Sci* 1994; 7(Suppl): S5-S12.
- 44 Hinson JT, Fantin VR, Schonberger J, et al. Missense mutations in the BCS1L gene as a cause of the Bjornstad syndrome. *N Engl J Med* 2007; 356: 809-819.
- 45 Robinson GC, Johnston MM. Pili torti and sensory neural hearing loss. *J Pediatr* 1967; 70: 621-623.
- 46 Lubianca NJ, Lu L, Eavey RD, et al. The Bjornstad syndrome (sensorineural hearing loss and pili torti) disease gene maps to chromosome 2q34-36. *Am J Hum Genet* 1998; 62: 1107-1112.
- 47 Loche F, Bayle-Lebey P, Carriere JP, et al. Pili torti with congenital deafness (Bjornstad syndrome): a case report. *Pediatr Dermatol* 1999; 16: 220-221.
- 48 Telfer NR, Cutler TP, Dawber RP. The natural history of 'dystrophic' pili torti. *Br J Dermatol* 1989; 120: 323-325.
- 49 Moller LB, Mogensen M, Horn N. Molecular diagnosis of Menkes disease: genotype-phenotype correlation. *Biochimie* 2009; 91: 1273-1277.
- 50 Menkes JH, Alter M, Steigleder GK, et al. A sex-linked recessive disorder with retardation of growth, peculiar hair, and focal cerebral and cerebellar degeneration. *Pediatrics* 1962; 29: 764-779.
- 51 Hart DB. Menkes' syndrome: an updated review. *J Am Acad Dermatol* 1983; 9: 145-152.
- 52 Maddox JL Jr, Odom RB, Goette DK. Menkes's syndrome. *Pediatr Dermatol* 1984; 1: 307-311.
- 53 Tang J, Donsante A, Desai V, et al. Clinical outcomes in Menkes disease patients with a copper-responsive

- ATP7A mutation, G727R. *Mol Genet Metab* 2008; **95**: 174–181.
- 54 Park HD, Moon HK, Lee J, *et al*. A novel ATP7A gross deletion mutation in a Korean patient with Menkes disease. *Ann Clin Lab Sci* 2009; **39**: 188–191.
- 55 Bertini I, Rosato A. Menkes disease. *Cell Mol Life Sci* 2008; **65**: 89–91.
- 56 de BP, Muller P, Wijmenga C, Klomp LW. Molecular pathogenesis of Wilson and Menkes disease: correlation of mutations with molecular defects and disease phenotypes. *J Med Genet* 2007; **44**: 673–688.
- 57 Ambrosini L, Mercer JF. Defective copper-induced trafficking and localization of the Menkes protein in patients with mild and copper-treated classical Menkes disease. *Hum Mol Genet* 1999; **8**: 1547–1555.
- 58 Mirmirani P, Samimi SS, Mostow E. Pili torti: clinical findings, associated disorders, and new insights into mechanisms of hair twisting. *Cutis* 2009; **84**: 143–147.
- 59 Greene SL, Muller SA. Netherton's syndrome. Report of a case and review of the literature. *J Am Acad Dermatol* 1985; **13**: 329–337.
- 60 Pruszkowski A, Bodemer C, Fraitag S, *et al*. Neonatal and infantile erythrodermas: a retrospective study of 51 patients. *Arch Dermatol* 2000; **136**: 875–880.
- 61 Sun JD, Linden KG. Netherton syndrome: a case report and review of the literature. *Int J Dermatol* 2006; **45**: 693–697.
- 62 Altman J, Stroud J. Netherton's disease and ichthyosis linearis circumflexa. *Arch Dermatol* 1969; **100**: 248–249.
- 63 Powell J, Dawber RP, Ferguson DJ, Griffiths WA. Netherton's syndrome: increased likelihood of diagnosis by examining eyebrow hairs. *Br J Dermatol* 1999; **141**: 544–546.
- 64 Netherton EW. A unique case of trichorrhhexis nodosa; bamboo hairs. *AMA Arch Derm* 1958; **78**: 483–487.
- 65 Chavanas S, Bodemer C, RoCHAT A, *et al*. Mutations in SPINK5, encoding a serine protease inhibitor, cause Netherton syndrome. *Nat Genet* 2000; **25**: 141–142.
- 66 Chavanas S, Garner C, Bodemer C, *et al*. Localization of the Netherton syndrome gene to chromosome 5q32, by linkage analysis and homozygosity mapping. *Am J Hum Genet* 2000; **66**: 914–921.
- 67 Ong C, O'Toole EA, Ghali L, *et al*. LEKTI demonstrable by immunohistochemistry of the skin: a potential diagnostic skin test for Netherton syndrome. *Br J Dermatol* 2004; **151**: 1253–1257.
- 68 Bitoun E, Micheloni A, Lamant L, *et al*. LEKTI proteolytic processing in human primary keratinocytes, tissue distribution and defective expression in Netherton syndrome. *Hum Mol Genet* 2003; **12**: 2417–2430.
- 69 Bentley-Phillips B, Bayles MA. A previously undescribed hereditary hair anomaly (pseudo-monilethrix). *Br J Dermatol* 1973; **89**: 159–167.
- 70 Winter H, Clark RD, Tarras-Wahlberg C, *et al*. Monilethrix: a novel mutation (Glu402Lys) in the helix termination motif and the first causative mutation (Asn114Asp) in the helix initiation motif of the type II hair keratin hHb6. *J Invest Dermatol* 1999; **113**: 263–266.
- 71 Summerly R, Donaldson EM. Monilethrix: a family study. *Br J Dermatol* 1962; **74**: 387–391.
- 72 Karıncaoglu Y, Coskun BK, Seyhan ME, Bayram N. Monilethrix: improvement with acitretin. *Am J Clin Dermatol* 2005; **6**: 407–410.
- 73 Healy E, Holmes SC, Belgaid CE, *et al*. A gene for monilethrix is closely linked to the type II keratin gene cluster at 12q13. *Hum Mol Genet* 1995; **4**: 2399–2402.
- 74 Birch-Machin MA, Healy E, Turner R, *et al*. Mapping of monilethrix to the type II keratin gene cluster at chromosome 12q13 in three new families, including one with variable expressivity. *Br J Dermatol* 1997; **137**: 339–343.
- 75 Schweizer J, Langbein L, Rogers MA, Winter H. Hair follicle-specific keratins and their diseases. *Exp Cell Res* 2007; **313**: 2010–2020.
- 76 Winter H, Labreze C, Chapalain V, *et al*. A variable monilethrix phenotype associated with a novel mutation, Glu402Lys, in the helix termination motif of the type II hair keratin hHb1. *J Invest Dermatol* 1998; **111**: 169–172.
- 77 Schaffer JV, Bazzi H, Vitebsky A, *et al*. Mutations in the desmoglein 4 gene underlie localized autosomal recessive hypotrichosis with monilethrix hairs and congenital scalp erosions. *J Invest Dermatol* 2006; **126**: 1286–1291.
- 78 Zlotogorski A, Marek D, Horev L, *et al*. An autosomal recessive form of monilethrix is caused by mutations in DSG4: clinical overlap with localized autosomal recessive hypotrichosis. *J Invest Dermatol* 2006; **126**: 1292–1296.
- 79 Shimomura Y, Sakamoto F, Kariya N, *et al*. Mutations in the desmoglein 4 gene are associated with monilethrix-like congenital hypotrichosis. *J Invest Dermatol* 2006; **126**: 1281–1285.

## Answers

1. c
2. c
3. d
4. c
5. a
6. b
7. a
8. a
9. c
10. a