

Postprocessing Approaches for the Improvement of Cardiac Ultrasound B-Mode Images: A Review

Antonios Perperidis

Abstract—The improvement in the quality and diagnostic value of ultrasound images has been an ongoing research theme for the last three decades. Cardiac ultrasound suffers from a wide range of artifacts such as acoustic noise, shadowing, and enhancement. Most artifacts are a consequence of the interaction of the transmitted ultrasound signals with anatomic structures of the examined body. Structures such as bone, lungs (air), and fat have a direct limiting effect on the quality of the acquired images. Furthermore, physical phenomena such as speckle introduce a granular pattern on the imaged tissue structures that can sometimes obscure fine anatomic detail. Over the years, numerous studies have attempted to address a range of artifacts in medical ultrasound, including cardiac ultrasound B-mode images. This review provides extensive coverage of such attempts identifying their limitations as well as future research opportunities.

Index Terms—Cardiac ultrasound, compounding, contrast enhancement, echocardiography, image enhancement, image filtering, noise suppression, review.

I. INTRODUCTION

ECHOCARDIOGRAPHY provides a versatile, real-time diagnostic tool with no adverse secondary effects, capable of acquiring images of high spatial and temporal resolution at relatively low operational cost [1]. The wide range of available imaging techniques makes cardiac ultrasound a prevalent tool for the qualitative and quantitative assessment of cardiac morphology and function in both 2-D and 3-D. Cardiac ultrasound images can be acquired 1) through the thorax of the patient, also known as transthoracic echocardiography (TTE), or 2) from inside the esophagus of the patient (by utilizing specialized acquisition probes), also known as transesophageal echocardiography (TEE) [2]. TEE can generate high-quality images. However, the extended acquisition time and personnel requirements along with patient discomfort currently limit its clinical use, making TTE the common approach in clinical examinations. However, transthoracic cardiac ultrasound images are often incomplete (partial heart coverage) and suffer from a range of artifacts as a consequence of the interaction of the transmitted ultrasound signals with anatomic structures of the examined body. Structures such as bone, lungs (air), and fat have a direct limiting effect on the quality and diagnostic value of the acquired cardiac images. Furthermore, transthoracic

cardiac ultrasound images a constantly and rapidly moving structure through the patient's rib cage. The nature of such a challenging acquisition enhances the manifestation of common medical ultrasound artifacts (Fig. 1).

Cardiac ultrasound images suffer from acoustic noise due to a range of acoustical phenomena (artifacts) such as reverberations, side-lobes, and grating-lobes [1], [2]. The extent of each artifact on the imaged cardiac structures depends on both the acquisition technology utilized as well as the echogenicity of the patient. For example, modern phased-array transducers minimize the effect of grating-lobes by using an adequately small pitch (less than half the wavelength of the transmitted signal) between the elements of the array. On the other hand, the effect of side-lobes, especially when transmitted in out-of-scan-plane directions, is mostly related to the proximity of extra-cardiac structures such as the lung and rib-cage bones. Furthermore, many instruments, especially phased array transducers, suffer from near-field clutter or ring-down effect [2]. Near-field clutter manifests itself at the top part of the scan as a zone with a high level of stationary noise that gradually declines to zero for increasing scanning depth [2]. Finally, oblique incidence angles of the transmitted ultrasound beam with respect to an imaged structure may result in low contrast between the cardiac tissue and chamber. A high-gain setting, possibly in an attempt to compensate for the low tissue signal, may result in additional amplifier noise mostly present in cardiac chambers. While not an exhaustive list, the aforementioned artifacts corrupt the imaged cardiac structures and from an imaging perspective can be considered as noise.

Imaging of relatively small and rapidly moving structures such as the cardiac valves introduces additional challenges. Besides the limited delineation as a result of noise, the structure may move into and out of the scan plane due to the cardiac and respiratory motion. Furthermore, reverberations and shadowing appear due to the interaction of the transmitted ultrasound with high reflective and attenuating structures, such as the patient's rib cage and lungs that lie in the path of the ultrasound beam. Such artifacts may appear momentarily or alter their position and orientation throughout a scan due to small movements of the transducer combined with the patient's respiration motion, obscuring the imaging of portions of the examined cardiac structure [1], [2].

Speckle is a type of acoustic phenomenon responsible for the granular appearance of ultrasound images. Speckle is a result of constructive and destructive interference of echoes produced by scattering of ultrasound at random, small-scale, tissue inhomogeneities. Speckle is a direct consequence of 1) the stochastic nature of the reflectivity of scattering media, and 2) the coherent

Manuscript received November 13, 2015; accepted January 31, 2016. Date of publication February 8, 2016; date of current version March 11, 2016. This work was supported by the Engineering and Physical Sciences Research Council (EPSRC) through the "Biologically Inspired Acoustic Systems" under Grant EP/C523776/1.

The author was with the Unit of Medical Physics and Medical Engineering, University of Edinburgh, Edinburgh EH16 4TJ, U.K. He is now with the Institute of Signals Sensors and Systems, Heriot Watt University, Edinburgh EH14 4AS, U.K. (e-mail: A.Perperidis@hw.ac.uk).

Digital Object Identifier 10.1109/TUFFC.2016.2526670

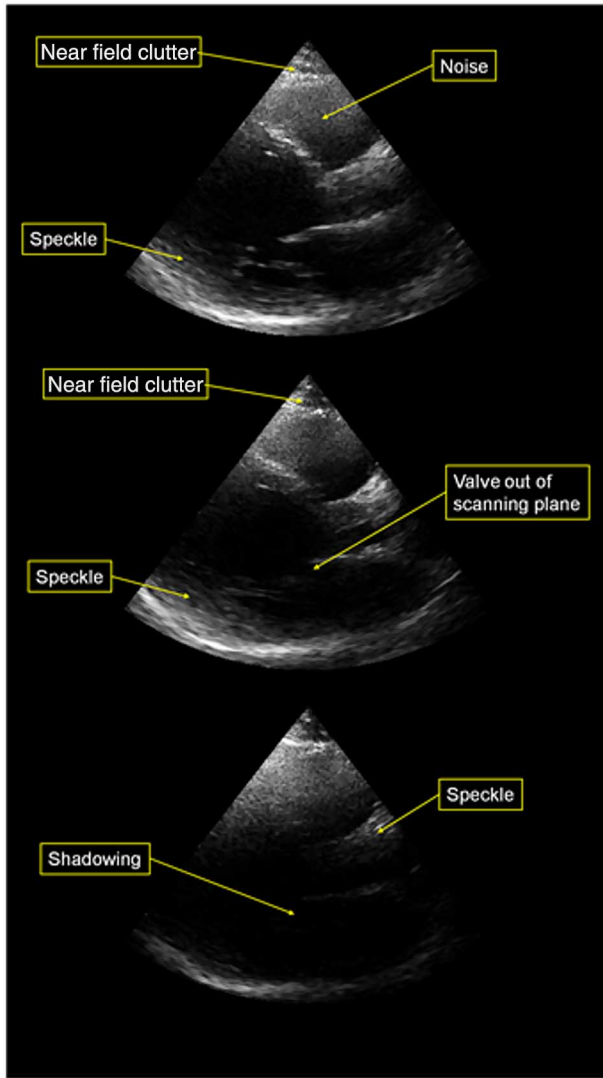


Fig. 1. Examples of corrupted cardiac ultrasound data: near-field noise, clutter, shadowing, speckle, and structures moving out of the scanning plane.

nature of the piezoelectric transducer. Several studies provide detailed information on the origin of speckle and its statistical properties [3]–[5]. The granular pattern of speckle can sometimes be considered as an undesirable property since it may obscure fine anatomic detail. In cardiac ultrasound images, tissue speckle combined with high levels of chamber noise can limit the delineation of cardiac structures. Furthermore, the granular appearance of the images limits the application of postformation processing techniques such as image registration and segmentation. Therefore, means for suppressing noise and speckle can possibly improve the image quality and diagnostic value of a cardiac ultrasound dataset. On the other hand, speckle motion may be utilized in tissue velocity and strain estimation methods such as speckle tracking echocardiography (STE) [6] and radio frequency (RF)-based strain imaging [7]. Both techniques assess global and regional cardiac function by tracking the movement of speckle patterns over time. They provide a promising alternative to 1) tagged cardiac MRI for assessing left ventricular deformation and torsion [8], and 2) color Doppler for strain imaging, addressing problems

associated with angle dependence [7]. Detailed descriptions on the principles of STE as well as current and future clinical applications are provided in [6], [9]–[12]. Similarly, more information on RF-based strain imaging is provided in [7], [13]–[17]. Image processing methods that enhance the intensity dynamic range (contrast) within speckle may improve the accuracy and robustness of such existing techniques that tackle speckle motion.

Over the last three decades, a number of advances in data acquisition have substantially improved cardiac ultrasound image quality. Nevertheless, a considerable portion of current cardiac ultrasound images demonstrate low image quality and limited diagnostic value. In 2008, a systematic study was performed on routine patients going through the echocardiography department of the Western General Hospital (Edinburgh). The results of the study have been used for educational purposes in the department and have not been published yet. The study, performed using both older and the state-of-the-art cardiac ultrasound systems, demonstrated that about 33% of the datasets are of high (clear cardiac structures, enabling reliable clinical measurements), 33% are of average (partially corrupted cardiac structures, limiting the accuracy and precision of clinical measurements), and 33% are of low (highly corrupted cardiac structures, limiting and many times prohibiting clinical measurements) image quality and diagnostic value. While the state-of-the-art ultrasound system improved the quality of the acquired data, the findings were heavily dependent on the echogenicity of the patients. Furthermore, a number of postformation image processing techniques such as image registration, image segmentation, data classification, and texture analysis have been introduced for cardiac data acquired using modalities such as CT and MRI [18]–[20]. These techniques enable the development of tools and protocols that enhance the accuracy, robustness, and repeatability of the diagnostic process. Over the last few years, similar postprocessing techniques have been attempted on cardiac ultrasound images [21]–[24]. Recent advances in real-time 3-D echocardiography (RT3DE) extend the potential application of such techniques [25], [26]. However, while postformation image processing techniques may work on high quality images, high levels of noise, low contrast, speckle, and shadowing limit their effectiveness in a considerable proportion of clinical cardiac ultrasound datasets. The development of effective postprocessing methods that enhance the quality and diagnostic value of cardiac ultrasound images is, therefore, desirable. Postprocessing techniques do not require hardware modifications and can be applied to both existing and new data. This study attempts to provide a thorough review of such image-enhancement postprocessing techniques for cardiac ultrasound images.

II. SPECKLE AND NOISE SUPPRESSION TECHNIQUES

Noise and speckle suppression has been of active research interest for more than 20 years. Ultrasound, and, to a greater extent, cardiac ultrasound scans represent a very difficult and demanding application area for noise suppression algorithms. The main challenge lies in the fact that while cardiac ultrasound images may suffer from high noise and low contrast levels,

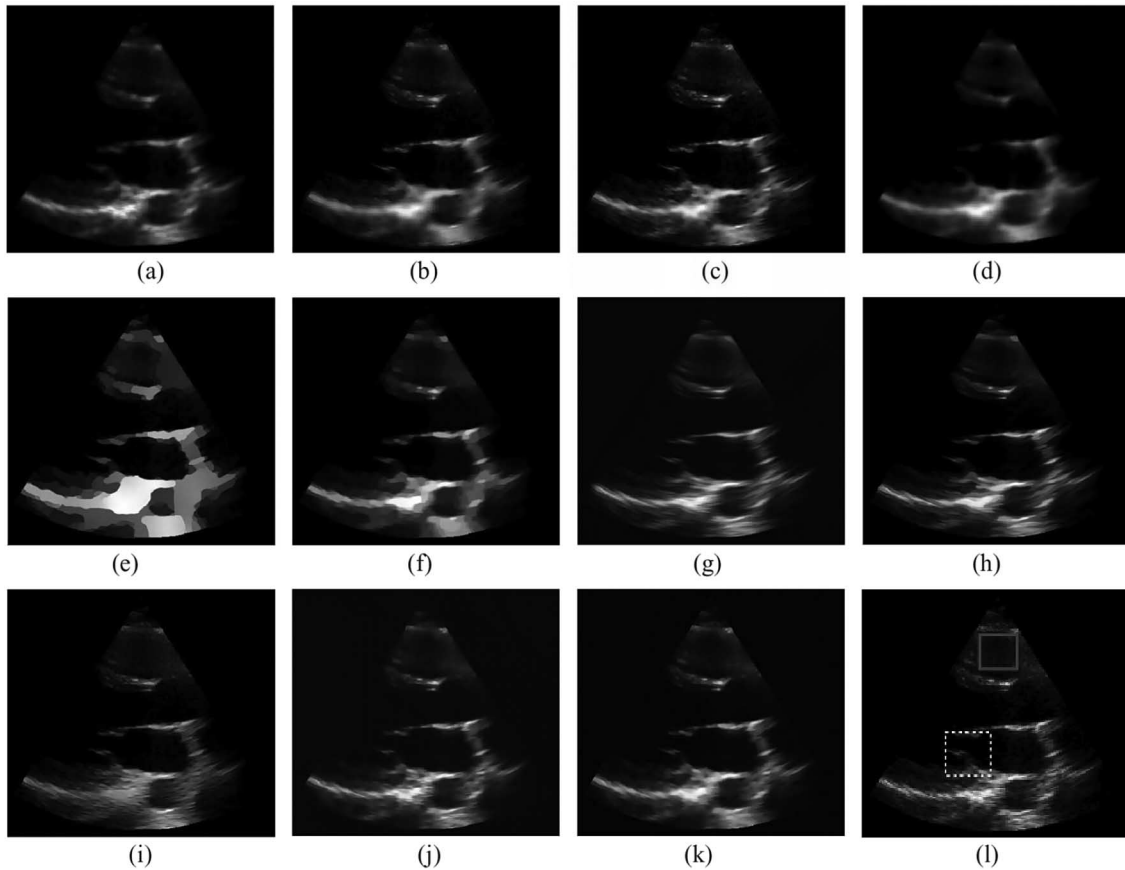


Fig. 2. Effect of a range of filtering techniques on a log-compressed frame from a clinical transthoracic parasternal long-axis echocardiographic video. Adaptive local statistics filters: (a) Lee *et al.* [32], (b) Kuan *et al.* [34], and (c) Frost *et al.* [33], [35]. Anisotropic diffusion filters: (d) Perona and Malik diffusion (PAMD) [58]. (e) SRAD [59], (f) detail preserving anisotropic diffusion (DPAD) [60], (g) nonlinear coherent diffusion (NCD) [61], and (h) OSRAD [62]. Wavelet filters: (i) Zong *et al.* [53], (j) generalized likelihood method (GML) [48], and (k) NMWD filter [63], integrating wavelet transforms with anisotropic diffusion. (l) Original, unprocessed frame with the RV and mitral-valve regions highlighted (used in the original study for CNR estimation). The figure has been adapted with relevant permission from [64].

they also contain a variety of spatial features that should be preserved during processing. Such features include interfaces between structures represented with a different grayscale level, e.g., cardiac tissue/chamber boundaries, as well as relatively small structures, e.g., rapidly moving cardiac valves. Over the years, a number of approaches for suppressing speckle and noise have been introduced. Such approaches can be broadly categorized into image filtering and compounding techniques. Their effectiveness on enhancing image quality varies greatly.

A. Filtering

A range of postprocessing filters have been developed for suppressing speckle and noise in medical ultrasound images. From a very early stage, it was identified [27], [28] that nonadaptive filters, such as mean and median, were inadequate for enhancing medical ultrasound images since they introduced severe blurring on the edges of anatomic structures and consequently loss of valuable diagnostic information. Due to the limitations of commonly used nonadaptive filters, the development of effective noise and speckle suppression filters for medical ultrasound images evolved into a field of major research interest. While a diverse range of noise suppression

filters have been developed over the years [29], [30], most filters can be broadly categorized as: 1) adaptive local statistics; 2) wavelet domain; or 3) anisotropic diffusion filters. Fig. 2 provides some representative examples from all the three aforementioned filter categories on cardiac ultrasound data. A recent study by Biradar *et al.* [31] provided quantitative comparison of 48 denoising filters covering approaches beyond the scope of the present study, including Fourier, nonlocal means, fuzzy, total variation, and other hybrid filters. The study provides a very good resource to a wider range of filtering/despeckling approaches.

1) *Adaptive Filters:* Adaptive local statistics filters have long been used for the suppression of noise and speckle in medical ultrasound images. Such filters utilize statistical information derived from a region-of-interest (ROI) within the processed image, and adapt the parameters of the filter applied to this ROI accordingly. Adaptable parameters include weighting, size, and shape of the filter, among others. Adaptive local statistics filters were initially applied on synthetic aperture radar (SAR) data that also suffered from high levels of noise and speckle [32]–[35] [Fig. 2(a)–(c)]. Jin *et al.* [36] provided a qualitative and quantitative assessment on the performance of popular SAR filters on medical ultrasound images. Thereafter,

a number of adaptive filters have been developed for suppressing noise and speckle in medical ultrasound images [27], [28], [37]–[39]. Massay *et al.* [40] in an early attempt to enhance the quality of cardiac ultrasound images utilized the adaptive filtering approach first introduced by Bamber and Daft [27]. The filter identified regions containing speckle based on *a priori* knowledge of speckle statistics. Regions resembling fully developed speckle were then heavily smoothed by a low-pass (local mean) filter. The approach suppressed speckle considerably in both phantom and clinical cardiac ultrasound images. However, while intended to preserve the underlying cardiac structure, the filter degraded the diagnostic value of the clinical cardiac images by increasing the perceived dimensions of cardiac chambers. Nillesen *et al.* [25] examined the effect of two adaptive filters and one nonadaptive filter on pediatric cardiac ultrasound images. Both adaptive filters were based on the approach by Bamber and Daft [27] using local mean and mean-squares, respectively, to smooth regions recognized as homogeneous. The nonadaptive filter utilized the local entropy [41]–[43] (measure of information) within a sliding kernel to smooth homogeneous regions while enhancing tissue/chamber edges. All three filters were found to be valuable preprocessing steps to automatic tissue/chamber segmentation, reducing speckle and enhancing the detectability between cardiac tissue and chambers. Both adaptive filters outperformed the non-adaptive approach with the choice of adaptive filter be of no importance.

2) *Wavelet Filters:* Recently, there has been an increased interest in utilizing wavelet transforms as a tool for suppressing noise within medical ultrasound images. Wavelet filters attempt to remove noise while preserving the boundaries of anatomic structures. Filters in the wavelet domain consist of three main steps [44]. 1) The original image is decomposed using a wavelet transform. 2) The wavelet coefficients are modified in order to generate the desired noise suppression. 3) The enhanced image is reconstructed from the modified wavelet coefficients using an inverse wavelet transform. Wavelets provide an attractive domain for noise suppression in medical ultrasound images due to inherent properties such as: 1) simplicity, multiscale decomposition that simplifies the statistics of complex signals; 2) multiresolution, image features are analyzed at an appropriate resolution scale; and 3) edge detection, large wavelet coefficients coincide with image edges [45]. A range of noise and speckle suppression filters for medical ultrasound images operating in the wavelet domain have been investigated [44]–[51] [Fig. 2(j)]. In an early study, Kang *et al.* [52] identified the potential of wavelet filters in enhancing cardiac ultrasound images by suppressing noise while preserving cardiac tissue/chamber edges. The suggested approach was based on the assumption that edges demonstrate large signal on a sequence of wavelet scales as opposed to noise and speckle that are manifested on a limited number of wavelet scales. The direct multiplication of wavelet data at adjacent scales was, therefore, used to distinguish “important” edges from noise and consequently accomplish the desirable noise suppression. The approach was validated on a very limited number (five) of single-frame 2-D cardiac ultrasound images outperforming the basic, nonadaptive Wiener filter in the enhancement of the

processed data. Zong *et al.* [53] introduced an algorithm that suppressed noise using multiscale wavelet analysis [54] while enhancing cardiac structures using adaptive gain nonlinear processing [55]. A discreet dyadic wavelet transform (DWT) [56] was employed throughout the multiscale wavelet analysis in order to reduce undesirable artifacts, such as pseudo-Gibbs phenomena. The algorithm was thoroughly evaluated both qualitatively and quantitatively using 60 clinical datasets and input from 2 expert observers. Compared to nonadaptive, adaptive, and wavelet denoising-only filters, Zong *et al.*'s [53] approach suppressed noise while enhancing the edges between cardiac tissues and chambers considerably [Fig. 2(i)]. The enhancement of the cardiac ultrasound images improved the consistency and reliability of manually defined borders by expert observers, especially for data of low image quality. Hao *et al.* [57] combined adaptive filtering with wavelet domain techniques for the effective suppression of cardiac ultrasound speckle. More precisely, the adaptive weighted mean filter [28] was utilized to generate an image containing the signal and an image containing the noise of the original data. Both images were then individually processed using wavelet filters. The final, noise-reduced image was obtained by summing the two filtered images. The algorithm was evaluated on cardiac images from a pig outperforming the individual adaptive [28] and wavelet filters [46] in noise suppression and edge preservation. However, the assessment was very limited with no results on human cardiac images being presented.

3) *Anisotropic Diffusion Filters:* Similar to filters in the wavelet domain, anisotropic diffusion filters aim toward the suppression of noise while preserving boundaries between anatomic structures. Diffusion is known as the process that equilibrates concentration differences by distributing particles from areas with high to areas with low concentration [65]. During diffusion, a set of filtered images are iteratively generated until a sufficient level of noise suppression is achieved. The image diffusion, and consequently the noise suppression, is controlled by a partial differential equation. Within the partial differential equation, a diffusion coefficient is utilized in order to identify edges within the image and encourage noise suppression within homogeneous regions instead of across edges. The diffusion coefficient can be a constant scalar value, a process known as isotropic diffusion, or a tensor that is a function of the differential structure of the evolving image, a process known as anisotropic diffusion [65]. Anisotropic diffusion is required in order to suppress noise while maintaining edges within an image. This process has been referred to as intra-structure smoothing as distinct from inter-structure smoothing [66]. Anisotropic diffusion filters were introduced by Perona and Malik [58] [Fig. 2(d)]. Over the last decade, a wide range of such filters for the suppression of speckle and noise in medical ultrasound images have been developed [59], [60], [62], [67], [68] [Fig. 2(e), (f), and (h)]. A method for noise reduction and feature enhancement of cardiac ultrasound images using anisotropic diffusion was presented by Abd-Elmoniem *et al.* [61] [Fig. 2(g)]. For a robust and optimal speckle suppression and anatomic feature enhancement, the proposed model changed progressively from isotropic linear diffusion, through anisotropic diffusion to finally mean

curvature motion according to the extent of speckle and image anisotropy. Processing the raw scan lines along with a special discretization scheme improved the processing requirements of the technique, potentially enabling its real-time implementation on commercial systems. The noise suppression and feature preservation properties of the algorithm were assessed using phantom, cardiac, liver, and kidney images that exhibit a range of structural information. When compared with adaptive [28] and wavelet [53] filters, the proposed anisotropic diffusion algorithm appeared to best smooth speckle while preserving anatomic structures. However, the assessment was performed on a limited number of datasets (1 of each type) and based only on qualitative observations. Yue *et al.* [63] combined wavelet transforms along with anisotropic diffusion for the suppression of noise and enhancement of anatomic features within cardiac ultrasound images [Fig. 2(k)]. More precisely, the original image was decomposed into multiscale wavelet coefficients, which then individually underwent anisotropic diffusion. The idea was to benefit from the multiresolution property of wavelets as well as the edge preservation property of anisotropic diffusion, introducing a more effective, integrated image-enhancement method. The evaluation of the method, while very limited (1 clinical dataset), demonstrated potential to outperform the individual wavelet [46] and diffusion filters [59] in noise suppression and edge enhancement of cardiac ultrasound images. More recently, Gu *et al.* [69] employed the normalized modulus of the image's wavelet coefficients at different scales as a robust edge detector instead of a gradient (differential) operator. The approach was quantitatively and qualitatively assessed using simulated and *in vivo* cardiac ultrasound images, respectively. In both cases, the proposed approach outperformed other popular despeckling methods [30], [59], [63] in noise suppression and edge preservation. However, similar to other diffusion filters [61], [63] applied in cardiac ultrasound data, the assessment was of a very limited extent (1 *in vivo* dataset). A more extensive assessment is necessary for more solid conclusions with regards to the performance of each filter to be made.

4) *Comparing Filtering Techniques:* A recent study by Finn *et al.* [64] provided a thorough quantitative evaluation and comparison among 15 popular noise and speckle suppression filters on a range of simulated and clinical cardiac ultrasound images. A range of early local statistics adaptive filters [32]–[34], wavelet domain filters [48], [53], [63], and anisotropic diffusion filters [58]–[60], [62], [65] were evaluated. Fig. 2 provides a characteristic example of the effect of these filters on clinical cardiac ultrasound data. Hundred clinical cardiac ultrasound scans from forty patients were utilized in order to assess the effect of each filtering algorithm on five quantitative image quality metrics: 1) Pratt's figure of merit [70], measuring the displacement of edge pixels between the original and each filtered image; 2) structural similarity [71], assessing the preservation of structural information (cardiac structure); 3) edge region mean square error (MSE), assessing the average absolute difference between the extracted edges in the original and filtered images; 4) contrast-to-noise ratio (CNR), assessing the effect of each filtering method on the contrast between cardiac chambers and tissue structures; and

5) signal-to-noise ratio (SNR), assessing the levels of noise and speckle in the original and filtered images. The quantitative metrics were chosen in order to assess the effect of filters on noise suppression, contrast enhancement, and feature and edge preservation. Moreover, the study was very comprehensive making some valuable comparisons among popular noise suppression filters. From the findings, anisotropic diffusion filters performed better on simulated data. However, the results were more diverse for clinical cardiac ultrasound images, the quality of which was affected by a wider range of artifacts. The most satisfactory noise suppression and feature preservation was achieved by the oriented speckle reduction anisotropic diffusion (OSRAD) filter developed by Krissian *et al.* [62] [Fig. 2(h)], and the nonlinear multiscale wavelet diffusion (NMWD) filter [63] [Fig. 2(k)], integrating wavelet transforms with anisotropic diffusion. Both filters performed well in the quantitative assessment as well as the visual inspection of the processed images. Furthermore, both OSRAD and NMWD achieved some of the highest increases in CNR between cardiac tissue and chambers in both the simulated and the clinical data. A large variability in the effects of the examined filters on the CNR between clinical and simulated data was observed. On simulated data, more than 60% of examined filters demonstrate reduction (compared to a reference image) in CNR, while on clinical images, all filters demonstrated improvement in CNR. As a result, the findings on the effect of the examined filters on CNR were inconclusive demonstrating the scope for further research in cardiac tissue/chamber contrast-enhancement approaches. Nevertheless, in general, anisotropic diffusion filters followed by wavelet filters performed the best in cardiac image enhancement. In addition, while diffusion and wavelet filters tend to be more computationally intensive than adaptive filters, diffusion filters seem to provide the best tradeoff between performance and computational requirements, potentially making them better filtering candidates for clinical cardiac ultrasound images [31].

5) *Limitations of Filtering Techniques:* Postprocessing image filters for noise and speckle suppression suffer from a number of inherent limitations. Such limitations include the sensitivity to the size and shape of the filter window and sometimes to a required threshold value. In most cases, such filter parameters are determined empirically. Inappropriate choice may result in ineffective filtering. Moreover, some filters focus on speckle reduction making assumptions on the nature of the noise adopting a multiplicative model [59], [60], [62], [68]. However, acoustic noise in cardiac ultrasound images originates from a range of acoustical phenomena. Furthermore, the multiplicative model does not take into account the logarithmic compression commonly applied to RF ultrasound data to reduce its dynamic range for displaying. Other approaches compensate for this logarithmic compression converting to an additive noise model with a Gaussian, or Rayleigh probability density function (pdf) [44], [45], [47], [49]. However, as demonstrated by Kaplan and Ma [72], the log-compression of a Rayleigh-distributed signal (multiplicative noise) results in a Fisher–Tippett pdf. These assumptions of the noise model can, therefore, be considered restrictive and sometimes erroneous. Furthermore, while many filters claim to enhance contrast and anatomic structure edges, what they actually do is contrast

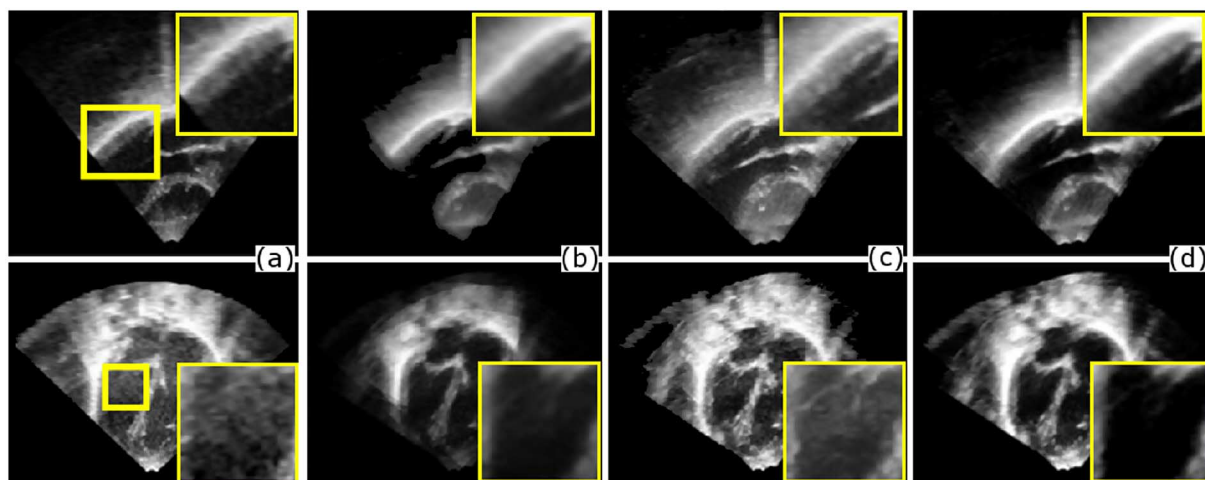


Fig. 3. Two-dimensional slices from two example datasets of (a) original unprocessed images, and compounded images using different compounding methods such as (b) mean, (c) maximum, and (d) weighted mean based on a local feature coherence/consistency as described in [89]. The figure has been reproduced with relevant permission from [89].

and edge preservation by withholding noise suppression along tissue/chamber edges. Finally, postprocessing filtering techniques do not address artifacts such as shadowing and reverberations that are commonly observed in cardiac ultrasound images. The presence of such artifacts may result in loss of clinically valuable information throughout the filtering process. Consequently, there is still a lot of scope in the research and development of alternative methods for enhancing the quality and diagnostic value of cardiac ultrasound images.

B. Compounding

Compounding techniques involve the fusion of multiple independent or partially decorrelated images of an anatomic structure obtained by varying one or more system parameters during data acquisition. Compounding techniques have been used for the suppression of speckle in medical ultrasound data for about three decades. The success of compounding techniques depends heavily on the statistical independence (decorrelation) among the speckle patterns of the source data. Burckhardt [4] demonstrated that if N independent ultrasound images are fused, then the SNR of the compound image will be increased by a factor of \sqrt{N} . Over the years, a number of data fusion strategies have been attempted including minimum, maximum, median, root mean square (rms), and various forms of weighted averaging. Fig. 3 provides examples of different intensity fusion approaches in 3-D cardiac ultrasound data. Currently, intensity averaging is the most commonly used image fusion strategy.

Spatial and frequency compounding are two commonly used compounding approaches. Early studies reported the potential of spatial compounding in speckle and noise suppression of medical ultrasound images [73]–[75]. Spatial compounding involves the fusion of independent images whose speckle patterns have been modified (decorrelated) by imaging the target ROI from varying angles. The variation in the imaging angle can be achieved by electronically steering the direction of the transmitted ultrasound signals or by repositioning the ultrasound transducer along the scanning plane. Through electronic

signal steering, the acquisition of real-time compounded images is feasible. However, electronic steering reduces the temporal resolution of the acquired images. Repositioning the transducer provides greater flexibility in the level of independence (decorrelation) as well as the number of the independent views of the imaged anatomic structure. However, reliable data alignment is required for the effective compounding of images acquired through transducer repositioning. Furthermore, the data acquisition time requirements are increased. In order to be able to achieve optimal spatial compounding, a number of studies have attempted to determine the correlation of speckle patterns as a function of aperture translation [4], [76], [77]. Frequency compounding involves the averaging of images whose speckle patterns have been modified (decorrelated) by a change in the spectrum of the transmitted or received acoustical pulse [78]–[81]. Frequency compounding has been reported to reduce speckle contrast and enhance structure boundaries in medical ultrasound images. However, Trahey *et al.* [80] observed that due to a resulting loss of resolution, frequency compounding is counterproductive in improving image quantity. Trahey *et al.* [82] combined frequency and spatial compounding in an attempt to compensate for this loss of resolution, providing a more effective noise and speckle suppression technique.

1) *Spatial Compounding of 3-D Cardiac Ultrasound Images:* Spatial compounding addresses many of the artifacts limiting the quality and diagnostic value of cardiac ultrasound images, making it an inherently more suitable noise and speckle suppression approach than postprocessing filters. However, the constant rapid movement of the heart, the constant respiration motion of the patient’s chest, and the limited acoustic windows between the rib cage and lungs introduce a number of limitations and challenges for spatial compounding methods. A number of studies have attempted to address these challenges in spatial compounding through transducer repositioning, enhancing cardiac ultrasound images. Soler *et al.* [83] performed spatial compounding of two cardiac volumes acquired from different apical acoustic windows. The 3-D volumes were spatially aligned without the use of external positioning sensors.

The registration approach was performed in two steps; an initial coarse alignment of two semiautomatically segmented left ventricle (LV) volumes was followed by a refined rigid registration of the volumetric data. Grau and Noble [84] introduced a method for compounding manually aligned apical and parasternal views of 3-D cardiac images. The compounding was based on image phase, and was implemented using the monogenic signal [85]. Grau and Noble [84] argued that image phase provides contrast invariant information on local structure definition and orientation. Considering the low contrast in many cardiac ultrasound images, image phase may provide a robust information resource. Yao and Penney [86] extended the previous attempts by aligning and compounding up to 11 parasternal and apical 3-D volumes. A combination of optical position sensors and rigid registration was utilized for the accurate alignment of the volumes. Traditional approaches such as intensity maximum and average, along with phase-based compounding, were also investigated. Rajpoot *et al.* [87] developed the first approach utilizing a fully automatic, multiresolution, voxel-based rigid registration for the alignment of multiple apical 3-D volumes. A novel wavelet-based spatial compounding method was also introduced enabling the decomposition and relevant fusion of the aligned volumes in low- and high-frequency components. Yao *et al.* [88], [89] used a combination of optical tracking followed by phased-based registration similar to [90] to align the 3-D cardiac volumes. Weighted averaging based on local feature coherence/consistency was employed for optimized image feature preservation during spatial compounding (Fig. 3). Gao *et al.* [91] performed a phantom-based feasibility study on the real-time compounding of transesophageal cardiac ultrasound volumes. An electromagnetic position sensor was utilized for the spatial alignment of the images. Another recent study investigated the effect of spatial compounding of multiple 3-D volumes on fetal cardiac ultrasound data [92]. The effect of a range of compounding approaches was examined including intensity maximum, mean, median as well as wavelet-based compounding. The physiology of a fetal heart, small size, and high heart rate, along with the absence of standard imaging windows in fetal cardiology, introduced additional challenges in effective spatial compounding. Szmigielski *et al.* [93] performed a thorough qualitative and quantitative assessment on the effect of spatial compounding of 3-D cardiac ultrasound images using phantom as well as clinical data from 32 participants. A rigid, fully automatic, voxel-based registration was utilized for the spatial alignment of the cardiac volumes. Finally, most of the aforementioned studies aligned and compounded frames from a single temporal phase of the cardiac cycle, usually consisting of end-diastole (ED) and/or end-systole (ES) frames. Mulder *et al.* [94], [95] compared the alignment results of employing single or multiple frame-pairs for the alignment of cardiac frame sequences. Linear temporal characteristics were assumed between ED and ES cardiac phases. Since, temporally corresponding frame pairs were matched, rigid spatial registration using normalized cross correlation (NXC) and mutual information (MI) was employed. The proposed algorithm was applied for the alignment of the LV and right ventricle (RV) volumes from 28 healthy volunteers, indicating that multiframe registration using NXC yield improved

results when compared to single frame registration. However, the assumption of linear temporal characteristics can be considered a bit restrictive leaving scope for the improvement on the alignment and compounding of multiple 3-D volumes.

The aforementioned studies have identified the potential of spatial compounding in improving the quality and diagnostic value of 3-D cardiac ultrasound images. Substantial noise and speckle reduction, field of view increase, reducing angle dependencies, acoustic shadowing and reverberation compensation, and enhancement of the presence of visually weak cardiac structures are commonly identified benefits of spatial compounding of cardiac volumes. The choice of spatial compounding approach has a direct effect on the processed images. The intensity averaging (mean or median) methods tend to generate a higher level of noise and speckle suppression. Techniques like maximum intensity compounding enhance anatomic feature delineation [92]. More advanced approaches such as phase- and wavelet-based compounding provide a tradeoff between noise suppression and feature delineation [92]. Some techniques like maximum intensity, deconvolution, phase-based, and wavelet compounding have been identified to introduce a modest tissue/chamber contrast increase [83], [86], [87].

Spatial compounding can introduce blurring across the boundaries of the imaged anatomic structures [75], [76], [96]. Blurring across structure boundaries can arise from a wide range of sources including: 1) uncertainties in transducer position; 2) uncertainties in the velocity of moving tissue structures; 3) errors in the assumed mean speed of sound; 4) spatial variations in the speed of sound; and 5) tissue movement during the sequential data acquisition. The accurate spatio-temporal alignment of the fused 3-D volumes is a key process for effective spatial compounding. Accurate alignment of all individual views of the imaged structure prior to spatial compounding can limit and possibly eliminate blurring across structure boundaries. Insufficient alignment may result in considerable degradation of the diagnostic value of the processed images. Most current approaches utilize fully automated, voxel-based rigid spatial registration of the compounded volumes. While nonrigid spatial registration could provide a more accurate alignment, its potential is currently limited due to the high levels of noise and low contrast of the aligned datasets. Moreover, nonlinear image transformation may result in undesired deformation of the cardiac physiology and is, therefore, not advisable. Currently, no study has attempted to address the temporal variability between consecutive cardiac cycles. This constitutes a major limitation in existing studies, which assume a regular cardiac cycle for the compounded volumes. This assumption is very restrictive and may cause severe deformation of cardiac structures affecting the diagnostic value of the processed images. Overall, throughout the years, there has been a substantial improvement in image alignment methods. It is expected that future studies will address most current limitations making the compounding of partially decorrelated 3-D volumes of the heart a very powerful image-enhancement tool. Nonetheless, possible physical barriers to multiview 3-D image acquisition due to extended acquisition and restricted acoustic windows through the patient's rib cage may limit its applicability.

2) *Spatial Compounding of 2-D Cardiac Ultrasound Images*: The acquisition of independent cardiac views using 2-D ultrasound is more challenging than the corresponding 3-D image acquisition. For effective spatial compounding 1) all images need to be acquired over the same or a very similar scan plane and 2) a substantial overlap between the individual heart views is required. Consequently, acquiring 2-D images suitable for effective spatial compounding through different acoustic windows (in a manner similar to 3-D volumes) is very ambitious and possibly not feasible with current acquisition and tracking technology. A number of studies have attempted to overcome this limitation by spatially compounding partially decorrelated 2-D images of the heart acquired along the temporal domain through a single acoustic window. The studies can be broadly categorized as: 1) compounding of temporally adjacent frames and 2) compounding frames corresponding to the same cardiac phase acquired over consecutive cardiac cycles. All of the proposed approaches can be extended to 4-D cardiac ultrasound volumes.

An early study by Petrovic *et al.* [97] enhanced cardiac ultrasound images by averaging the intensity levels from three consecutive frames. Due to the constant motion of the heart, the consecutive frames were partially decorrelated and consequently spatial compounding reduced noise and speckle in the processed images. However, averaging consecutive frames of a constantly and rapidly moving structure, such as the heart, introduced a considerable amount of blurring on the boundaries of cardiac tissue and chamber. Furthermore, averaging three frames to generate a single frame substantially reduced the temporal resolution of the processed dataset. A very similar approach was used to enhance intravascular ultrasound images by Li *et al.* [98]. Achmad *et al.* [99] attempted to address both limitations of the compounding method introduced by Petrovic *et al.* [97]. More precisely, for each frame in the B-mode frame sequence, a moving window was defined containing the preceding and the following frames (three frames). Optical flow [100] was utilized to derive an intermediate frame between the preceding and the following frame, which was then compounded with the current frame. By performing spatial compounding for each individual frame in the original B-mode frame sequence utilizing a moving window, no loss of temporal resolution was introduced. Moreover, by generating a partially decorrelated intermediate frame to compound with each frame in the sequence, no severe tissue/chamber boundary blurring was introduced. However, the noise suppression introduced by averaging two frames was very limited. Similar approaches have been adopted as a preprocessing step to image segmentation by dos Reis *et al.* [101], [102]. Lin *et al.* [103] extended further the compounding of temporally adjacent frames by utilizing a hierarchical, motion-compensating technique to spatially align (warp) up to nine frames. Qualitative and quantitative assessment demonstrated considerable noise reduction and enhancement of anatomic structures. However, the technique relied heavily on the accurate nonlinear registration of consecutive cardiac ultrasound frames. Currently, the applicability of nonlinear image registration methods is limited for a large proportion of cardiac ultrasound scans due to high levels of noise and low contrast. Consequently, the applicability

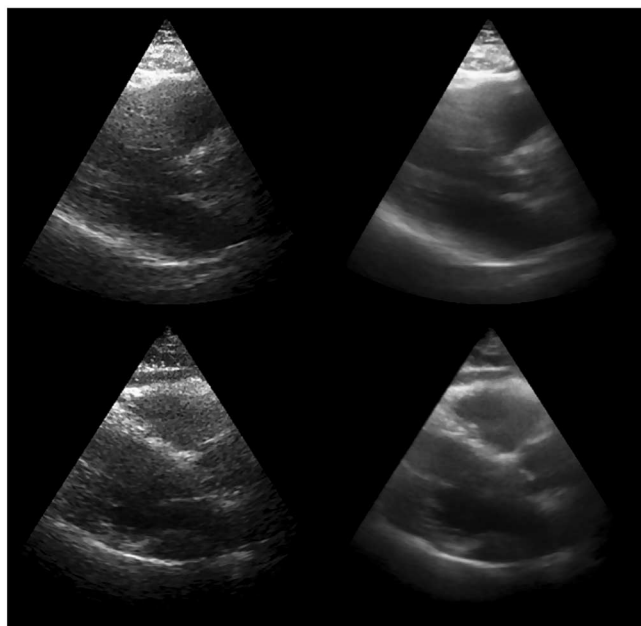


Fig. 4. Original (left) and compound (right) parasternal long axis ED frames of low image quality and diagnostic value. The images are generated using the temporal compounding approach as described in [105] and [112]. Compounding suppresses tissue speckle and chamber noise substantially. Data remain of low diagnostic value but some structures such as the IVS and RV (top), and the IVS, RV, LVPW, and aortic valve (bottom) marginally enhanced enabling their delineation. The figure has been reproduced with relevant permission from [112].

of this noise reduction method is limited to cardiac ultrasound images with low levels of noise.

Another set of studies attempted to utilize the repeated rhythmic contractions of the heart in order to acquire multiple 2-D images of the same cardiac phase over consecutive cardiac cycles. The process has been referred to as temporal compounding [104]. Minor random movements during a multicycle image acquisition alter the scan plane resulting in the acquisition of partially decorrelated views of the imaged cardiac structure. Spatially compounding such partially decorrelated frames corresponding to the same cardiac phase acquired over consecutive cardiac cycles can, therefore, enhance the processed images. Accurate and robust temporal and spatial alignments of corresponding frames acquired over multiple cardiac cycles are essential processes for effective temporal compounding. Insufficient spatio-temporal alignment may result in severe blurring of the imaged cardiac structure. Figs. 4 and 5 [105] provide representative examples of the effect of temporal compounding on cardiac ultrasound images over a range of image qualities and diagnostic values.

van Ocken *et al.* [106] first identified the potential of fusing information acquired over consecutive cardiac cycles in order to enhance the quality of the ultrasound datasets [107]. Unser *et al.* [108] performed averaging on a normalized time scale of M-mode ultrasound data acquired over a number of consecutive cardiac cycles. The temporal alignment to a reference cardiac cycle was performed using a dynamic programming time-wrapping algorithm requiring no ECG information. The compounding method enhanced the M-mode cardiac ultrasound

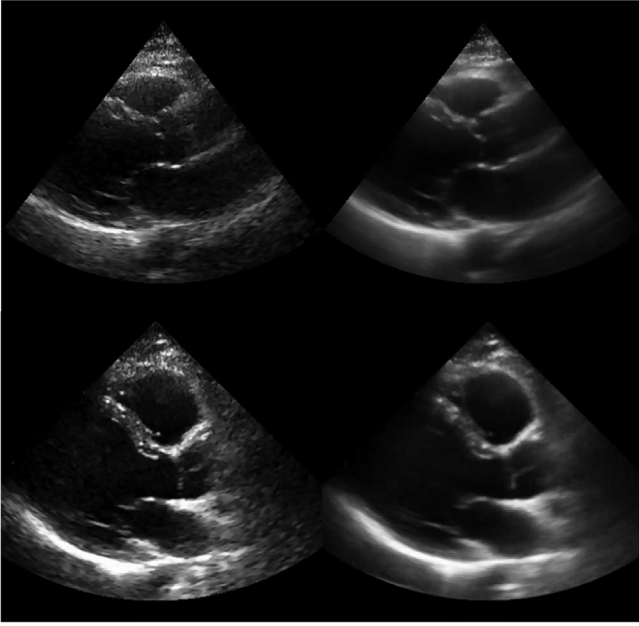


Fig. 5. Original (left) and compound (right) parasternal long axis ED frames of average (top) and high (bottom) image quality and diagnostic value. The images are generated using the temporal compounding approach as described in [105] and [112]. Compounding suppresses tissue speckle and chamber noise substantially. Structures such as the IVS, RV, and aortic valve (top) and the RV and aortic valve (bottom) are enhanced without any noticeable blurring across cardiac tissue and cavities. The figure has been reproduced with relevant permission from [112].

scans by suppressing noise with no apparent loss of temporal resolution. Vitale *et al.* [109] presented the first attempt to use compounding of partially decorrelated B-mode images acquired over consecutive cardiac cycles. In this early attempt, the temporal alignment of corresponding frames was based on information extracted from the ECG signal. More precisely, the ED frames from each cardiac cycle were identified at the peaks of the QRS complex of the recorded ECG signal. Twenty two frames were then extracted using regular temporal displacement between two consecutive ED frames. Corresponding frames from consecutive cardiac cycles were spatially compounded by intensity averaging. The study examined the effect of compounding an increasing number of frames on noise and speckle. The results were promising with images from ten cardiac cycles providing a good tradeoff between noise suppression and processing resources. Similar approaches have in recent studies been adopted and combined with compounding of temporally adjacent frames as a preprocessing step for more effective image segmentation of cardiac structures [110], [111]. However, these studies [109]–[111] suffered from two major limitations. In the first instance, the studies assumed that cardiac cycles are occurring in regular intervals. Unfortunately, this is not the case in most clinical cardiac ultrasound scans. Second, no spatial alignment was performed on the temporally aligned frames prior to intensity averaging. Spatial alignment can compensate for larger movements of the heart during the multicycle image acquisition. Both limitations can lead to severe blurring of the imaged cardiac structure

depreciating substantially the diagnostic value of the processed images.

Olstad [113] extended the temporal compounding approach by introducing a rigid spatial alignment to compensate for larger cardiac movements during the multicycle image acquisition. Abiko *et al.* [104] presented a novel spatio-temporal alignment utilizing exclusively 1-D intensity information extracted from the central scan line of each frame. While a crude heuristic method for image alignment, the study demonstrated the potential for an accurate temporal alignment without making 1) any assumptions on the characteristics of the cardiac cycle and 2) use of ECG information. However, the study utilized very limited information from highly noisy images in order to perform the very important task of spatio-temporal image alignment prior to spatial compounding. Moreover, it assumed no image rotation or translation along the long-axis (only translation along the short-axis) over the multicycle scan. This assumption is very restrictive and may result in severe blurring of the imaged cardiac structures in the processed images. Perperidis *et al.* [105], [112] attempted to address this limitation by introducing a seven-stage nonlinear temporal alignment along with a robust rigid spatial alignment using exclusively intensity information from within the image sequences. Qualitative and quantitative results on the quality and diagnostic value of the processed images were very promising (Figs. 4 and 5). Giraldo-Guzman *et al.* [114] combined temporal compounding with anisotropic diffusion for enhanced speckle suppression. The approach compound images from three cardiac cycles before applying an anisotropic diffusion filter on them. The approach was tested on 20 cardiac ultrasound videos and compounding increased the SNR improvement by a factor of 3 when compared to just the anisotropic diffusion filter. Finally, in a feasibility study, Perperidis *et al.* [115] extended their earlier approach by acquiring and compounding adjacent (along the elevation plane), partially decorrelated cardiac slices from a single acoustic window. Therefore, decorrelated images could in principle be acquired using real-time 4-D matrix transducer technology over a single cardiac cycle, abolishing the requirement for a multicycle acquisition and an accurate spatio-temporal alignment process.

All of above studies have established the benefits of spatially compounding partially decorrelated images from consecutive cardiac cycles. Similar to other spatial compounding techniques, considerable noise suppression can be introduced along with enhancement of visually weak cardiac structures (Figs. 4 and 5). The potential of the approach has also been recognized by a number of studies [110], [111], [116], [117], even for other imaging modalities such as CT [118]. However, while the accurate and robust spatio-temporal image alignment is a key process for effective compounding of data from consecutive cardiac cycles, many current implementations fail to provide a reliable and effective registration approach. As a result, it is strongly believed that there are current research opportunities on the development of such spatio-temporal alignment algorithms as well as more advanced image compounding techniques.

III. OTHER CARDIAC ULTRASOUND IMAGE-ENHANCEMENT TECHNIQUES

Cardiac ultrasound suffers from numerous artifacts besides noise and speckle. Compounding can address some of these artifacts including acoustic shadowing, reverberations, and structures moving in and out of plane. However, there are artifacts that require more dedicated approaches, and while they limit the quality and diagnostic value of the acquired images considerably, there has not been substantial research interest in order to address them.

A. Contrast Enhancement

Limited contrast between cardiac tissue and chambers constitute a major limitation on cardiac ultrasound images (Figs. 4 and 5) making (when combined with noise) the delineation of cardiac structures very challenging for both automatic and manual, expert-driven approaches. Consequently, low contrast levels limit the diagnostic value as well as the effectiveness of postprocessing techniques such as image segmentation and registration of cardiac ultrasound images. Contrast agents such as microbubbles [119], [120] have been successfully used to enhance the delineation between cardiac chambers and the myocardium in cardiac ultrasound images [121]. However, due to their invasive nature, the coverage of such techniques goes beyond the scope of this paper. Noncontrast tissue harmonic imaging (THI) has also been used in order to enhance the contrast and delineation between cardiac tissue and chambers. Harmonics are frequencies that occur at multiples of the fundamental or transmitted frequency [122]. Ward *et al.* [123], [124] identified the nonlinear propagation properties of tissue contributing to harmonic ultrasound images. Averkiou *et al.* [125] presented some early *in vivo* harmonic images. Since then, numerous studies have qualitatively and quantitatively assessed the effect of THI, using second harmonic frequencies, on cardiac ultrasound data [126]–[129]. The effect of THI on specific techniques such as stress echocardiography has also been investigated [130], [131]. Through these studies, it has been well established that THI can enhance the quality of cardiac ultrasound images. However, there are still a number of challenging cases where effective postprocessing techniques are required for the contrast enhancement between cardiac tissue and chambers.

Boukerroui *et al.* [132] introduced a novel contrast and anatomic feature-enhancement approach based on a phase-based feature detection algorithm. The algorithm utilized feature asymmetry [133], a 2-D extension of phase congruency [134] providing a robust, brightness, and contrast-invariant detection of asymmetric image features, such as step edges. The sparse set of extracted features was then interpolated by a fast sparse surface interpolation (FSI) algorithm. Finally, a novel nonlinear processing method was developed reconstructing an approximation to the intensity inhomogeneities within the corrupted data which were subtracted from the original images. The algorithm was applied in a set of B-mode cardiac ultrasound image sequences. The results in contrast and anatomic feature enhancement were promising. However,

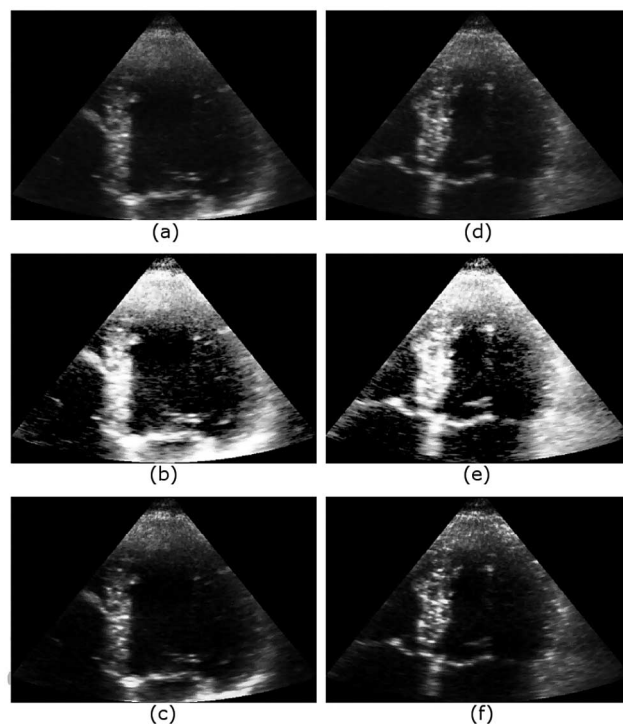


Fig. 6. Example of a dataset with good image quality. (a) Original ED frame. (b) ED frame after applying histogram equalization. (c) ED frame after applying ABTFs [117]. (d) Original ES frame. (e) ES frame after applying histogram equalization. (f) ES frame after applying ABTF. ABTF results have better contrast when compared with both the original and the histogram equalized images. The figure has been reproduced with relevant permission from [117].

Boukerroui *et al.* [132] identified that feature asymmetry was not very effective for images with low SNR. This drawback of feature asymmetry can impose a major limitation on the applicability of the contrast-enhancement approach to substantial proportion of clinical cardiac ultrasound images.

Zwirn and Akselrod [116], [117] introduced a very interesting technique for the automatic adjustment of the gray-levels used in cardiac ultrasound images aiming to enhance cardiac tissue visualization and tracking (Figs. 6 and 7). The technique was referred to as adaptive brightness transfer function (ABTF) and was based on the assumption that the gray-level histogram of cardiac ultrasound images can be approximated by the sum of three overlapping Gaussian distribution functions. Each Gaussian represented a different cardiac structure, with the low-intensity Gaussian representing cardiac chambers, and the medium- and high-intensity Gaussians representing low- and high-intensity cardiac tissue structures, respectively. The intersection between these three Gaussians would then act as thresholds defining the intensity range for each of the three image segments. Each section of the histogram was then processed individually using a number of techniques including histogram equalization, specification, and scaling. ABTF provided an extension to similar histogram analysis approaches for the enhancement of low-contrast images [135], [136]. The results from a qualitative and quantitative assessment of the ABTF on suppressing noise in cardiac chambers and enhancing contrast between cardiac tissue and chambers were promising (Figs. 6 and 7). However, for highly noisy

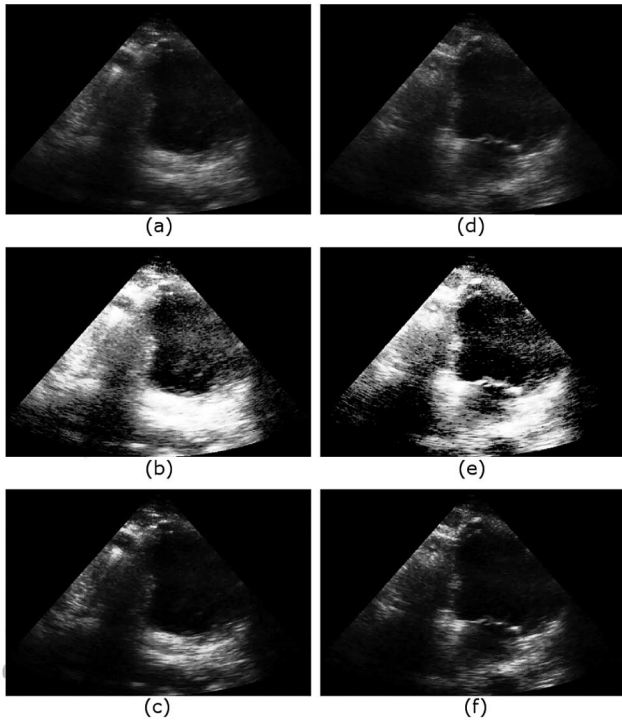


Fig. 7. Example of a dataset with average image quality. (a) Original ED frame. (b) ED frame after applying histogram equalization. (c) ED frame after applying ABTFs [117]. (d) Original ES frame. (e) ES frame after applying histogram equalization. (f) ES frame after applying ABTF. ABTF results have better contrast when compared with both the original and the histogram equalized images. The figure has been reproduced with relevant permission from [117].

data, the histogram of acoustic noise in cardiac chambers may overlap considerably with that of low-contrast tissue structures. Misclassification between cardiac tissue and chambers can prevent the suppression of high-amplitude noise and the delineation of low-contrast tissue. Nevertheless, morphological operations can partially compensate for such misclassifications while spatial compounding can suppress any remaining noise in cardiac chambers. Furthermore, like all the histogram-shape-based approaches, ABTF made a very strong assumption about the shape of the gray-level histograms of the processed cardiac ultrasound images. While some images may conform to it, such an assumption may be restrictive for the representation of a wide range of clinical datasets. Finally, ABTF assumed constant illumination throughout the scanned structure, which in many cardiac ultrasound scans is not accurate.

A few studies have introduced postprocessing techniques in an attempt to enhance contrast in cardiac ultrasound images. A number of postprocessing filters [30], [53], [63], [64], as well as spatial compounding approaches [86], [87], [93], have claimed to enhance the cardiac structure boundaries along with the contrast between cardiac tissue and chambers. Many of these noise suppression methods actually performed contrast and boundary preservation rather than enhancement. Specialized algorithms, primarily focusing on the contrast enhancement of cardiac ultrasound images, have also been developed [116], [117], [132]. Their results have demonstrated potential in enhancing the contrast and anatomic features in cardiac ultrasound images. However, some of these studies [116], [117] make strong and

potentially limiting assumptions on the histogram shape of the processed images, while others [132] have been identified to be effective only on data with high SNR. With low contrast between cardiac tissue and chambers being a well-recognized limitation in echocardiography, there is research opportunity in the advancement of the existing techniques developing a more effective and robust contrast-enhancement approach making fewer assumptions on the processed images.

B. Suppression of Stationary Noise

Side-lobes and reverberations between near-field structures such as ribs and intercostal muscles introduce acoustic noise (also referred to as clutter) in the cardiac ultrasound images [137]. Cardiac motion is considerably faster than the motion of such structures, which is predominantly introduced during the patient's respiration. Consequently, noise originating from such slow-moving structures appears to remain stationary throughout the multiframe acquisition. Stationary noise (clutter) is an artifact present in most cardiac ultrasound scans corrupting cardiac structures and therefore limiting the applicability of commonly used processing techniques as well as the diagnostic value of the images. Hozumi *et al.* [138] provided an early technique for suppressing stationary noise by introducing a high-pass filter on cardiac ultrasound data acquired over consecutive frames. More precisely, for each pixel within a reference image, the intensity variations over consecutive frames were extracted as a 1-D signal. This signal was decomposed into the tissue-generated component and a noise component by utilizing a high-pass filter. The high-pass filter was implemented by subtraction between the original noise-corrupted signal and a moving-average signal representing the stationary noise. The moving-average signal was generated by successively averaging a number of adjacent values of the original signal and shifting the averaging range. While the results in the study appeared promising, an implementation and evaluation of the technique introduced by Hozumi *et al.* [138] demonstrated a limited effect in noise suppression on clinical cardiac ultrasound images.

Zwirn and Akselrod [139] provided a different approach in order to address the stationary noise within cardiac ultrasound images. Unlike the approach by Hozumi *et al.* [138], no high-pass filter was employed. Instead, two reference frames were generated. The first reference frame contained the average intensity level over the consecutive frames. For strong stationary noise, the mean intensity value should be relatively high. The second reference image contained the MSE between each consecutive frame and the average intensity frame. For stationary noise, the MSE should be relatively low. The corresponding thresholds were derived utilizing the three Gaussians histogram decomposition introduced in [116] and [117]. For the average intensity frame, the threshold was set as the intersection of the two high-intensity Gaussians. Any pixel with intensity higher than the threshold could possibly be stationary noise. For the MSE frame, the threshold was set as the intersection of the two low-intensity Gaussians. Any pixel with intensity lower than the threshold could possibly be stationary noise. Pixels that were identified in both reference images as potential stationary noise

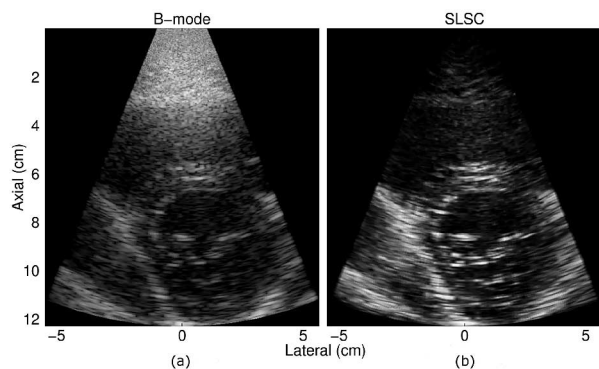


Fig. 8. (a) B-mode and (b) SLSC images of the LV. The corresponding SLSC image shows reduced clutter and more well-defined borders, especially in the near field. The figure has been reproduced with relevant permission from [140].

were removed from the original frame sequence. The results from the study were very promising. However, strong relatively akinetic tissue segments, such as the pericardium, could be falsely identified and removed as stationary noise.

In a more recent study, Lediju *et al.* [140]–[142] introduced a novel image acquisition and formation method referred to as short-lag spatial coherence (SLSC) imaging (Fig. 8). Instead of the conventional B-mode imaging, SLSC data display differences in spatial coherence. More precisely, spatial coherence was estimated by cross-correlating the time-delayed echoes received by individual transducer elements and plotting them as a function of element separation. The authors claimed that spatial coherence of the myocardium demonstrates different characteristics from that of cardiac chambers or clutter. This difference in spatial coherence tends to be larger for smaller element separations (shorter lags). Hence, they defined a metric called SLSC estimating the integral of the spatial coherence function over the first M lags (with $M \leq 30\%$ of the aperture size). An SLSC image was then formed by estimating the SLSC using a correlation kernel of one wavelength for each location (scan line and depth) across the imaging plane. The technique was first introduced in [141] and tested using simulated, phantom (lesions), and *in vivo* human thyroid data. It was then applied for the suppression of clutter noise in cardiac ultrasound data in [140] and [142]. The technique was qualitatively and quantitatively assessed on *in vivo* data from 14 volunteers (6 healthy and 8 patients). For the qualitative assessment of endocardial visualization, three experienced cardiology fellows were requested to rank (from 1—low to 3—high) a number of specific segments from mid-level short axis and apical four-chamber views of the LV. Furthermore, measures such as contrast, CNR, and SNR were derived from the short axis views. SLSC decreased the percentage of segments with poor myocardial visualization as well as the images characterized as of poor quality. Similarly, SLSC mostly improved the contrast, CNR, and SNR in comparison to the B-mode images. SLSC was extended to combine the harmonic signals (instead of just the fundamental) to form a new spatial coherence image. The approach was referred to as harmonic spatial coherence imaging (HSCI) [143]. HSCI demonstrated the potential to moderately improve on the SLSC performance. However, the

results presented in the study did not indicate any substantial improvement. Combining image formation approaches, such as SLSC and HSCI, with postprocessing approaches such as the one introduced by Zwirn and Akselrod, can potentially maximize the clutter suppression in cardiac ultrasound images.

IV. SUMMARY AND CONCLUSION

A wide range of artifacts limit the quality and diagnostic value of cardiac ultrasound images. Over the years, a number of studies have attempted to enhance the quality of cardiac ultrasound images. The majority of these studies have focused on the suppression of speckle and noise, a dominant limitation in cardiac ultrasound images.

Most existing noise/speckle suppression techniques can be broadly categorized into filtering and compounding techniques. Filtering techniques can be further categorized into 1) adaptive; 2) wavelet; and 3) anisotropic diffusion filters. While wavelet and anisotropic diffusion filters have demonstrated potential in the suppression of noise/speckle in medical ultrasound images, inherent properties limit their applicability in cardiac ultrasound images. Such limitations include the sensitivity to the size and shape of the filter window and sometimes to a required threshold value. Inappropriate choice may result in ineffective filtering. Finally, they do not address commonly observed artifacts such as high levels of chamber noise, limited contrast, shadowing, and reverberation. Consequently, there is still a lot of scope in the research and development of alternative methods for enhancing the quality and diagnostic value of cardiac ultrasound images.

Compounding techniques can be further categorized into frequency and spatial compounding. Spatial compounding approaches appear to be inherently more suitable for the enhancement of cardiac ultrasound images than filtering, demonstrating very strong potential in addressing a range of artifacts including 1) noise and speckle; 2) acoustic shadowing; 3) reverberations, 4) structures moving in and out of plane; and 5) limited delineation of visually weak cardiac structures. Large potential has been identified for spatial compounding of 3-D volumes acquired from different acoustic windows as well as 2-D images acquired from a single acoustic window over consecutive cardiac cycles. Most current limitations on both approaches can be resolved with the development of more effective, accurate, and robust spatio-temporal alignment techniques. As a result, there is a current research opportunity on the development of such alignment algorithms.

Cardiac ultrasound suffers from a number of artifacts besides noise and speckle. While such artifacts limit the image quality and diagnostic value of the acquired images considerably, there has not been substantial research to address them. Spatial compounding has been identified to address a wide range of cardiac ultrasound artifacts. Nevertheless, the limited contrast between cardiac tissue and chambers is currently not addressed by spatial compounding. Low tissue/chamber contrast constitutes a major limitation in cardiac ultrasound images. Therefore, more dedicated contrast-enhancement approaches are required. A number of studies have introduced postprocessing techniques that claim to enhance contrast while suppressing

noise in medical ultrasound images. However, most of these methods actually performed contrast and boundary preservation, by withholding noise suppression along edges, rather than enhancement. A very limited number of studies have attempted to develop more focused tools for enhancing the contrast and delineation between cardiac tissue and chambers. While a step in the right direction, there is plenty of scope for the development of more effective and robust contrast-enhancement techniques.

ACKNOWLEDGMENT

The author would like to thank N. McDicken, T. Anderson, and T. MacGillivray from the University of Edinburgh for their guidance. He would also like to thank A. White and D. Cusack from the Echocardiography Department of the Western General Hospital, Edinburgh, for their valuable input in this study.

REFERENCES

- [1] M. G. S. J. Sutton and J. D. Rutherford, *Clinical Cardiovascular Imaging*. Amsterdam, The Netherlands: Elsevier, 2004.
- [2] H. Feigenbaum, *Echocardiography*, 5th ed. Philadelphia, PA, USA: Lea & Febiger, 1994.
- [3] J. W. Goodman, "Some fundamental properties of speckle," *J. Opt. Soc. Amer.*, vol. 66, pp. 1145–1150, 1976.
- [4] C. B. Burckhardt, "Speckle in ultrasound B-mode scans," *IEEE Trans. Sonics Ultrason.*, vol. SU-25, no. 1, pp. 1–6, Jan. 1978.
- [5] R. F. Wagner, S. W. Smith, J. M. Sandrik, and H. Lopez, "Statistics of speckle in ultrasound B-scans," *IEEE Trans. Sonics Ultrason.*, vol. SU-30, no. 3, pp. 156–163, May 1983.
- [6] L. N. Bohs and G. E. Trahey, "A novel method for angle independent ultrasonic imaging of blood flow and tissue motion," *IEEE Trans. Biomed. Eng.*, vol. 38, no. 3, pp. 280–286, Mar. 1991.
- [7] J. D'Hooge *et al.*, "Two-dimensional ultrasonic strain rate measurement of the human heart in vivo," *IEEE Trans. Ultrason., Ferroelectr., Freq. Control*, vol. 49, no. 2, pp. 281–286, Feb. 2002.
- [8] Y. Notomi *et al.*, "Measurement of ventricular torsion by two-dimensional ultrasound speckle tracking imaging," *J. Amer. College Cardiol.*, vol. 45, pp. 2034–2041, 2005.
- [9] D. H. Evans and W. N. McDicken, *Doppler Ultrasound*, 2nd ed. Hoboken, NJ, USA: Wiley, 2000.
- [10] T. H. Marwick, C. M. Yu, and J. P. Sun, *Myocardial Imaging*. Oxford, U.K.: Blackwell, 2007.
- [11] H. Geyer *et al.*, "Assessment of myocardial mechanics using speckle tracking echocardiography: Fundamentals and clinical applications," *J. Amer. Soc. Echocardiograph.*, vol. 23, pp. 351–369, 2010.
- [12] H. Blessberger and T. Binder, "Two dimensional speckle tracking echocardiography: Clinical applications," *Heart*, vol. 96, pp. 2032–2040, 2010.
- [13] E. Konofagou, J. D'Hooge, and J. Ophir, "Cardiac elastography—A feasibility study," in *Proc. IEEE Ultrason. Symp.*, 2000, pp. 1273–1276.
- [14] E. Konofagou, J. D'hooge, and J. Ophir, "Myocardial elastography—A feasibility study in vivo," *Ultrasound Med. Biol.*, vol. 28, pp. 475–482, 2002.
- [15] E. Konofagou and J. Ophir, "A new elastographic method for estimation and imaging of lateral displacements, lateral strains, corrected axial strains and Poisson's ratios in tissues," *Ultrasound Med. Biol.*, vol. 24, pp. 1183–1199, 1998.
- [16] R. Lopata, M. Nillesen, H. Hansen, I. Gerrits, J. Thijssen, and C. de Korte, "Performance evaluation of methods for two-dimensional displacement and strain estimation using ultrasound radio frequency data," *Ultrasound Med. Biol.*, vol. 35, pp. 796–812, 2009.
- [17] C. Ma and T. Varghese, "Comparison of cardiac displacement and strain imaging using ultrasound radiofrequency and envelope signals," *Ultrasonics*, vol. 53, pp. 782–792, 2013.
- [18] J. B. A. Maintz and M. A. Viergever, "A survey of medical image registration," *Med. Image Anal.*, vol. 2, pp. 1–36, 1998.
- [19] T. Makela *et al.*, "A review of cardiac image registration methods," *IEEE Trans. Med. Imag.*, vol. 21, no. 9, pp. 1011–1021, Sep. 2002.
- [20] D. L. Pham, C. Xu, and J. L. Prince, "Current methods in medical image segmentation," *Annu. Rev. Biomed. Eng.*, vol. 2, pp. 315–337, 2000.
- [21] A. Hammoude, "Endocardial border identification in two-dimensional echocardiographic images: Review of methods," *Comput. Med. Imag. Graph.*, vol. 22, pp. 181–193, 1998.
- [22] J. A. Noble and D. Boukerrouj, "Ultrasound image segmentation: A survey," *IEEE Trans. Med. Imag.*, vol. 25, no. 8, pp. 987–1010, Aug. 2006.
- [23] M. J. Ledesma-Carbayo, J. Kybic, M. Desco, A. Santos, and M. Unser, "Cardiac motion analysis from ultrasound sequences using non-rigid registration," *Medical Image Computing and Computer-Assisted Intervention – MICCAI 2001*. Utrecht, The Netherlands: Springer Berlin Heidelberg, Oct. 14–17, 2001, vol. 2208, pp. 889–896.
- [24] V. Walimbe *et al.*, "Mutual information-based multimodality registration of cardiac ultrasound and SPECT images: A preliminary investigation," *Int. J. Cardiovasc. Imag.*, vol. 19, pp. 483–494, 2003.
- [25] M. M. Nillesen *et al.*, "Segmentation of the heart muscle in 3-D pediatric echocardiographic images," *Ultrasound Med. Biol.*, vol. 33, pp. 1453–1462, 2007.
- [26] V. Zagrodsky, V. Walimbe, C. R. Castro-Pareja, J. X. Qin, J. M. Song, and R. Shekhar, "Registration-assisted segmentation of real-time 3-D echocardiographic data using deformable models," *IEEE Trans. Med. Imag.*, vol. 24, no. 9, pp. 1089–1099, Sep. 2005.
- [27] J. C. Bamber and C. Daft, "Adaptive filtering for reduction of speckle in ultrasonic pulse-echo images," *Ultrasonics*, vol. 24, pp. 41–44, Jan. 1986.
- [28] T. Loupas, W. N. McDicken, and P. L. Allan, "An adaptive weighted median filter for speckle suppression in medical ultrasonic images," *IEEE Trans. Circuits Syst.*, vol. 36, no. 1, pp. 129–135, Jan. 1989.
- [29] A. N. Evans and M. S. Nixon, "Biased motion-adaptive temporal filtering for speckle reduction in echocardiography," *IEEE Trans. Med. Imag.*, vol. 15, no. 1, pp. 39–50, Feb. 1996.
- [30] P. C. Tay, C. D. Garson, S. T. Acton, and J. A. Hossack, "Ultrasound despeckling for contrast enhancement," *IEEE Trans. Image Process.*, vol. 19, no. 7, pp. 1847–1860, Jul. 2010.
- [31] N. Biradar, M. L. Dewal, and M. K. Rohit, "Speckle noise reduction in B-mode echocardiographic images: A comparison," *IETE Tech. Rev.*, vol. 32, no. 6, pp. 1–19, 2015.
- [32] J. S. Lee, "Digital image enhancement and noise filtering by use of local statistics," *IEEE Trans. Pattern Anal. Mach. Intell.*, vol. PAMI-2, no. 2, pp. 165–168, Mar. 1980.
- [33] V. S. Frost, J. A. Stiles, K. S. Shanmugan, and J. C. Holtzman, "A model for radar images and its application to adaptive digital filtering of multiplicative noise," *IEEE Trans. Pattern Anal. Mach. Intell.*, vol. PAMI-4, no. 2, pp. 157–166, Mar. 1982.
- [34] D. T. Kuan, A. A. Sawchuk, T. C. Strand, and P. Chavel, "Adaptive restoration of images with speckle," *IEEE Trans. Acoust. Speech Signal Process.*, vol. ASSP-35, no. 3, pp. 373–383, Mar. 1987.
- [35] A. Lopes, R. Touzi, and E. Nezry, "Adaptive speckle filters and scene heterogeneity," *IEEE Trans. Geosci. Remote Sens.*, vol. 28, no. 6, pp. 992–1000, Nov. 1990.
- [36] J. Y. Jin, G. T. Silva, and A. C. Frery, "SAR despeckling filters in ultrasound imaging," *Lat. Amer. Appl. Res.*, vol. 34, pp. 49–53, Jan./Mar. 2004.
- [37] J. I. Koo and S. B. Park, "Speckle reduction with edge preservation in medical ultrasonic images using a homogeneous region growing mean filter (HRGMF)," *Ultrason. Imag.*, vol. 13, pp. 211–237, Jul. 1991.
- [38] M. Karaman, M. A. Kutay, and G. Bozdagi, "An adaptive speckle suppression filter for medical ultrasonic imaging," *IEEE Trans. Med. Imag.*, vol. 14, no. 2, pp. 283–292, Jun. 1995.
- [39] Y. Chen, R. Yin, P. Flynn, and S. Broschat, "Aggressive region growing for speckle reduction in ultrasound images," *Pattern Recognit. Lett.*, vol. 24, pp. 677–691, Feb. 2003.
- [40] R. J. Massay, R. B. Logan-Sinclair, J. C. Bamber, and D. G. Gibson, "Quantitative effects of speckle reduction on cross sectional echocardiographic images," *Brit. Heart J.*, vol. 62, pp. 298–304, 1989.
- [41] J. N. Kapur, P. K. Sahoo, and A. K. C. Wong, "A new method for gray-level picture thresholding using the entropy of the histogram," *Comput. Vis. Graph. Image Process.*, vol. 29, pp. 273–285, 1985.
- [42] F. Mao, J. Gill, D. Downey, and A. Fenster, "Segmentation of carotid artery in ultrasound images," in *Proc. IEEE 22nd Annu. Int. Conf. Eng. Med. Biol. Soc.*, 2000, pp. 1734–1737.
- [43] Y. Zimmer, R. Tepper, and S. Akselrod, "A two-dimensional extension of minimum cross entropy thresholding for the segmentation of ultrasound images," *Ultrasound Med. Biol.*, vol. 22, pp. 1183–1190, 1996.

- [44] Y. S. Kim and J. Ra, "Improvement of ultrasound image based on wavelet transform: Speckle reduction and edge enhancement," in *Proc. SPIE Proc. Med. Imag.*, 2005, vol. 5747, pp. 1085–1092.
- [45] S. Sudha, G. Suresh, and R. Sukanesh, "Speckle noise reduction in ultrasound images using context-based adaptive wavelet thresholding," *Int. J. Comput. Theory Eng.*, vol. 55, pp. 135–143, 2009.
- [46] D. L. Donoho, "De-noising by soft-thresholding," *IEEE Trans. Inf. Theory*, vol. 41, no. 3, pp. 613–627, May 1995.
- [47] A. Achim, A. Bezerianos, and P. Tsakalides, "Novel Bayesian multiscale method for speckle removal in medical ultrasound images," *IEEE Trans. Med. Imag.*, vol. 20, no. 8, pp. 772–783, Aug. 2001.
- [48] A. Pizurica, W. Philips, I. Lemahieu, and M. Achero, "A versatile wavelet domain noise filtration technique for medical imaging," *IEEE Trans. Med. Imag.*, vol. 22, no. 3, pp. 323–331, Mar. 2003.
- [49] H. Rabbani, M. Vafadust, P. Abolmaesumi, and S. Gazor, "Speckle noise reduction of medical ultrasound images in complex wavelet domain using mixture priors," *IEEE Trans. Biomed. Eng.*, vol. 55, no. 9, pp. 2152–2160, Sep. 2008.
- [50] S. Gupta, R. C. Chauhan, and S. C. Saxena, "Robust non-homomorphic approach for speckle reduction in medical ultrasound images," *Med. Biol. Eng. Comput.*, vol. 43, pp. 189–195, 2005.
- [51] M. S. Uddin, M. Tahtali, A. J. Lambert, M. R. Pickering, M. Marchese, and I. Stuart, "Nonlinear multi-scale complex wavelet diffusion based speckle reduction approach for 3D ultrasound images," in *Proc. SPIE Appl. Digit. Image Process.*, San Diego, CA, USA, 2014, vol. 9217, pp. 92171A-1–92171A-6.
- [52] S. C. Kang, S. M. Lee, and S. H. Hong, "Noise reduction of echocardiographic images using wavelet filtering," in *Proc. Int. Conf. Signal Process.*, Beijing, China, 1998, pp. 267–270.
- [53] X. Zong, A. F. Laine, and E. A. Geiser, "Speckle reduction and contrast enhancement of echocardiograms via multiscale nonlinear processing," *IEEE Trans. Med. Imag.*, vol. 17, no. 4, pp. 532–540, Aug. 1998.
- [54] H. Guo, J. E. Odegard, M. Lang, R. A. Gopinath, I. W. Selesnick, and C. S. Burrus, "Wavelet based speckle reduction with application to SAR based ATD/R," in *Proc. IEEE Int. Conf. Image Process.*, 1994, pp. 75–79.
- [55] A. F. Laine, S. Schuler, F. Jian, and W. Huda, "Mammographic feature enhancement by multiscale analysis," *IEEE Trans. Med. Imag.*, vol. 13, no. 4, pp. 725–740, Dec. 1994.
- [56] S. Mallat and S. Zhong, "Characterization of signals from multiscale edges," *IEEE Trans. Pattern Anal. Mach. Intell.*, vol. 14, no. 7, pp. 710–732, Jul. 1992.
- [57] X. Hao, S. Gao, and X. Gao, "A novel multiscale nonlinear thresholding method for ultrasonic speckle suppressing," *IEEE Trans. Med. Imag.*, vol. 18, no. 9, pp. 787–794, Sep. 1999.
- [58] P. Perona and J. Malik, "Scale-space and edge detection using anisotropic diffusion," *IEEE Trans. Pattern Anal. Mach. Intell.*, vol. 12, no. 7, pp. 629–639, Jul. 1990.
- [59] Y. Yu and S. T. Acton, "Speckle reducing anisotropic diffusion," *IEEE Trans. Image Process.*, vol. 11, no. 11, pp. 1260–1270, Nov. 2002.
- [60] S. Aja-Fernandez and C. Alberola-Lopez, "On the estimation of the coefficient of variation for anisotropic diffusion speckle filtering," *IEEE Trans. Image Process.*, vol. 15, no. 9, pp. 2694–2701, Sep. 2006.
- [61] K. Z. Abd-Elmoniem, A. B. Youssef, and Y. M. Kadah, "Real-time speckle reduction and coherence enhancement in ultrasound imaging via nonlinear anisotropic diffusion," *IEEE Trans. Biomed. Eng.*, vol. 49, no. 9, pp. 997–1014, Sep. 2002.
- [62] K. Krissian, C. F. Westin, R. Kikinis, and K. G. Vosburgh, "Oriented speckle reducing anisotropic diffusion," *IEEE Trans. Image Process.*, vol. 16, no. 5, pp. 1412–1424, May 2007.
- [63] Y. Yue, M. M. Croitoru, A. Bidani, J. B. Zwischenberger, and J. W. Clark, "Ultrasound speckle suppression and edge enhancement using multiscale nonlinear wavelet diffusion," in *Proc. IEEE Eng. Med. Biol. Conf.*, Shanghai, China, 2005, pp. 6429–6432.
- [64] S. Finn, M. Glavin, and E. Jones, "Echocardiographic speckle reduction comparison," *IEEE Trans. Ultrason., Ferroelectr., Freq. Control*, vol. 58, no. 1, pp. 82–101, Jan. 2011.
- [65] J. Weickert, *Anisotropic Diffusion in Image Processing*. Stuttgart, Germany: Teubner-Verlag, 1998.
- [66] C. P. Loizou, C. S. Pattichis, C. I. Christodoulou, R. S. H. Istepanian, M. Pantziaris, and A. Nicolaides, "Comparative evaluation of despeckle filtering in ultrasound imaging of the carotid artery," *IEEE Trans. Ultrason., Ferroelectr., Freq. Control*, vol. 52, no. 10, pp. 1653–1669, Oct. 2005.
- [67] K. Z. Abd-Elmoniem, Y. M. Kadah, and A. B. M. Youssef, "Real time adaptive ultrasound speckle reduction and coherence enhancement," in *Proc. Int. Conf. Image Process.*, 2000, pp. 172–175.
- [68] Q. Sun, J. A. Hossack, J. Tang, and S. T. Acton, "Speckle reducing anisotropic diffusion for 3D ultrasound images," *Comput. Med. Imag. Graph.*, vol. 28, pp. 461–470, 2004.
- [69] Y. Gu, X. Yu, Z. Cui, L. Wang, and C. Xiu, "Detail-preserving despeckling under multiscale anisotropic diffusion in medical ultrasound images," in *Proc. 4th Int. Conf. Biomed. Eng. Informat. (BMEI)*, Shanghai, China, 2011, pp. 245–249.
- [70] W. K. Pratt, *Digital Signal Processing*. Hoboken, NJ, USA: Wiley, 1977.
- [71] Z. Wang, A. C. Bovik, H. R. Sheikh, and E. P. Simoncelli, "Image quality assessment: From error visibility to structural similarity," *IEEE Trans. Image Process.*, vol. 13, no. 4, pp. 600–612, Apr. 2004.
- [72] D. Kaplan and Q. Ma, "On the statistical characteristics of log-compressed Rayleigh signals: Theoretical formulation and experimental results," *J. Acoust. Soc. Amer.*, vol. 95, pp. 1396–1400, 1994.
- [73] D. A. Carpenter, M. J. Dadd, and G. Kossoff, "A multimode real time scanner," *Ultrasound Med. Biol.*, vol. 6, pp. 279–284, 1980.
- [74] M. Berson, A. Roncin, and L. Pourcelot, "Compound scanning with an electrically steered beam," *Ultrason. Imag.*, vol. 3, pp. 303–308, 1981.
- [75] D. P. Shattuck and O. T. von Ramm, "Compound scanning with a phased array," *Ultrason. Imag.*, vol. 4, pp. 93–107, Apr. 1982.
- [76] G. E. Trahey, S. W. Smith, and O. T. von Ramm, "Speckle pattern correlation with lateral aperture translation: experimental results and implications for spatial compounding," *IEEE Trans. Ultrason., Ferroelectr., Freq. Control*, vol. 33, no. 3, pp. 257–264, May 1986.
- [77] M. O'Donnell and S. D. Silverstein, "Optimum displacement for compound image generation in medical ultrasound," *IEEE Trans. Ultrason., Ferroelectr., Freq. Control*, vol. 35, no. 4, pp. 470–476, Jul. 1988.
- [78] P. A. Magnin and O. T. von Ramm, "Frequency compounding for improved grey scale imaging," *Ultrason. Imag.*, vol. 3, p. 213, 1981.
- [79] P. A. Magnin, O. T. von Ramm, and F. L. Thurstone, "Frequency compounding for speckle contrast reduction in phased array images," *Ultrason. Imag.*, vol. 4, pp. 267–281, Jul. 1982.
- [80] G. E. Trahey, J. W. Allison, S. W. Smith, and O. T. von Ramm, "A quantitative approach to speckle reduction via frequency compounding," *Ultrason. Imag.*, vol. 8, pp. 151–164, Jul. 1986.
- [81] U. Bencharit, J. L. Kaufman, N. M. Bilgutay, and J. A. Saniie, "Frequency and spatial compounding techniques for improved ultrasonic imaging," in *Proc. IEEE Ultrason. Symp.*, Williamsburg, NY, USA, 1986, pp. 1021–1026.
- [82] G. E. Trahey, J. W. Allison, S. W. Smith, and O. T. von Ramm, "Simultaneous frequency and spatial compounding for increased speckle reduction," *Ultrason. Imag.*, vol. 8, p. 68, 1986.
- [83] P. Soler, O. Gerard, P. Allain, E. Saloux, E. Angelini, and I. Bloch, "Comparison of fusion techniques for 3D+T echocardiography acquisitions from different acoustic windows," in *Proc. IEEE Comput. Cardiol. Conf.*, Lyon, France, 2005, pp. 141–144.
- [84] V. Grau and J. A. Noble, "Adaptive multiscale ultrasound compounding using phase information," in *Proc. Int. Conf. Med. Image Comput. Comput.-Assisted Interv.*, Palm Springs, CA, USA, 2005, pp. 589–596.
- [85] M. Felsberg and G. Sommer, "The monogenic signal," *IEEE Trans. Signal Process.*, vol. 49, no. 12, pp. 3136–3144, Dec. 2001.
- [86] C. Yao and G. P. Penney, "Spatial compounding of 3D echocardiography: Novel methodologies for large sets of images," in *Proc. Med. Image Understand. Anal. Conf.*, Dundee, U.K., 2008, pp. 69–73.
- [87] K. Rajpoot, J. A. Noble, V. Grau, C. Szmigielski, and H. Becher, "Multiview RT3D echocardiography image fusion," *Functional Imaging and Modeling of the Heart*. Nice, France: Springer Berlin Heidelberg, Jun. 3–5, 2009, vol. 5528, pp. 134–143.
- [88] C. Yao, J. M. Simpson, T. Schaeffter, and G. P. Penney, "Spatial compounding of large numbers of multi-view 3D echocardiography images using feature consistency," in *Proc. IEEE Int. Symp. Biomed. Imag.: Nano Macro*, London, U.K., 2010, pp. 968–971.
- [89] C. Yao, J. M. Simpson, T. Schaeffter, and G. P. Penney, "Multi-view 3D echocardiography compounding based on feature consistency," *Phys. Med. Biol.*, vol. 56, p. 6109, 2011.
- [90] V. Grau, H. Becher, and J. A. Noble, "Registration of multiview real-time 3-D echocardiographic sequences," *IEEE Trans. Med. Imag.*, vol. 26, no. 9, pp. 1154–1165, Sep. 2007.
- [91] G. Gao, K. Reddy, M. Yingliang, and K. S. Rhode, "Real-time compounding of three-dimensional transesophageal echocardiographic volumes: The phantom study," in *Proc. IEEE Eng. Med. Biol. Soc.*, Minneapolis, MN, USA, 2009, pp. 499–502.
- [92] M. J. Gooding, K. Rajpoot, S. Mitchell, P. Chamberlain, S. H. Kennedy, and J. A. Noble, "Investigation into the fusion of multiple 4-D fetal echocardiography images to improve image quality," *Ultrasound Med. Biol.*, vol. 36, pp. 957–966, 2010.

- [93] C. Szmigielski *et al.*, "Real-time 3D fusion echocardiography," *J. Amer. College Cardiol.: Cardiovasc. Imag.*, vol. 3, pp. 682–690, 2010.
- [94] H. W. Mulder, M. van Stralen, H. van der Zwaan, K. Y. E. Leung, J. G. Bosch, and J. P. W. Pluim, "Multiframe registration of real-time three-dimensional echocardiography time series," *J. Med. Imag.*, vol. 1, p. 014004, 2014.
- [95] H. W. Mulder, M. van Stralen, H. B. van der Zwaan, K. Y. E. Leung, J. G. Bosch, and J. P. W. Pluim, "Registration of multi-view apical 3D echocardiography images," in *Proc. SPIE Med. Imag.: Image Process.*, Lake Buena Vista, FL, USA, 2011, vol. 7962, p. 10.
- [96] S. K. Jespersen, J. E. Wilhjelm, and H. Sillesen, "In vitro spatial compound scanning for improved visualization of atherosclerosis," *Ultrasound Med. Biol.*, vol. 26, pp. 1357–1362, Oct. 2000.
- [97] O. Petrovic *et al.*, "Digital averaging to facilitate two-dimensional echocardiographic measurements," *J. Clin. Ultrasound*, vol. 14, pp. 367–372, 1986.
- [98] W. Li *et al.*, "Temporal averaging for quantification of lumen dimensions in intravascular ultrasound images," *Ultrasound Med. Biol.*, vol. 20, pp. 117–122, 1994.
- [99] B. Achmad, M. M. Mustafa, and A. Hussain, "Inter-frame enhancement of ultrasound images using optical flow," *Visual Informatics: Bridging Research and Practice*. Kuala Lumpur, Malaysia: Springer Berlin Heidelberg, Nov. 11–13, 2009, vol. 5857, pp. 191–201.
- [100] J. L. Barron, D. J. Fleet, S. S. Beauchemin, and T. A. Burkitt, "Performance of optical flow techniques," in *Proc. IEEE Comput. Soc. Conf. Comput. Vis. Pattern Recognit.*, Champaign, IL, USA, 1992, pp. 236–242.
- [101] M. dos Reis *et al.*, "Semi-automatic detection of the left ventricular border," in *Proc. IEEE Eng. Med. Biol. Soc. Conf.*, Vancouver, BC, Canada, 2008, pp. 218–221.
- [102] M. dos Reis *et al.*, "On the use of motion-based frame rejection in temporal averaging denoising for segmentation of echocardiographic image sequences," in *Proc. IEEE Eng. Med. Biol. Soc. Conf.*, 2009, pp. 507–510.
- [103] C. H. Lin, Y. N. Sun, and C. J. Lin, "A motion compounding technique for speckle reduction in ultrasound images," *J. Digit. Imag.*, vol. 23, pp. 246–257, 2010.
- [104] Y. Abiko, T. Ito, and M. Nakajima, "Improvement on quality of echocardiograms," *Acoust. Imag.*, vol. 23, pp. 169–176, 1997.
- [105] A. Perperidis, D. Cusack, N. McDicken, T. MacGillivray, and T. Anderson, "Temporal compounding of cardiac ultrasound data: Improving image quality and clinical measurement repeatability," in *Proc. IEEE Annu. Int. Conf. Eng. Med. Biol. Soc. (EMBC'09)*, Minneapolis, MN, USA, 2009, pp. 3661–3664.
- [106] E. van Ocken, V. A. Glaes, and D. L. Brutsaert, "Image enhancement by digital averaging of 2-dimensional echopictures," in *Proc. 4th Eur. Congr. Ultrasound Med.*, Amsterdam, Netherlands, 1981, p. 69.
- [107] R. B. L. Sinclair, P. J. Oldershaw, and D. G. Gibson, "Computing in echocardiography," *Prog. Cardiovasc. Dis.*, vol. 25, pp. 465–486, 1983.
- [108] M. A. Unser, L. Dong, G. Pelle, P. Brun, and M. Eden, "Restoration of echocardiograms using time warping and periodic averaging on a normalized time scale," in *Proc. SPIE Proc. Med. Imag.*, 1989, pp. 84–93.
- [109] D. F. Vitale *et al.*, "Optimal number of averaged frames for noise reduction of ultrasound images," in *Proc. IEEE Comput. Cardiol. Conf.*, London, U.K., 1993, pp. 639–641.
- [110] J. C. Amorim, M. dos Reis, J. L. A. de Carvalho, A. F. da Rocha, and J. F. Camapum, "Improved segmentation of echocardiographic images using fusion of images from different cardiac cycles," in *Proc. IEEE Eng. Med. Biol. Soc. Conf.*, Minneapolis, MN, USA, 2009, pp. 511–514.
- [111] S. A. Melo *et al.*, "Semi-automatic algorithm for construction of the left ventricular area variation curve over a complete cardiac cycle," *Biomed. Eng. Online*, vol. 9, pp. 1–17, 2010.
- [112] A. Perperidis, D. Cusack, A. White, N. McDicken, T. MacGillivray, and T. Anderson, "Temporal compounding: A novel implementation and its impact on quality and diagnostic value in echocardiography," *Ultrasound Med. Biol.*, vol. 41, pp. 1749–1765, 2015.
- [113] B. Olstad, "ECG gated ultrasonic image compounding," U.S. Patent 6447450, 2002.
- [114] J. Giraldo-Guzmán, O. Porto-Solano, A. Cadena-Bonfanti, and S. H. Contreras-Ortiz, "Speckle reduction in echocardiography by temporal compounding and anisotropic diffusion filtering," in *Proc. SPIE 10th Int. Symp. Med. Inf. Process. Anal.*, Cartagena de Indias, Columbia, vol. 9287, 2015, pp. 92871F–92871F-6.
- [115] A. Perperidis, A. White, D. Cusack, W. N. McDicken, T. MacGillivray, and T. Anderson, "3D-to-2D compounding and its effect on cardiac ultrasound data," in *Proc. Med. Image Understand. Anal. Conf.*, Warwick, U.K., 2010, pp. 45–49.
- [116] G. Zwirn and S. Akselrod, "A histogram-based technique for echocardiographic image enhancement," in *Proc. Comput. Cardiol. Conf.*, 2004, pp. 81–84.
- [117] G. Zwirn and S. Akselrod, "Adaptive brightness transfer functions in echocardiography," *Ultrasound Med. Biol.*, vol. 31, pp. 649–661, 2005.
- [118] S. Bhat, I. V. Larina, K. V. Larin, M. E. Dickinson, and M. Liebling, "Multiple-cardiac-cycle noise reduction in dynamic optical coherence tomography of the embryonic heart and vasculature," *Opt. Lett.*, vol. 34, pp. 3704–3706, 2009.
- [119] V. Sboros, "Response of contrast agents to ultrasound," *Adv. Drug Del. Rev.*, vol. 60, pp. 1117–1136, 2008.
- [120] E. Stride and N. Saffari, "Microbubble ultrasound contrast agents: A review," in *Proc. Inst. Mech. Eng. H: J. Eng. Med.*, vol. 217, pp. 429–447, 2003.
- [121] J. R. Lindner, "Microbubbles in medical imaging: Current applications and future directions," *Nat. Rev. Drug Discov.*, vol. 3, pp. 527–533, 2004.
- [122] R. S. Shapiro, J. Wagreich, R. B. Parsons, A. Stancato-Pasik, H. C. Yeh, and R. Lao, "Tissue harmonic imaging sonography: Evaluation of image quality compared with conventional sonography," *Amer. J. Roentgenol.*, vol. 171, pp. 1203–1206, 1998.
- [123] B. Ward, A. C. Baker, and V. F. Humphrey, "Nonlinear propagation applied to the improvement of resolution in diagnostic medical ultrasound," *J. Acoust. Soc. Amer.*, vol. 101, pp. 143–154, 1997.
- [124] B. Ward, A. C. Baker, and V. F. Humphrey, "Non-linear propagation applied to the improvement of lateral resolution in medical ultrasound scanners," in *Proc. World Congr. Ultrason. Conf.*, Berlin, Germany, 1995, pp. 965–968.
- [125] M. A. Averkiou, D. N. Roundhill, and J. E. Powers, "A new imaging technique based on the nonlinear properties of tissues," in *Proc. IEEE Ultrason. Symp.*, Toronto, ON, Canada, 1997, pp. 1561–1566.
- [126] H. Becher *et al.*, "Improvement in endocardial border delineation using tissue harmonic imaging," *Echocardiography*, vol. 15, pp. 511–517, 1998.
- [127] K. Caidahl *et al.*, "New concept in echocardiography: Harmonic imaging of tissue without use of contrast agent," *Lancet*, vol. 352, pp. 1264–1270, 1998.
- [128] S. L. Mulvagh, D. A. Foley, M. Belohlavek, and J. B. Seward, "Image enhancement by noncontrast harmonic echocardiography. Part I. Qualitative assessment of endocardial visualization," *Mayo Clin. Proc.*, vol. 73, pp. 1062–1065, 1998.
- [129] M. Belohlavek, K. Tanabe, S. L. Mulvagh, D. A. Foley, J. F. Greenleaf, and J. B. Seward, "Image enhancement by noncontrast harmonic echocardiography. Part II. Quantitative assessment with use of contrast-to-speckle ratio," *Mayo Clin. Proc.*, vol. 73, pp. 1066–1070, 1998.
- [130] D. G. Skolnick, S. G. Sawada, H. Feigenbaum, and D. S. Segar, "Enhanced endocardial visualization with noncontrast harmonic imaging during stress echocardiography," *J. Amer. Soc. Echocardiograph.*, vol. 12, pp. 559–563, 1999.
- [131] A. Franke *et al.*, "Non-contrast second harmonic imaging improves interobserver agreement and accuracy of dobutamine stress echocardiography in patients with impaired image quality," *Heart*, vol. 83, pp. 133–140, 2000.
- [132] D. Boukerroui, J. A. Noble, and M. Brady, "Feature enhancement in low quality images with application to echocardiography," *Information Processing in Medical Imaging*. Davis, CA, USA: Springer Berlin Heidelberg, Jun. 18–22, 2001, vol. 2082, pp. 453–460.
- [133] M. Mulet-Parada and J. A. Noble, "2D+T acoustic boundary detection in echocardiography," *Med. Image Anal.*, vol. 4, pp. 21–30, 2000.
- [134] P. Kovesi, "Image features from phase congruency," *Visere J. Comput. Vis. Res.*, vol. 1, pp. 1–26, 1999.
- [135] M. Abdullah-Al-Wadud, H. Kabir, M. A. A. Dewan, and O. Chae, "A dynamic histogram equalization for image contrast enhancement," *IEEE Trans. Consum. Electron.*, vol. 53, no. 2, pp. 593–600, May 2007.
- [136] H. Ibrahim and N. S. P. Kong, "Brightness preserving dynamic histogram equalization for image contrast enhancement," *IEEE Trans. Consum. Electron.*, vol. 53, no. 4, pp. 1752–1758, Nov. 2007.
- [137] M. A. Lediju Bell, B. C. Byram, and G. E. Trahey, "Sources and characterization of clutter in cardiac B-mode images," in *Proc. IEEE Int. Ultrason. Symp. (IUS)*, Rome, Italy, 2009, pp. 1419–1422.
- [138] T. Hozumi *et al.*, "Visualization of clear echocardiographic images with near field noise reduction technique: Experimental study and clinical experience," *J. Amer. Soc. Echocardiograph.*, vol. 11, pp. 660–667, 1998.
- [139] G. Zwirn and S. Akselrod, "Stationary clutter rejection in echocardiography," *Ultrasound Med. Biol.*, vol. 32, pp. 43–52, 2006.

- [140] M. A. Lediju Bell, R. Goswami, and G. E. Trahey, "Clutter reduction in echocardiography with short-lag spatial coherence (SLSC) imaging," in *Proc. 9th IEEE Int. Symp. Biomed. Imag. (ISBI)* Barcelona, Spain, 2012, pp. 1116–1119.
- [141] M. A. Lediju Bell, G. E. Trahey, B. C. Byram, and J. J. Dahl, "Short-lag spatial coherence of backscattered echoes: Imaging characteristics," *IEEE Trans. Ultrason., Ferroelectr., Freq. Control*, vol. 58, no. 7, pp. 1377–1388, Jul. 2011.
- [142] M. A. Lediju Bell, R. Goswami, J. A. Kisslo, J. J. Dahl, and G. E. Trahey, "Short-lag spatial coherence imaging of cardiac ultrasound data: Initial clinical results," *Ultrasound Med. Biol.*, vol. 39, pp. 1861–1874, Oct. 2013.
- [143] M. A. Lediju Bell, R. Goswami, J. J. Dahl, and G. E. Trahey, "Improved visualization of endocardial borders with short-lag spatial coherence imaging of fundamental and harmonic ultrasound data," in *Proc. IEEE Int. Ultrason. Symp. (IUS)*, Dresden, Germany, 2012, pp. 2129–2132.



Antonios Perperidis was born in Athens, Greece, in 1983. He received the B.Sc. degree in computer science, the M.Sc. degree in remote sensing and image processing, and the Ph.D. degree in medical image analysis from the University of Edinburgh, Edinburgh, U.K., in 2004, 2006, and 2011, respectively.

Since 2011, he has worked as a Research Associate in biomedical image analysis and engineering with the University of Edinburgh, Edinburgh, U.K., and Heriot Watt University, Edinburgh, U.K. His research interests include the development of image processing techniques that enhance the performance of medical imaging devices in clinical practice.