

Benign rolandic epilepsy and generalized paroxysms: A study of 13 patients

Rodrigo Vargas, Lucas Beltrán, Rafael Lizama, Gabriela Reyes Valenzuela, Roberto Caraballo*

Hospital de Pediatría "Prof. Dr. Juan P Garrahan", Buenos Aires, Argentina

ARTICLE INFO

Article history:

Received 13 December 2017
Received in revised form 20 February 2018
Accepted 5 March 2018
Available online xxx

Keywords:

Benign
Centrottemporal spikes
Rolandic epilepsy
Generalized paroxysms
Spike and waves

ABSTRACT

Purpose: To present a retrospective study of 13 children with benign epilepsy with centrottemporal spikes (BECTS), also known as benign rolandic epilepsy (BRE), associated with generalized spikes and waves as the only EEG manifestation at onset.

Method: Charts of children with typical clinical criteria of BRE electroclinically followed-up between February 2000 and February 2015 were reviewed.

Results: Among 309 patients who met the electroclinical criteria of BRE, we identified 13 children who presented with the typical clinical manifestations but who, on the EEG, only had generalized paroxysms at onset that continued along the course of the syndrome. Generalized spike-and-wave discharges were observed in all patients when awake and during sleep (100%). During the evolution no particular electroclinical pattern was observed. The patients responded well to antiepileptic drugs, such as valproic acid and levetiracetam. Outcome was good in all patients.

Conclusions: We found evidence that patients with BRE may have generalized EEG discharges at onset as the sole manifestation lasting throughout the course of the syndrome. In some, focal paroxysms developed later. The course was benign. In our group of patients, clinical features and evolution were similar to those of typical cases of BRE. Response to valproic acid and levetiracetam was found to be particularly good.

© 2018 British Epilepsy Association. Published by Elsevier Ltd. All rights reserved.

1. Introduction

Benign rolandic epilepsy (BRE) also known as benign epilepsy with centro-temporal spikes (BECTS) is a focal epilepsy of childhood characterized by motor focal seizures and particular EEG abnormalities in the absence of neurological deficits [1]. BRE is the most common form of idiopathic epilepsy in children [2]. In spite of the concept that the qualification “benign” should be avoided in the milder epilepsy syndromes such as BRE, in this study we have kept this term. [3]. In the recent ILAE Classification proposal the term “idiopathic” has been replaced by “genetic” [3]; however, as the genetic marker in patients with BRE is not well known, it could be considered as probably genetic. Here, we have also maintained the terms “idiopathic localization-related epilepsy” and “idiopathic generalized epilepsy (IGE)”.

In BRE the seizures are usually infrequent, brief, and partial, paradoxically showing abundant interictal EEG abnormalities, and remit spontaneously before the end of adolescence [4]. The seizures are somatosensory and motor focal, mainly affecting the face and oropharynx, with speech arrest and hypersalivation and in some cases involving the upper limbs [5]. The typical EEG shows high-voltage spikes or spikes and waves in the centrottemporal region that may shift from side to side with a normal background.

In BRE patients, generalized spike-wave discharges are rather common and brief. Generalized 3–5-Hz slow-wave bursts intermixed with small spikes, with or without clinical seizures, were reported to occur in 4% of the cases [6,7].

BRE is easily diagnosed based on EEG features. Generalized spike discharges, also observed in childhood absence epilepsy (CAE) or IGE, were found to be appearing with or without seizures during follow-up periods. Considering the benign, age-related, and age-limited features of idiopathic localization-related epilepsies and IGEs, this finding suggests a neurobiological continuum between the two epilepsies [8].

* Corresponding author at: Combate de los Pozos 1881, Buenos Aires, 1245, Argentina.

E-mail address: rhcaballo@arnet.com.ar (R. Caraballo).

The aim of this study was to describe BRE patients in whom EEG findings were generalized spikes and waves as the only manifestation at onset.

2. Methods

Between February 2000 and February 2015, we evaluated 309 patients with BRE at the department of neurology of our hospital; 13 of these patients only had generalized spike-and-wave paroxysms at onset.

The following inclusion criteria for BRE were used:

- a Typical sensorimotor seizures affecting the orofacial district with or without generalization
- b Normal pregnancy and delivery
- c Uneventful past medical history
- d Normal psychomotor development at diagnosis
- e Normal brain imaging
- f Generalized spike-and-wave paroxysms as the sole manifestation at onset
- g Patients with typical electroclinical features of BRE who during follow-up presented with electroclinical features of other idiopathic focal epilepsies of childhood were also included

Patients with centro-temporal spikes alone or combined with generalized paroxysms at onset, or those with a normal EEG, with known mental or neurological deficits, or with typical electroclinical features of Panayiotopoulos (PS) or Gastaut-type childhood epilepsy with occipital paroxysms (CEOP) at onset were excluded.

We analyzed sex, age at onset, personal and family history of epilepsy, seizure duration and manifestations, circadian distribution, seizure frequency, response to therapy, and outcome.

EEGs were performed while awake and asleep. Electrodes were placed according to the international 10–20 system. Brain CT scan and MRI were performed in all patients.

Between February 2000 and February 2015, 13 patients who met the inclusion criteria of BRE were identified and have been followed up to the present time. All patients were evaluated longitudinally, clinically, and with EEGs for 2–8 years (mean: 4.5 years). A mean of 8 ± 3 EEGs were obtained for each patient. We evaluated the charts reviewing clinical and EEG details of all patients that were unanimously agreed upon by all authors.

3. Results

3.1. Number of patients and gender

Overall, 13 children, 8 boys and 5 girls, met the inclusion criteria of idiopathic BRE over a 15-year period between February 2000 and February 2015.

3.2. Age at onset

Age at first afebrile seizure ranged from 5 to 11.5 years, with a mean age of 6.5 and a median of 7 years.

3.3. Personal and family history of febrile seizures and epilepsy

A family history of epilepsy was found in five cases (38%). Febrile seizures were reported in two (31%) and migraine in one (11%).

3.4. Ictal manifestations

Oropharyngeal manifestations were observed in seven children (54%), unilateral facial sensorimotor seizures in four (31%), speech arrest in six (46%), and hypersalivation in seven (54%). Hemiclonic focal seizures were observed in three patients (23%). Six children had focal seizures to generalized seizures (46%). Consciousness

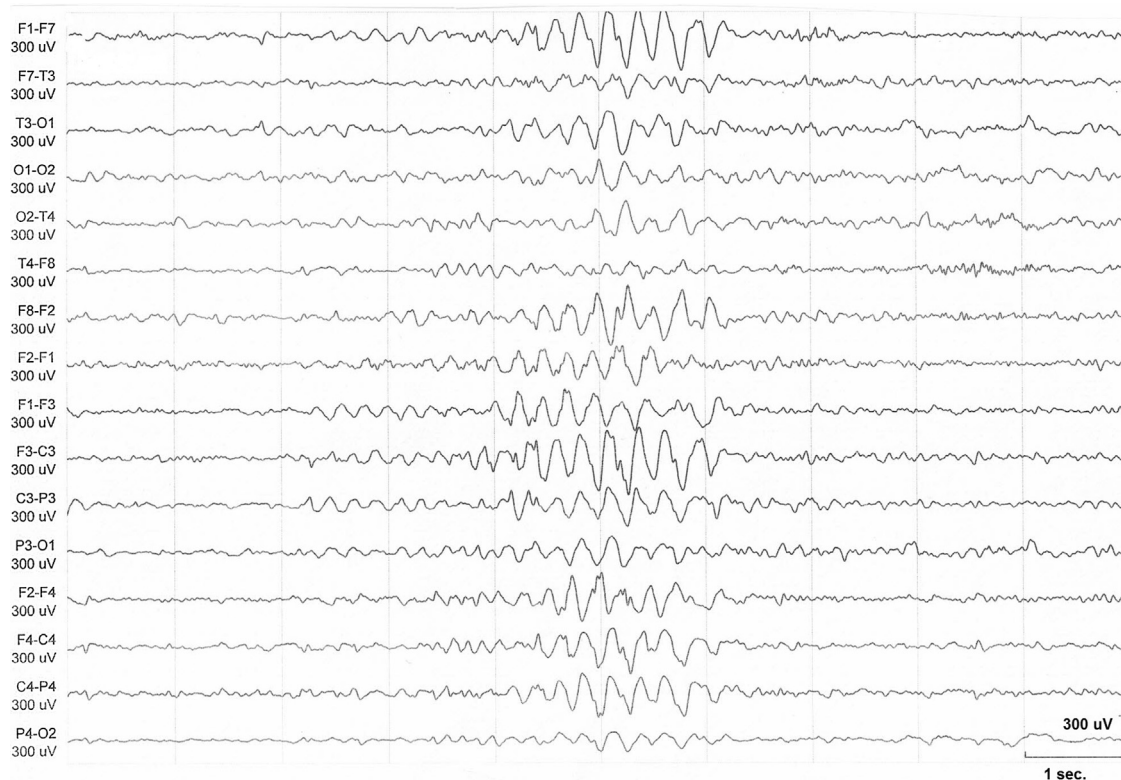


Fig. 1. The interictal EEG recording during sleep shows generalized spike-and-wave paroxysms predominantly in the anterior regions in a 7-year-old boy. Focal abnormality in the left frontal region preceding the generalized paroxysms is evident.

was partially impaired in four patients (31%). Two patients with typical electroclinical features of BRE also had ictal vomiting and head deviation as concurrent manifestations of Panayiotopoulos syndrome (PS). No typical absences were observed in any of the patients. All patients had two or more seizures.

According to parents report, the duration of seizures was around 3 min. Seizures occurred during sleep in 10 (77%) children, but also while awake in four (30%).

Three patients (23%) had a single seizure and nine (67%) had infrequent and sporadic seizures. The remaining child had monthly seizures.

3.5. Electroencephalographic findings

Generalized spike-and-wave discharges were observed in all patients when awake and during sleep (100%) (Figs. 1 and 2), occurring predominantly in anterior regions in 10 patients (77%). In seven patients voltage asymmetry was observed. Later in the course of the syndrome, four patients also had focal spikes during sleep, that were centro-temporal in three cases and temporo-occipital in the remaining one. Spikes were activated by sleep in all four cases and their pattern remained unchanged during the evolution. No ictal EEG recordings were registered in any of the patients.

3.6. Imaging studies

Brain CT scan and MRI were normal in all patients.

3.7. Treatment

Antiepileptic treatment with a single drug was started in 10 patients (77%): Valproic acid in eight and levetiracetam in two. In

six patients who received valproic acid and in both patients who received levetiracetam, the EEG became normal within two years of treatment.

Two patients, receiving topiramate and carbamazepine, respectively, initially did not respond well to the treatment; however, addition of levetiracetam resulted in excellent seizure control.

3.8. Evolution

All patients treated had an excellent response to AEDs. Seizures remitted within one or two years after treatment onset despite persistent EEG abnormalities in seven (54%) of them. Antiepileptic treatment was discontinued in eight patients who remained seizure free over a period of 3–11.5 years of follow-up.

None of the patients developed an electroclinical picture compatible with epilepsy with typical absences or an atypical evolution.

4. Discussion

In epilepsy, as in medicine in general, adequate diagnosis is essential not only because of its implications for the treatment but also as a prognostic tool. This may, however, be challenging as features sometimes overlap during the disease course, especially in childhood epilepsies.

Idiopathic childhood focal and generalized epilepsies are classically defined by their specific focal EEG findings and clinical correlates. They are assumed to have a commonly shared genetic background because of their idiopathic etiology. This may be explained by the concurrence of rolandic epilepsy and Panayiotopoulos syndrome and absence features [9,10] in the same patients, as seen in the benign childhood susceptibility syndrome [11].

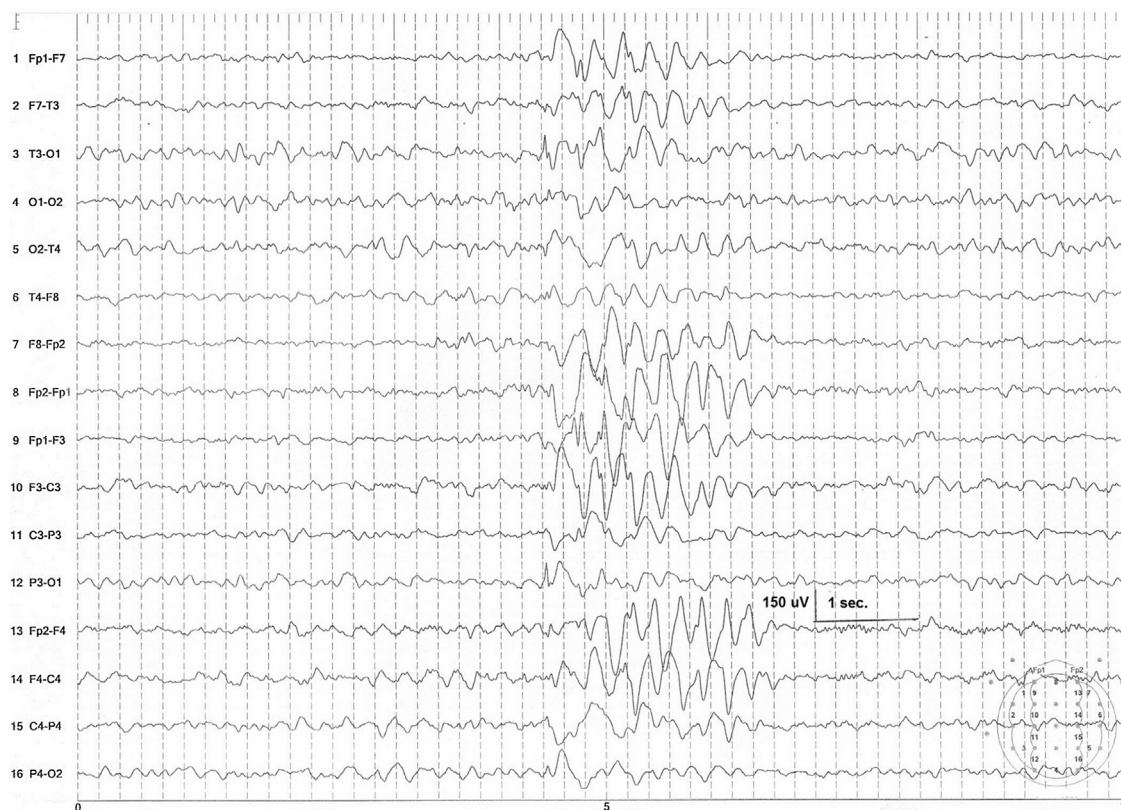

Fig. 2. The interictal EEG recording when awake shows centro-temporal sharp waves preceding irregular generalized spike-and-wave paroxysms predominantly in the anterior regions in an 8-year-old boy.

Here we report children with typical clinical manifestations of BRE, but who only had generalized paroxysms on the EEG at onset that continued along the course of the syndrome. In some of them, additionally to the generalized paroxysms, centrottemporal spikes appeared later. From the clinical point of view, no differences were found compared with the classic form of BRE with a benign course. During the evolution, no particular electroclinical pattern was found in our 13 patients either.

To our knowledge, similar cases with typical clinical manifestations of BRE only associated with generalized paroxysms on the EEG at onset have not been published. Recently, our group has reported patients with PS with similar EEG findings [12]. Additionally, the chapter on focal idiopathic epilepsies of childhood of the Blue Guide [13] states that generalized paroxysms as a sole EEG manifestation in children with PS may occur in 4% of the cases. This may be explained by the fact that in the different series of patients with PS published, this EEG feature as a unique neurophysiological pattern has not been considered as an inclusion criterion. It emphasizes that it is sometimes important not to apply too strict inclusion criteria, not only regarding clinical but also regarding EEG features, as if this is the case, patients with PS with particular electroclinical characteristics may be missed. Interestingly, in this series of patients two cases who started with BRE subsequently had an electroclinical pattern of PS.

The real incidence of spike-wave discharges in children with BRE is not well known, since numbers vary between 7% and 65% [14–16]. Nevertheless, we must be cautious in its interpretation because bursts of slow waves with spikes are seen during drowsiness in up to 20% of children between 3 and 6 years of age, especially those with a history of febrile seizures [17].

It is well known that in BRE, PS, and occipital idiopathic epilepsy of Gastaut generalized spike-and-wave discharges may occur [13] and that, conversely, juvenile myoclonic epilepsy and epilepsy with absence seizures may present with focal EEG features [18]. Additionally, it has been widely acknowledged that idiopathic localization-related epilepsy and IGE may coexist in the same patient at the same time or in different age periods [10,13,15,19] and types of focal and generalized epilepsies may occur in different members of the same family [13,15]. These findings suggest a close genetic relationship between idiopathic localization-related epilepsy and IGE. Perhaps, in this group of patients exome or whole genome sequencing will show a different pattern of gene variants.

The fact that in our series the generalized paroxysms do not increase in frequency during sleep, could be a marker differentiating these cases from the cases of IGEs in which the generalized SW always increase in frequency during sleep [20,21]. Focal sharp waves can be the only EEG marker in the absence of the typical slow-spike-slow-wave paroxysms in a significant number of cases of idiopathic partial epilepsy in children [15]. In Figs. 1 and 2, similar sharp waves preceding the diffuse discharges can be recognized.

The EEGs of our patients are different from those observed in IGE, including the generalized paroxysms seen in patients with CAE, considering the relatively focal manifestations. Therefore, in these cases the typical finding on the sleep EEG may be due to secondary bilateral synchrony unlike the generalized spike waves seen in CAE. Regardless of this discussion, it is important to be aware that in some patients with BRE these generalized paroxysms may occur at onset without independent focal sharp waves, even on the awake EEG.

Idiopathic focal epilepsies in childhood are caused by hyperexcitability of a particular functional area or system of the brain. The lower rolandic (somatosensory) cortex that represents the face and the oropharynx bilaterally is involved in BRE, the occipital areas (cortical visual system) are involved in occipital idiopathic epilepsy of Gastaut, and the central autonomic network is bilaterally and

diffusely involved in PS [22,23]. However, these conditions are probably related to the same dysfunctional process of brain maturation which is generally mild and reversible and has a genetic predisposition [13].

It is interesting to note that a small number of patients with any type of benign childhood susceptibility syndrome (BCSSS) may also suffer typical generalized convulsive or absence seizures either during the active phase of BCSSS or more often at a later stage [24]. Patients with syndromes of IGE including childhood absence epilepsy may, in sporadic cases, also have EEG focal spikes alone or together with any type of seizure associated with BCSSS [19].

5. Conclusion

In this retrospective study we found patients with typical clinical manifestations of BRE who had generalized EEG discharges as the sole manifestation at onset lasting throughout the course of the syndrome. In some, focal paroxysms developed later. Clinical features and evolution were the same as in the typical cases of BRE. The patients responded well to valproic acid and levetiracetam.

Up to now, in these patients no particular electroclinical evolution was found. Further studies should be performed to confirm these findings so as to manage these patients accordingly.

Conflict of interest

None of the authors of this paper has a financial or personal relationship with other people or organizations that could inappropriately influence or bias the content of the paper.

References

- [1] Fejerman N, Caraballo R. Benign focal epilepsies in infancy, childhood and adolescence. Paris: John Libbey Eurotext; 2007.
- [2] Fejerman N, Caraballo RH, Dalla Bernardina B. Benign childhood epilepsy with centrotemporal spikes. In: Fejerman N, Caraballo RH, editors. Benign focal epilepsies in infancy, childhood and adolescence. Montrouge: John Libbey Eurotext; 2007. p. 77–113.
- [3] Scheffer I, French J, Hirsch E, Jain S, et al. Classification of epilepsies: new concepts for discussion and debate—special report of the ILAE classification Task Force of the commission for classification and terminology. *Epilepsia* 2016;1(1-2):37–44. doi:<http://dx.doi.org/10.1002/epi4.5>.
- [4] Eeg-Olofsson O, Lundberg S, Raininko R. MRI in rolandic epilepsy. *Epilept Disord* 2000;2:51–3.
- [5] Holmes GL. Benign focal epilepsies of childhood. *Epilepsia* 1993;34(Suppl. 3):S49–61.
- [6] Gutierrez AR, Brick JF, Bodensteiner J. Dipole reversal: an ictal feature of benign partial epilepsy with centrotemporal spikes. *Epilepsia* 1990;31:544–8.
- [7] Veggiotti P, Beccaria F, Gatti A, Papalia G, Resi C, Lanzi G. Can protrusion of the tongue stop seizures in rolandic epilepsy? *Epileptic Disord* 1999;1:217–20.
- [8] Yum Mi-Sun, Ko Tae-Sun, Lee Eun Hye, Jeong Min-Hee. Electroencephalographic generalized features in idiopathic childhood focal epilepsies. *Seizure* 2010;19:222–5.
- [9] Ramelli GP, Donati F, Moser H, Vassella F. Concomitance of childhood absence and Rolandic epilepsy. *Clin Electroencephalogr* 1998;29(October (4)):177–80.
- [10] Caraballo R, Sologuestua A, Grañana N, et al. Idiopathic occipital and absence epilepsies appearing in the same children. *Pediatr Neurol* 2004;30(1):24–8.
- [11] Caraballo R, Aldao MR, Cachia P. Benign childhood seizure susceptibility syndrome: three case reports. *Epileptic Disord* 2011;13(2):133–9.
- [12] Caraballo R, Pasteris C, Portuondo E, Fortini S. Panayiotopoulos syndrome and diffuse paroxysms as the first EEG manifestation at clinical onset: study of nine patients. *Epileptic Disord* 2015;17(2):143–9.
- [13] Panayiotopoulos CP, Bureau M, Caraballo R, Dalla Bernardina B, Valeta T. In: Bureau M, Genton P, Dravet Ch, Delgado-Escueta A, Tassinari CA, Thomas P, Wolf P, editors. Idiopathic focal epilepsies in childhood. *Epileptic syndromes in infancy, childhood and adolescence*. 50 ed. John Libbey Eurotext; 2012. p. 217–54.
- [14] Degen R, Degen HE. Some genetic aspects of Rolandic epilepsy: waking and sleep EEGs in siblings. *Epilepsia* 1990;31:795–801.
- [15] Dalla Bernardina B, Sgrò V, Fejerman N, et al. Epilepsy with centro-temporal spikes and related syndromes. In: Roger J, Bureau M, Dravet CH, editors. *Epileptic syndromes in infancy, childhood and adolescence*. 4th edition Montrouge: John Libbey; 2005. p. 203–25.
- [16] Beydoun A, Garofalo EA, Drury I. Generalized spike-waves, multiple loci, and clinical course in children with EEG features of benign epilepsy of childhood with centrotemporal spikes. *Epilepsia* 1992;33:1091–6.

- [17] Alvarez N, Lombroso CT, Medina C, Cantlon B. Paroxysmal spike and wave activity in drowsiness in young children: its relationship to febrile convulsions. *Electroenceph Clin Neurophysiol* 1983;56:406–13.
- [18] Thomas P, Genton P, Gelisse P, In: Bureau M, Genton P, Dravet CH, Delgado-Escueta A, Tassinari CA, Thomas P, Wolf P, editors. *Juvenile Myoclonic epilepsy*. Epileptic syndromes in infancy, childhood and adolescence. 50 ed. Eurotext: John Libbey; 2012. p. 305–28.
- [19] Caraballo R, Fontana E, Darra F, et al. Childhood absence epilepsy and electroencephalographic focal abnormalities with or without clinical manifestations. *Seizures* 2008;17:617–24.
- [20] Sato S, Dreifuss FE, Penry JK. The effect of sleep on spike-wave discharges in absence seizures. *Neurology* 1973;23(December (12)):1335–45.
- [21] Tassinari CA, et al. Generalized Epilepsies and seizures during sleep. A polygraphic study. In: Van Praag, Meinardi, editors. *Brain and sleep*. Amsterdam: The Erven Bohn DV; 1974. p. 154–66.
- [22] Lada C, Skiadas K, Theodorou V, Covanis A. A study of 43 patients with Panayiotopoulos syndrome: a common and benign childhood seizure susceptibility. *Epilepsia* 2003;44:81–8.
- [23] Koutroumanidis M. Panayiotopoulos syndrome: an important electroclinical example of benign childhood system epilepsy. *Epilepsia* 2007;48:1044–53.
- [24] Caraballo R, Cersósimo R, Fejerman N. Late-onset childhood occipital epilepsy “Gastaut type”: A peculiar evolution. *Epileptic Disord* 2005;7(4):341–6.