

# Intraoral Vertical Ramus Osteotomy Procedure and Technique



Samuel J. McKenna, DDS, MD\*, Emily E. King, DMD

## KEYWORDS

• Orthognathic surgery • Intraoral vertical ramus osteotomy • Surgical technique

## KEY POINTS

- Intraoral vertical ramus osteotomy is a useful osteotomy for mandibular setback and rotational movements of the mandible.
- The correct placement of the osteotomy is critical to the preservation of proximal segment muscle attachments.
- Preservation of adequate proximal segment medial pterygoid attachment is necessary to prevent condylar sag.
- Intraoral vertical ramus osteotomy has a low incidence of neurosensory dysfunction.
- Intraoral vertical ramus osteotomy avoids unfavorable condylar loading and may simultaneously address skeletal malocclusion and temporomandibular joint symptoms.

## Introduction

Intraoral vertical ramus osteotomy (IVRO) is a useful technique in the management of horizontal mandibular excess, mandibular asymmetry, and correction of minor mandibular deficiency. Originally performed through an extraoral approach, with the introduction of the power oscillating saw, the procedure has been performed transorally for more than 30 years. The goal of the procedure is to perform a full-thickness vertical osteotomy through the mandibular ramus posterior to the mandibular foramen with the creation of a proximal segment consisting of the condyle and posterior ramus and a distal segment containing the anterior ramus, coronoid process, inferior alveolar nerve, and tooth-bearing mandible. It is a technically straightforward procedure that can be performed efficiently and with low morbidity. This article reviews the technical considerations, technical modifications, and potential pitfalls in performing IVRO.

## Surgical technique

### Preoperative planning

Horizontal mandibular excess can be addressed using IVRO with posterior positioning of the distal segment. Mandibular asymmetry, where there is an anticipated need for rotation around one ramus, can be efficiently managed with IVRO. Unilateral IVRO can be combined with contralateral sagittal split osteotomy (SSO) when correction of mandibular asymmetry dictates

setback on one side and advancement on the other side. Minor mandibular advancement (1–2 mm) is permissible with IVRO with preservation of the medial pterygoid muscle attachment. Small mandibular advancements are possible because preservation of the proximal segment medial pterygoid attachment will favor forward rotation of the proximal segment and assure contact with the advanced distal segment while preserving condylar seating.

Patients with symptomatic temporomandibular joint (TMJ) disorders may benefit from IVRO over SSO because of a condylotomy effect. With IVRO, muscle positioning of the proximal segment prevents unphysiologic joint loading. As with modified mandibular condylotomy, IVRO may prevent new or increased joint symptoms and possibly improve preexisting symptoms.<sup>1–3</sup> In contrast to modified mandibular condylotomy where medial pterygoid attachment is intentionally stripped from the proximal segment to promote condylar sag, in IVRO, stripping of the medial pterygoid must be avoided to assure condylar seating and stable postoperative occlusion.<sup>4,5</sup>

There are limitations to the amount of setback that is possible with IVRO. Generally, up to 10 mm of mandibular setback can be achieved. However, in the authors' experience with the class III Caucasian population, the requirement for mandibular setback of this magnitude is unusual and there is likely coexisting maxillary deficiency that should be addressed. Unless internal fixation is planned, the magnitude of setback is limited by the requirement to preserve the proximal segment medial pterygoid muscle attachment. Stripping of the medial pterygoid muscle to facilitate segment overlap can lead to condylar sag and bite instability at the time of maxillomandibular fixation (MMF) release. Additionally, unopposed activity of the lateral pterygoid muscle on the proximal segment can lead to condylar subluxation.<sup>4</sup> In the authors' experience, 5 to 6 mm of setback can be performed while keeping adequate medial pterygoid muscle attachment to obviate internal fixation. Early IVRO techniques, which did not emphasize preservation of medial

Department of Oral and Maxillofacial Surgery, Vanderbilt University School of Medicine, 1623 The Vanderbilt Clinic, Nashville, TN 37323-5225, USA

\* Corresponding author.

E-mail address: [samuel.mckenna@vanderbilt.edu](mailto:samuel.mckenna@vanderbilt.edu)

Atlas Oral Maxillofacial Surg Clin N Am 24 (2016) 37–43  
1061-3315/16/\$ - see front matter © 2016 Elsevier Inc. All rights reserved.  
<http://dx.doi.org/10.1016/j.cxom.2015.10.002>

[oralmxosurgeryatlas.theclinics.com](http://oralmxosurgeryatlas.theclinics.com)

pterygoid attachment, were associated with a 14% incidence of open bite after MMF release.<sup>5</sup> Modified IVRO techniques, which preserve medial pterygoid attachment, limit this complication.<sup>6</sup>

Preservation of medial pterygoid attachment requires that the magnitude of setback is not greater than the width of the proximal segment muscle attachment. If the planned setback exceeds the width of medial pterygoid attachment, the entire muscle will be stripped with obligatory proximal and distal segment overlap. When treatment planning, it is important to remember that the greater the mandibular setback planned, the wider the proximal segment needs to be to maintain sufficient medial pterygoid muscle. Virtual surgical planning is particularly helpful in making these determinations because the amount of proximal-distal segment overlap can be viewed preoperatively, the location of the mandibular foramen assessed, and the vertical osteotomy planned accordingly. If it is determined intraoperatively that adequate medial pterygoid attachment cannot be maintained, internal fixation should be considered to ensure condylar seating and proximal segment stability. Alternatively, such cases can be planned for SSO.

Internal fixation is technically more challenging with IVRO because of limited access and visibility. Right-angled instrumentation has enhanced the ability to apply internal fixation with IVRO, often obviating percutaneous access. Unless rigid internal fixation is used, a 2- to 3-week period MMF followed by 3 to 4 weeks of guiding elastic use is required after IVRO.

IVRO has limited applicability when mandibular advancement is indicated. Only small amounts of mandibular advancement (1–2 mm) can be achieved without creating an unacceptable gap between the proximal and distal segments. Further, advancement of the soft tissue envelope may promote distraction of the condyle. In the setting of 2-jaw surgery, vertical ramus shortening with posterior impaction of the maxilla will enhance condylar seating and may resist the tendency for unfavorable proximal segment positioning with planned small advancements. Conversely, when posterior vertical lengthening is planned with 2-jaw surgery, soft tissue envelope distracting forces, along with mandibular advancement, may promote unfavorable condylar positioning and impact ultimate occlusal stability.

When significant counterclockwise rotation of the distal mandibular segment is anticipated, as in correction of a class III anterior open bite, IVRO should be used cautiously, if at all. As noted earlier, closing rotations cause vertical lengthening of the soft tissue envelope, which promotes distraction of the proximal segment, and occlusal instability. Only small closing rotations should be considered, such as with a presurgical edge-to-edge incisor relationship.

A clear consideration in choosing IVRO over SSO is the statistically significant lower incidence of neurosensory disturbance in the distribution of the inferior alveolar nerve following surgery.<sup>6–8</sup> When considering performing 2-jaw surgery with mandible first surgery, SSO is preferred because of the relative ease of internal fixation.

## Preparation and patient positioning

- Patients are placed supine on the operating table.
- Nasoendotracheal intubation and general anesthesia are performed.

- Local anesthetic with epinephrine is infiltrated at the planned incision site, and inferior alveolar nerve block is performed.

## Surgical approach

- Mucosal incision is made medial to the external oblique ridge and 2 to 3 mm lateral to the mucogingival junction extending anteriorly from the level of the occlusal plane to the first mandibular molar.
- Periosteum is elevated to expose the lateral ramus from the inferior border of the ramus to the sigmoid notch.
- Periosteum should be elevated from the inferior border of the mandible at the inferior extent of the planned osteotomy to minimize the risk of injury to the marginal mandibular branch of the facial nerve.
- Periosteum is not elevated from the posterior border of the ramus.
- Sufficient temporalis tendon is stripped from the anterior border and lateral aspect of the coronoid process to release tension in the buccal flap.

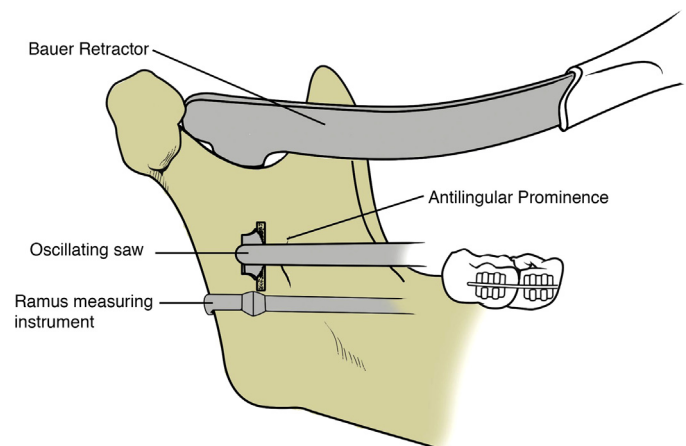
## Technical notes

- Care should be taken to make the mucosal incision within 2 to 3 mm of the mucogingival junction to limit formation of a scar band and food trap.
- To prevent stripping of the periosteum from the posterior ramus border, use of the Levasseur-Merrill retractor should be avoided.

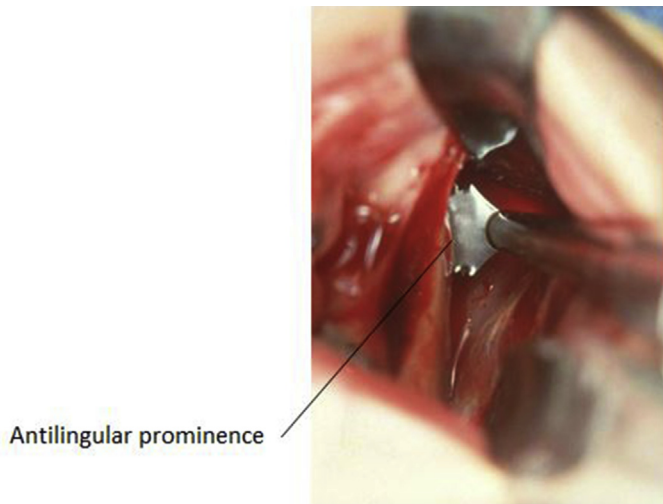
## Surgical procedure

### Step 1: identification of osteotomy location

- A Bauer retractor is placed to protect the contents of the sigmoid notch.
- The antilingual prominence is identified.
- A trial osteotomy is marked 7 to 8 mm anterior to the posterior border of the mandible, just posterior to the antilingual prominence, at the level of the mandibular foramen with the 11.7 × 7.0-mm oscillating blade.
- Confirm the correct placement of the trial osteotomy (Figs. 1 and 2).



**Fig. 1** Trial osteotomy at the level of the mandibular foramen and behind the antilingual prominence.



**Fig. 2** Operator view of antilingual prominence and trial osteotomy.

#### Technical notes

- The antilingual prominence, on the lateral surface of the ramus, is the lateral representation of the lingula on the medial surface of the ramus and is a useful but imperfect landmark. Osteotomies performed within the antilingual prominence may enter the mandibular foramen or canal.
- A second Bauer retractor may be placed in the antegonial notch to facilitate visualization of the lateral ramus, though one Bauer retractor is usually sufficient.
- To assist in judging the anterior-posterior location of the osteotomy, a sharply curved Freer elevator is helpful to estimate distance to the posterior border. A ramus measuring instrument with a laryngeal mirror or 30° endoscope visualization may be used to confirm correct osteotomy placement. When using the ramus measuring instrument, the instrument must closely approximate the posterior border of the mandible. If the ramus measuring instrument is not well adapted to the posterior border, the osteotomy will likely be placed too far posteriorly.
- The longer (11.7 × 12.0 mm) oscillating blade should not be routinely used to minimize the risk of injury to structures medial to the ramus.

#### Step 2: superior osteotomy

- The trial osteotomy is extended through the medial cortex of the ramus.
- The cutting edge of the blade is directed superiorly, and the osteotomy is continued superiorly through the sigmoid notch.
- The depth of the blade is decreased as the thinner portion of the ramus just below the sigmoid notch is approached to avoid damage to structures medial to the ramus.
- The Bauer retractor may be lifted slightly from the sigmoid notch to allow space for the blade to complete the most superior portion of the osteotomy.

#### Technical notes

- The shaft of the blade is stabilized along the lateral ramus as a pivot for the cutting edge.

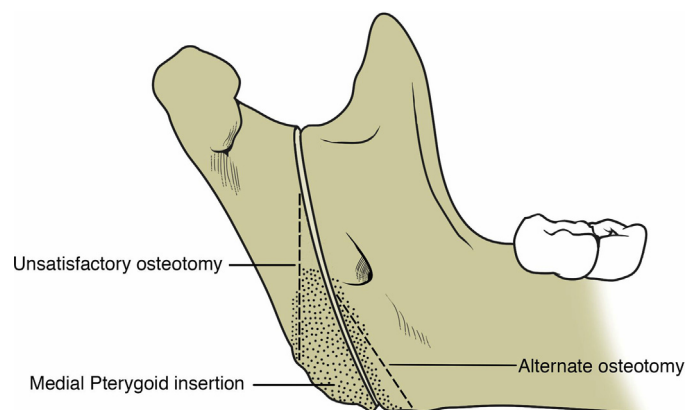
- The oscillating saw cuts most efficiently with the application of light pressure and a back-and-forth motion of the saw handpiece.
- Applying excessive pressure with the cutting edge of the oscillating saw results in less efficient cutting and may lead to handpiece overheating.

#### Step 3: inferior osteotomy

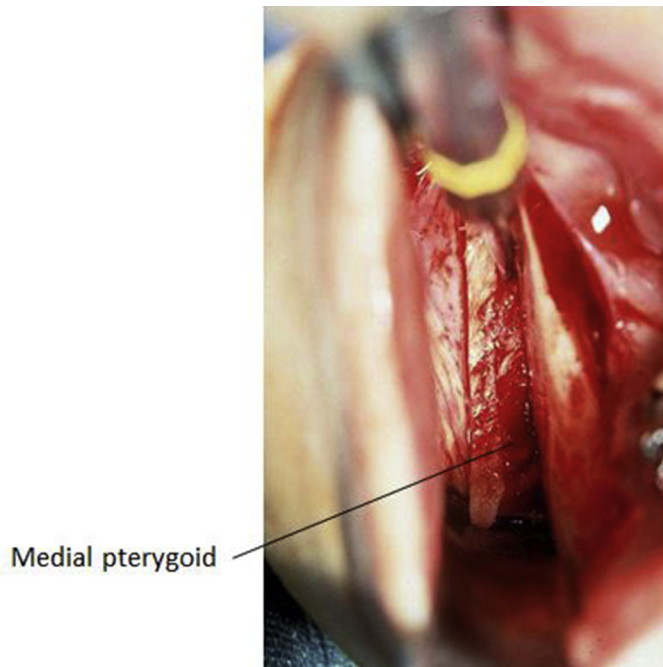
- Remove the upper Bauer retractor from the sigmoid notch and place a lower Bauer retractor in the antegonial notch.
- Without removing the saw from the completed superior osteotomy, redirect the cutting edge in an inferior direction.
- Below the antilingual prominence, the osteotomy is directed anteriorly to maximize proximal segment width.
- The distance from the osteotomy to the posterior border of the ramus is monitored as the osteotomy progresses inferiorly and the osteotomy is redirected anteriorly as needed.
- The osteotomy is completed through the inferior border of the mandible, and separation of the proximal segment and distal segment is confirmed.

#### Technical notes

- Avoid creating a posteriorly directed inferior osteotomy that results in a narrow and short proximal segment with inadequate medial pterygoid attachment. A separate, more anteriorly directed inferior osteotomy should be made if the osteotomy is progressing too posteriorly or in cases with planned large setback where medial pterygoid attachment must be maximized (Figs. 3 and 4).
- Common areas for incomplete osteotomy include the sigmoid notch and the inferior border. Incomplete osteotomy at the midramus is more likely if a separate anteriorly directed inferior osteotomy has been made.
- If the 11.5 × 7.0-mm oscillating saw blade is too short to complete the osteotomy through the medial cortex of the ramus, the osteotomy has likely been placed too far anteriorly. Rarely, ramus thickness is such that the longer blade is necessary. Use the longer blade with caution and never in the region of the sigmoid notch.
- When performing large mandibular setbacks, the coronoid process of the distal segment may interfere with the



**Fig. 3** Development of a long osteotomy to preserve proximal segment width. Alternative anteriorly directed osteotomy to maximize medial pterygoid muscle attachment.



**Fig. 4** Operator view of completed osteotomy with proximal segment distracted laterally demonstrating preservation of medial pterygoid insertion.

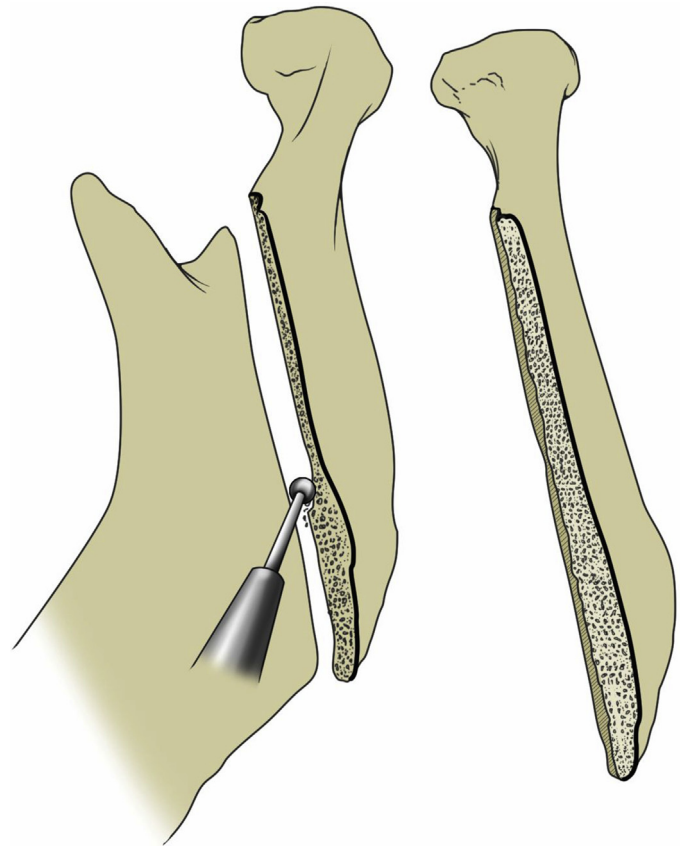
proximal segment. A simultaneous coronoidectomy may be useful in this situation. Proponents of this technique have found a reduction of bony interference during positioning of the distal segment posteriorly, better visualization of the sigmoid notch, and improved postoperative stability.<sup>9,10</sup>

#### Step 4: proximal segment trimming

- Using a rotary instrument and 3-mm round bur, the medial cortical edge of the proximal segment is trimmed to achieve the planned setback and segment overlap (Fig. 5).
- Adequate trimming has been achieved when the proximal segment can be passively positioned lateral to the distal segment without binding and/or posterior rotation of the proximal segment, with the mandible in final occlusion.
- Final trimming is completed after both ramus osteotomies have been performed and MMF is established.

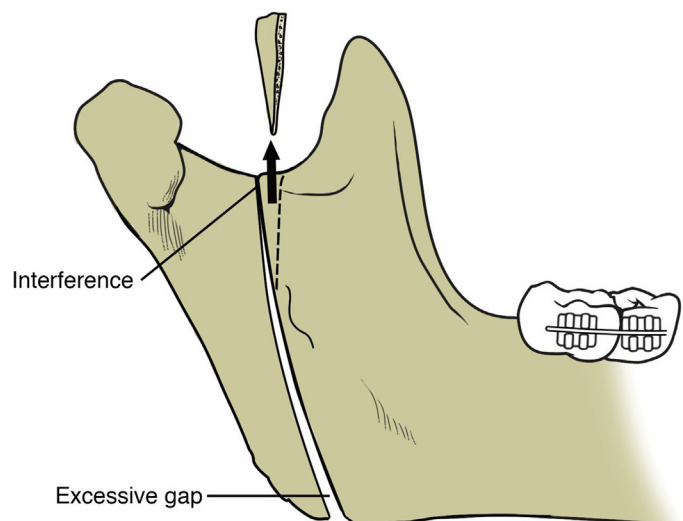
#### Technical notes

- Management of horizontal mandibular excess with IVRO often results in some counterclockwise rotation of the distal segment, as the mandible is setback. Superior interference at the level of the sigmoid notch is common. This interference must be relieved to prevent backwards rotation of the proximal segment and a gap at the inferior border of the osteotomy. With a significant superior interference, a second osteotomy can be performed to isolate and remove a small triangular piece of the superior portion of the distal segment (Fig. 6).
- Backward rotation of the proximal segment from inadequate trimming should also be avoided as it predisposes to forward relapse in class III patients.
- When using IVRO for small mandibular advancements, as the proximal segment rotates anteriorly, the first contact



**Fig. 5** Proximal segment is trimmed, creating a mortise overlap between the proximal and distal segments.

may occur prematurely at the inferior aspect of the osteotomy leaving a gap superiorly. Inferior interference between the proximal and distal segments can also occur during 2-jaw surgery with clockwise rotation of the maxillomandibular complex. This interference can be addressed with a second osteotomy to remove a small triangle of bone from the inferior aspect of the distal segment. This technique allows for passive apposition of



**Fig. 6** Supplemental osteotomy (arrow) of the distal segment to relieve superior interference.

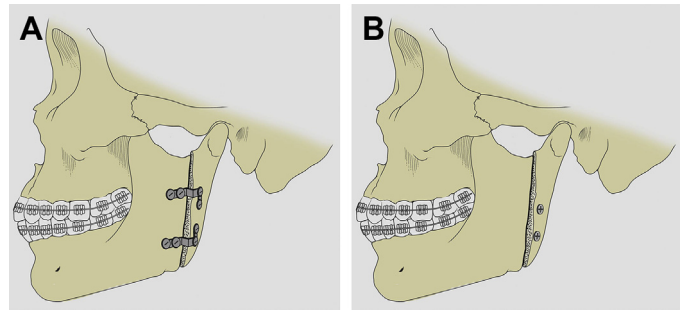
the segments without additional stripping of medial pterygoid muscle and proximal segment trimming (Fig. 7).

### Step 5: final proximal segment positioning

- Final occlusion and MMF is established.
- With condylar seating force applied to the inferior aspect of the proximal segment, verify passive, close apposition of the proximal and distal segments.
- Additional proximal segment trimming is performed as necessary.
- Surgical sites are thoroughly irrigated.
- The incisions are closed with a running chromic suture.

### Technical notes

- Persistent gap at the inferior border implies superior interference that should be trimmed.
- Excess proximal segment tip projection should be trimmed with a Kerrison rongeur.
- When vertical ramus osteotomy is performed with adequate proximal segment length and preservation of medial pterygoid muscle attachment to assure condylar seating, internal fixation is not required. Therefore, internal fixation following IVRO is generally not performed. However, there are circumstances when internal fixation might be required to assure condylar seating. As noted, procedures that result in lengthening of the soft tissue envelope of the ramus, such as vertical lengthening of the maxillomandibular complex, can result in condylar sag. More importantly, a poorly designed vertical ramus osteotomy with a short proximal segment and/or if the extent of setback leaves insufficient medial pterygoid attachment, condylar sag and even condylar subluxation may result.<sup>4-6</sup> In these situations, some form of internal fixation should be considered.
- Internal fixation can be established with L-shaped miniplates or a ladder plate. To apply internal fixation trans-orally, right-angle drills and screwdrivers are needed. Internal fixation can also be accomplished with a trans-buccal approach with the use of a trocar and sleeve system. When performing either approach, 2 L plates are preferred for sufficient stability and to obviate MMF (Fig. 8).
- Alternatively, if the setback has created sufficient overlap between the proximal and distal segments, internal



**Fig. 8** (A) Internal fixation using L-shaped miniplates. (B) Internal fixation using positioning screws.

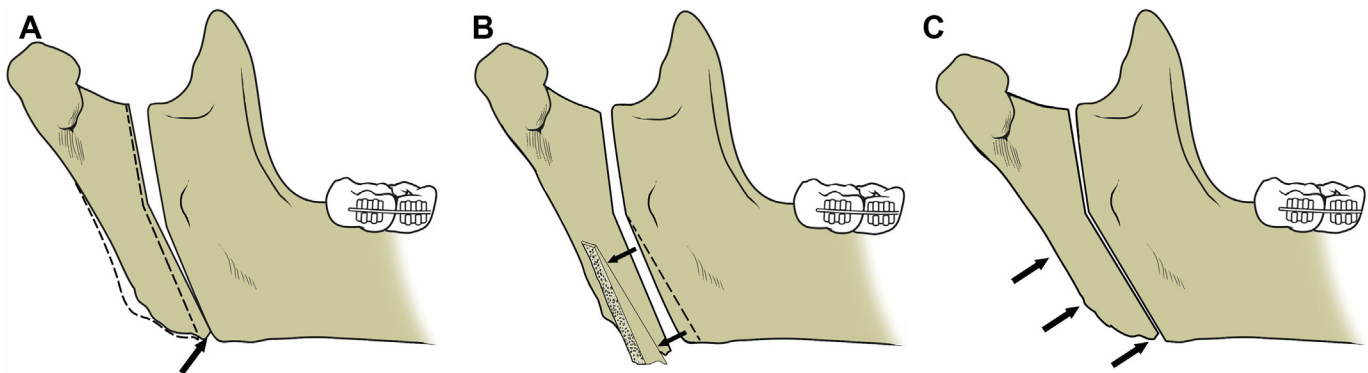
fixation can be established with 2 to 3 positioning screws (see Fig. 8)

### Potential complications

In addition to complications related to preservation of proximal segment medial pterygoid and segment positioning, described earlier, other risks associated with IVRO include nerve injury, bleeding, infection, and fibrous union. Although reported, necrosis of the tip of the proximal segment from stripping of soft tissue is a very rare complication in the authors' experience.<sup>10</sup>

Sensory alteration of the inferior alveolar nerve is uncommon after IVRO, especially compared with SSO.<sup>7,11,12</sup> Post-operative inferior alveolar nerve injury, associated with medial displacement of the proximal segment, occurs in approximately 3% to 8% of cases.<sup>13,14</sup> With medial displacement of the proximal segment, anterior rotation of the proximal segment can compress the inferior alveolar nerve as it enters the mandibular foramen. This event is usually associated with sudden sensory alteration, usually in the first week following surgery. Patients should be advised of this possible complication, and proximal segment repositioning should occur urgently to minimize the risk of long-term neurosensory alteration.

Lingual nerve injury is uncommon during IVRO, but use of a forked ramus stripper to strip temporalis tendon attachment from the anterior border of the ramus may be a source of injury to the lingual nerve. For this reason, the forked ramus stripper should be used cautiously. Injury to the marginal mandibular



**Fig. 7** (A) Premature contact (arrow) at the inferior aspect of the osteotomy. (B) Supplemental distal segment osteotomy (arrow) to relieve premature contact. (C) Forward rotation of the proximal segments and establishment of excellent bone contact with distal segment after relief of interference.

branch of the facial nerve can result with completion of the inferior portion of the osteotomy. The risk of this injury can be minimized with adequate elevation of periosteum at the inferior border such that the oscillating saw has clearance from soft tissue contact.

There are potential sources for profuse bleeding, which can generally be avoided. In particular, the masseteric artery and other branches of the maxillary artery reside medial to the ramus, in close proximity to the osteotomy site. Injury to the inferior alveolar artery, maxillary artery, and the retro-mandibular vein have been reported but are uncommon.<sup>15</sup> Vascular injury can generally be avoided with use of a properly positioned Bauer retractor in the sigmoid notch. Additionally, as noted earlier, the 11.5 × 7-mm blade is preferred, and it should not be used to its full 7-mm depth at the level of the sigmoid notch. Anatomic variations in the relationship of the maxillary artery to the sigmoid notch region have been described, and the risk of vascular injury may be higher in select populations.<sup>16</sup>

Fibrous union following IVRO is uncommon, likely because of the robust blood supply to this area, splinting provided by the muscles that envelope the ramus and a period of immobilization.

Historically, there has been some controversy regarding the stability of IVRO as compared with SSO. Studies have shown no significant difference in horizontal stability and only minor, statistically insignificant difference in vertical stability favoring SSO.<sup>7</sup>

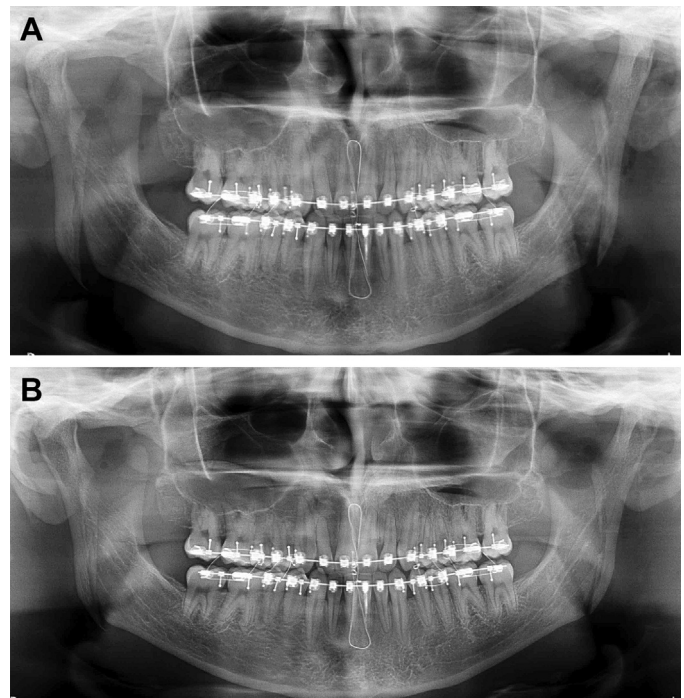
### Immediate postoperative care

Postoperative care should focus on management of pain, swelling, and adequate oral fluid intake. Measures to address swelling include head elevation, ice application, and corticosteroids. Pain is generally controlled with nonsteroidal anti-inflammatory drugs and a brief period of opioid administration, usually 2 to 3 days. Antibiotics are generally stopped after 1 or 2 postoperative doses. Oral intake is facilitated by avoiding the use of a full-coverage final splint. A postoperative panoramic image should be taken to assure satisfactory positioning of the proximal segments. With adequate control of pain and sufficient oral intake, overnight hospitalization is generally unnecessary following IVRO.

### Rehabilitation and recovery

If internal fixation is not used, 2 to 3 weeks of MMF is necessary, followed by 3 to 4 weeks of 22-hours-per-day training elastic use. During the period of training elastic use, patients are limited to a nonchewing diet. During the fourth postoperative week, active range-of-motion exercises are initiated to restore preoperative mandibular range of motion. During the sixth postoperative week, patients may resume a normal diet and begin finishing orthodontic treatments.

If postoperative imaging reveals condylar sag, clenching exercises during the first 2 weeks can effectively restore proper condylar position because of activity of the medial pterygoid and, to a lesser extent, the masseter muscles. Similarly, gaps at the inferior aspect of the osteotomy can also often be addressed with clenching exercises (Fig. 9).



**Fig. 9** (A) Immediate postoperative panoramic image showing inferior border gap. (B) Panoramic image after 2 weeks of clenching exercises showing closure of inferior border gap from muscle activity.

### Summary

IVRO is a straightforward technique, which can be used to perform mandibular setback or rotation about the vertical axis of the ramus. Small advancements are amenable to IVRO with anterior rotation of the proximal segment to establish satisfactory bone contact. Although rigid fixation can be used with IVRO, it often is not and a brief period of MMF is required. Because the position of the proximal segment and optimal condylar seating is dictated by muscle attachments to the proximal segment, it is important to design an osteotomy that maximizes the surface area of the medial pterygoid attachment to the proximal segments. The greater the planned setback, the broader the area of muscle attachment required. Compared with SSO, IVRO is associated with a very low incidence of nerve injury. Further, the authors' experience with modified mandibular condylotomy suggests that, when applied in the setting of symptomatic TMJ internal derangement, IVRO will allow for physiologic positioning of the condyle and should minimize the possibility for exacerbation of joint symptoms or the production of new joint symptoms.

### References

1. Bell WH, Yamaguchi Y, Poor MR. Treatment of temporomandibular joint dysfunction by intraoral vertical ramus osteotomy. *Int J Adult Orthodon Orthognath Surg* 1990;5:9–27.
2. Nickerson JW, Veaco NS. Condylotomy in surgery of the temporomandibular joint. *Oral Maxfac Clin North Am* 1989;4:303–12.
3. Hall HD, Navarro ZE, Gibbs JS. One and three-year prospective outcome study of modified condylotomy for treatment of reducing disc displacement. *J Oral Maxillofac Surg* 2000;58:7–17.
4. Yamauchi K, Takenobu T, Takahashi T. Condylar luxation following bilateral intraoral vertical ramus osteotomy. *Oral Surg Oral Med Oral Pathol Oral Radiol Endod* 2007;104:747–51.

5. Hall HD, Chase DC, Payor LG. Evaluation and refinement of the intraoral vertical subcondylar osteotomy. *J Oral Surg* 1975;33:333–41.
6. Hall HD, McKenna SJ. Further refinement and evaluation of intraoral vertical ramus osteotomy. *J Oral Maxillofac Surg* 1987;45:684–8.
7. Al-Moraissi EA, Ellis E. Is there a difference in stability and sensory function between bilateral sagittal split ramus osteotomy and intraoral vertical ramus osteotomy for mandibular setback? *J Oral Maxillofac Surg* 2015;73(7):1360–71.
8. Ghali GE, Sikes JW Jr. Intraoral vertical ramus osteotomy as the preferred treatment for mandibular prognathism. *J Oral Maxillofac Surg* 2000;58:313–5.
9. Epker BN, Wolford L. Dentofacial deformities: surgical-orthodontic correction. St Louis (MO): Mosby; 1980. p. 58–65.
10. Talesh KT, Motamedi MH, Yazdani J, et al. Prevention of relapse following intraoral vertical ramus osteotomy mandibular setback: can coronoidotomy help? *Oral Surg Oral Med Oral Pathol Oral Radiol Endod* 2011;111:557–60.
11. Westermarck A, Bystedt H, von Konow L. Inferior alveolar nerve function after mandibular osteotomies. *Br J Oral Maxillofac Surg* 1998;36:425–8.
12. Zaytoun HS, Phillips C, Terry BC. Long-term neurosensory deficits following transoral vertical ramus osteotomy and sagittal split osteotomies for mandibular prognathism. *J Oral Maxillofac Surg* 1986;44:193–6.
13. Blinder D, Peleg O, Yoffe T, et al. Intraoral vertical ramus osteotomy: a simple method to prevent medial trapping of the proximal fragment. *Int J Oral Maxillofac Surg* 2010;39:289–91.
14. Tuinzing DB, Greebe RB. Complications related to the intraoral vertical ramus osteotomy. *Int J Oral Surg* 1985;14:319–24.
15. Lanigan DT, Hey J, West RA. Hemorrhage following mandibular osteotomies: a report of 21 cases. *J Oral Maxillofac Surg* 1991;49:713–24.
16. Hara S, Mitsugi M, Kanno T, et al. Risk of maxillary artery injury during an intraoral vertical ramus osteotomy in Japanese patients is high—is it enough just to avoid damaging the inferior alveolar nerve? *J Oral Maxillofac Surg* 2014;72:1373–90.