

# blood

1966 28: 598-601

## Brief Note Nuclear Projections in Neutrophils

K. MÉHES

---

Information about reproducing this article in parts or in its entirety may be found online at:  
[http://bloodjournal.hematologylibrary.org/site/misc/rights.xhtml#repub\\_requests](http://bloodjournal.hematologylibrary.org/site/misc/rights.xhtml#repub_requests)

Information about ordering reprints may be found online at:  
<http://bloodjournal.hematologylibrary.org/site/misc/rights.xhtml#reprints>

Information about subscriptions and ASH membership may be found online at:  
<http://bloodjournal.hematologylibrary.org/site/subscriptions/index.xhtml>



## **Brief Note**

### **Nuclear Projections in Neutrophils**

*By K. MÉHES*

**S**INCE DAVIDSON AND SMITH<sup>1</sup> discovered the sex-specific projections of leukocytes, termed "drumsticks," many attempts have been made to show that other nuclear appendages might also be characteristic of certain conditions. A large number of such appendages have been described under a variety of names. The nomenclature used here is based on Kosenow's formula.<sup>6</sup> Thus drumsticks are called "forms A," sessile nodules are called "forms B," and leukocytes with other pedunculated nuclear projections, which are easily distinguished from lobes and forms A and B such as small clubs, hooks, tags, etc., are designated "forms C."

Harnack and Strietzel<sup>4</sup> were the first to demonstrate that, irrespective of sex, all the 3 forms were more frequent in children than in adults. Since then, the distribution of these projections by age, in inflammatory diseases and leukemia, has been dealt with by many authors without agreement.

Recently Huehns et al.<sup>5</sup> and Powars et al.<sup>12</sup> have shown that the appearance of numerous nuclear projections in the neutrophils is characteristic of the D<sup>13-15</sup> trisomy syndrome. The figures demonstrated by them seem to correspond to what we call forms C.

In previous papers,<sup>7,13</sup> we reported that an increase in the incidence of small clubs and hooks (forms C) could be observed after intensive androgen treatment in the rat and the mouse. This result has led us to the assumption that sex hormones might be implicated in the changes in number of C-chromatins; hence, these forms should not be regarded as sex-specific chromatins.

We also made an attempt to hydrolyze leukocytes with 5 N HCl under the phase-contrast microscope. After staining, most of the hydrolyzed nuclei gave the impression that forms A and B stained more vividly, whereas other nuclear parts and projections remained pale or even unstained. This was interpreted to mean that forms A and B were heterochromatic and that forms C were euchromatic. This, again, would seem to indicate that forms C were no specific bodies of the leukocytes, while drumsticks, and also sessile nodules, might be regarded as the equivalents of sex chromatin. Thus Müller's hypothesis<sup>10</sup> that sessile nodules are preformed drumsticks would also seem to have been confirmed.

Osztovcics and Foher<sup>11</sup> found that the incidence of forms C was below normal in patients with pituitary hypofunction, and above normal in pre-puberty basophilism. According to their conclusion the nuclear configuration of the leukocytes is influenced by the pituitary basophils.

---

*From the Department of Pediatrics, Medical University, Pécs, Hungary.*

*First submitted Feb. 21, 1966; accepted for publication May 24, 1966.*

*KÁROLY MÉHES, M.D.: Department of Pediatrics, University Medical School, Pécs, Hungary.*

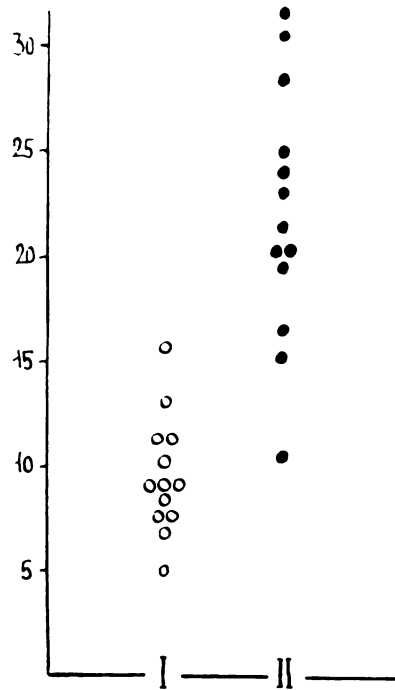


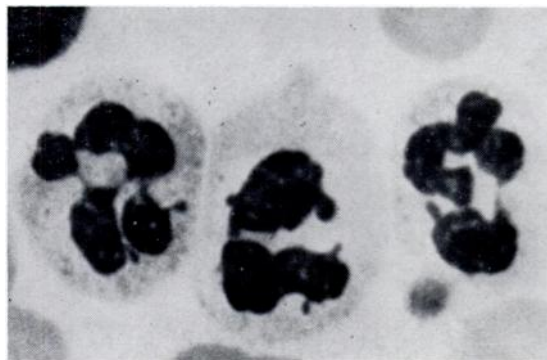
Fig. 1.—Examination results of 13 androgen-treated women (black dots) as compared with untreated controls (white dots). The incidence of forms C proved to be higher in the androgen-treated patients.

The contradictory data in the literature have tempted us to extend our examinations on human leukocytes. Recently, we studied the blood smears of female patients receiving chronic androgen therapy for mammary carcinoma. Since it had been found in control patients that a tumor itself caused no considerable changes in distribution of the nuclear appendages, the fact that the patients were suffering from a malignant tumor was disregarded in this study. The smears were taken after at least 12 weeks of intensive androgen treatment.

Only such patients were considered in whom (1) the total leukocyte count was between 4000–10,000, (2) the qualitative distribution of blood cells was normal, and (3) at least 1000 well-stained, nonshrunken neutrophils could be observed in the smear. Thirteen androgen-treated patients met these requirements. The results are shown in Figure 1.

Compared with untreated controls of the same age, the incidence of forms C (and also the total projection count) showed a significant increase. In addition, in 8 patients the “blackberry-forms” described previously<sup>8</sup> could also be observed.

Simultaneously, the smears of a 23-year-old woman with an androgen-producing tumor of the left adrenal (17-ketosteroid excretion: 380 mg./24 hours) were studied. The neutrophils with small clubs and hook-like appendages averaged 24 per cent (Fig. 2). After the removal of the tumor, the



**Fig. 2.**—Blood-smear of a woman with an androgen-producing tumor of the adrenal. Twenty-four per cent of the neutrophils have one or more nuclear projections.

incidence of forms C decreased to 8 per cent. These observations suggested that the increase in number of nuclear appendages might be a manifestation of a high androgen level in man too.

We have also studied the blood smears of 12 children receiving long-term prednisolone treatment, to which 4 of them responded with a remarkable increase in number of nuclear projections. A large number of forms C (39 per cent) was observed in a girl with an adrenogenital syndrome, but examinations in other patients with this anomaly showed a normal level.

We have seen a patient with 13–15 trisomy<sup>9</sup> and also a newborn with clinical features of this chromosome anomaly. The smears of these two cases were carefully studied. The number of nuclear projections in their leukocytes was slightly above normal, but morphologically the projections did not differ from the appendages seen in other conditions—for example, after androgen treatment. Thus, in agreement with Fine et al.<sup>3</sup> and Erkman et al.,<sup>2</sup> we think that multiple nuclear projections are not specific for the 13–15 trisomy syndrome.

It should be emphasized that no changes in the incidence of forms A (drumsticks) and B (sessile nodules) and of the sex chromatin bodies of buccal epithelial cells were noted in the patients examined.

#### CONCLUSIONS AND SUMMARY

All these findings and the contradictory data in the literature show that the different types of nuclear projections in neutrophils, "excluding the genetically determined drumsticks and sessile nodules, are nonspecific pseudosegments of the leukocytes. Their appearance depends on the segmentation, aging, and metabolism of the neutrophils. These features might be influenced by many factors, including possible hormonal effects. Our observations have shown, for instance, that androgens might induce an increase in the number of nuclear appendages. Although the appearance of these figures may be associated with certain diseases, it should not be regarded as a specific sign for a single pathologic or physiologic condition.

## SUMMARIO IN INTERLINGUA

Es postulate que le differente typos de projectiones trovate in le nucleos de neutrophilos es—con le exception del geneticamente determinate “formas A” e “formas B”—pseudosegmentos leucocytic sin specificitate. Lor apparentia depende del segmentation, del etate del subjecto, e del metabolismo del neutrophilos. Iste characteristics es possibilmente influentiate per numerose factores, incluse possibilmente certe effectos hormonal. Nostre observationes ha monstrate, per exemplo, que androgenos pote inducer un augmento in le numero del projectiones nucleari. Ben que le apparition de iste configurationes es possibilmente associate con certe morbos, illo non pote esser regardate como un signo specific de un specific condition pathologic o physiologic.

## REFERENCES

- Davidson, W. M., and Smith, D. R.: A morphological sex difference in the polymorphonuclear neutrophil leucocytes. *Brit. Med. J.* 2:6, 1954.
- Erkman, B., Basrur, U. R., and Conen, P. E.: D/D translocation D syndrome. *J. Pediat.* 67:270, 1965.
- Fine, R. N., Wang, M. Y. F. W., and Heath, C. W.: Nuclear projections of neutrophils in the 13–15 trisomy syndrome. *Pediatrics* 35:712, 1965.
- Harnack, G. A., and Strietzel, H. N.: Die Altersabhängigkeit der geschlechtsbedingten Leukocytenmerkmale. *Klin. Wschr.* 34:401, 1956.
- Huehns, E. R., Lutzner, M., and Hecht, F.: Nuclear abnormalities of the neutrophils in D<sub>1</sub> (13–15)-trisomy syndrome. *Lancet* 1:589, 1964.
- Kosenow, W., and Scupin, R.: Geschlechtsbestimmung auf Grund morphologischer Leukocytenmerkmale. *Klin. Wschr.* 34:51, 1956.
- Méhes, K., and Jobst, K.: Hormonkezelés hatása a patkány neutrophil leukocytáinak nemi chromatinformáira. *Morph. Ig. Orv. Szle* 2:34, 1962.
- Méhes, K., Zsifkovits, St., and Jobst, K.: Effects of androgens on nuclei of neutrophil leucocytes. *Lancet* 2:1198, 1960.
- Méhes, K., and Bata, G.: Congenital thrombocytopenia in 13–15 trisomy syndrome. *Lancet* 1:1279, 1965.
- Müller, D.: Zur Entwicklung der geschlechtsspezifischen sogenannten Drumsticks an segmentkernigen Leukocyten. *Ärztliche Wschr.* 14:260, 1959.
- Osztovics, M., and Focher, L.: The nuclear configuration of leucocytes in males in prepuberty. *Acta Paediat. Acad. Sci. Hung.* 5:83, 1964.
- Powars, D., Rohde, R., and Graves, D.: Foetal haemoglobin and the neutrophil anomaly in the D<sub>1</sub>-trisomy syndrome. *Lancet* 1:1363, 1964.
- Zsifkovits, St., Méhes, K., and Jobst, K.: Effect of sexual maturation and castration on the sex chromatin pattern in the male rat. *Nature* 184:1239, 1959.