



Full Length Article

Timing of dental development in osteogenesis imperfecta patients with and without bisphosphonate treatment



Ilkka Vuorimies^{a,b}, Heidi Arponen^c, Helena Valta^b, Outi Tiesalo^c, Marja Ekholm^c, Helena Ranta^d, Marjut Evälahti^c, Outi Mäkitie^{a,b,e,f,*}, Janna Waltimo-Sirén^{b,c}

^a Folkhälsan Institute of Genetics, Helsinki, Finland

^b Children's Hospital, University of Helsinki, Helsinki University Hospital, Helsinki, Finland

^c Department of Oral and Maxillofacial Diseases, University of Helsinki, Helsinki, Finland

^d Forensic Dentistry, Department of Forensic Medicine, University of Helsinki, Helsinki, Finland

^e Department of Molecular Medicine and Surgery, Center for Molecular Medicine, Karolinska Institutet, Stockholm, Sweden

^f Department of Clinical Genetics, Karolinska University Hospital, Stockholm, Sweden

ARTICLE INFO

Article history:

Received 16 February 2016

Revised 11 July 2016

Accepted 6 October 2016

Available online 07 October 2016

Keywords:

Bisphosphonate

Osteoclast

Pediatrics

Fracture

Pharmacology

ABSTRACT

Bisphosphonates have established their role as medical therapy for pediatric osteogenesis imperfecta (OI) patients. Since bisphosphonates have also been shown to delay tooth development in animal models, we aimed to assess whether the medication has a similar effect on children with OI. In this cross-sectional study, bisphosphonate-treated OI patients of whom dental panoramic tomograph was taken between 3 and 16 years of age formed the study group. The patients, 22 in total, had been treated with pamidronate, zoledronic acid or risedronate for at least one year before the radiography. Developmental stage of the permanent teeth, resorption of the deciduous teeth, and number of the erupted permanent teeth were radiographically assessed in the left mandibular quadrant. Dental panoramic tomographs of 50 OI patients, naïve to bisphosphonates, and of 50 healthy individuals of the same age were used as controls. The dental development was statistically significantly accelerated in the OI group naïve to bisphosphonates showing median advancement of dental age by 0.63 years from chronological age and median increase in the number of erupted teeth by 0.31 as compared to Finnish norms. Bisphosphonate-treated OI patients displayed, however, age-appropriate dental development. The OI patients not treated with bisphosphonates also showed statistically significantly faster resorption of the deciduous teeth than the treated ones, and displayed an altered interrelationship between the resorption stage of an individual primary tooth and the developmental stage of the succedaneous permanent tooth, unlike the OI patients treated with bisphosphonate. No correlation between either cumulative bisphosphonate dose or between treatment length and any measured component of the dental development was found. To conclude, OI itself was found to lead to advanced dental development. Bisphosphonate treatment had a delaying effect in all the three aspects studied, resulting in a rate of dental development indistinguishable from normal.

© 2016 Published by Elsevier Inc.

1. Introduction

Osteogenesis imperfecta (OI) is an inherited disorder characterized by bone fragility and skeletal deformities [1]. In the great majority of the cases, OI is caused by a mutation in one of the two genes encoding type I collagen (*COL1A1*, *COL1A2*). During the past years, mutations in several other genes have also been identified to cause OI. These genes code for proteins that take part in the posttranslational modification of type I collagen, folding, and osteoblast development [2].

In addition to skeletal features, the typical manifestations of OI include blue sclerae, hearing loss, excess joint laxity, growth deficiency, and bone pain. Dental anomalies, such as structural abnormality of dentin and hypodontia, are also prevalent. In fact, only 22% of the patients with OI have been reported not to have any detectable dental abnormalities [3]. Malocclusion is also much more frequent and severe in patients with OI than in their unaffected peers [4].

Bisphosphonates have established their role as medical treatment of pediatric OI patients and are generally well tolerated. Their main mechanism of action is inhibition of osteoclast function and bone resorption. Eruption of any tooth requires resorption of the alveolar bone, and in question of permanent teeth other than molars, also resorption of the roots of the pre-existing primary teeth. Since osteoclasts are responsible for the resorption of both, bisphosphonate treatment can be anticipated

* Corresponding author at: Folkhälsan Institute of Genetics, P.O. Box 63, University of Helsinki, Helsinki FIN-00014, Finland.

E-mail address: outi.makitie@helsinki.fi (O. Mäkitie).

to delay tooth eruption. This phenomenon has been documented in rats treated with zoledronic acid or alendronate [5–7]. There are also data suggesting that locally administered ibandronate retards orthodontic tooth movement in rabbits [8]. Evidence for similar effects in humans is sparse, only one study showing a reduced number of clinically erupted teeth in bisphosphonate-treated patients with OI in comparison to healthy children [9].

The purpose of the present study was to examine if the timing of dental development in children with OI differs from normal, and to obtain information on the effect of therapeutic doses of bisphosphonates on the timing of human dental development. We analyzed the dental development from three aspects: 1) development of the permanent teeth 2) resorption of the primary teeth, and 3) eruption of the permanent teeth. The study subjects were children with OI who had received bisphosphonate treatment. To control the effect of bisphosphonates separately from OI itself, we compared the findings with two types of controls: 1) a historical group of children with OI who were not treated with bisphosphonates, and 2) a group of healthy children of the same ethnicity.

2. Subjects and methods

2.1. Study subjects

The study group comprised children and adolescents with OI, treated at the Children's Hospital, Helsinki University Hospital. The patients were eligible for inclusion if they were aged between 3 and 16 years, and if they had been treated with bisphosphonates for a minimum period of one year. The upper age limit was set at 16 years, before anticipated completion of dental development, third molars excluded. Altogether 39 patients (24 boys, 15 girls) fulfilled these criteria and they were contacted by mail and phone. Of them, 17 (9 boys, 8 girls) gave a written informed consent to participation in clinical evaluation and radiography; one of them was not able to follow the study protocol because of current health problems and was excluded from the final data analyses. The study patients were examined by a dentist (H.A.) in 2013, and a dental panoramic tomograph (DPT) was obtained if one was not available from the previous 3 years (12 patients). In addition, DPTs, taken within 3 years, were available for 6 patients (4 boys and 2 girls) who did not take part in the clinical evaluation, and these were included in the analysis.

The final study group thus comprised 22 patients (13 boys, 9 girls) from 20 families. The type of OI was classified according to Sillence et al. [10]. Of the patients 16 had type I, five type III, and one type IV OI. Presence of dentinal abnormality, often referred as type I dentinogenesis imperfecta, was assessed using clinical and radiographic criteria [11].

All patients in the study group had been treated with at least one bisphosphonate preparation and for more than one year at the time of the radiography. The used bisphosphonates were intravenous pamidronate and zoledronic acid as well as orally administered risedronate. The dosing was 9 mg/kg/year, divided in 3–6 three-day infusion cycles

depending on the age, for pamidronate, and 0.05 mg/kg every six months for zoledronic acid. The risedronate oral dose was 2.5 mg daily for patients who weighted 10–30 kg and 5 mg/day for patients who weighted over 30 kg. All medication data were collected from clinical records to calculate the cumulative dose per body weight, expressed as mg/kg. Because of the differing molecules, we used coefficients also to sum up the cumulative doses of different bisphosphonates. The coefficients were based on relative potencies of the molecules to *in vitro* inhibit bone resorption. They were 100 for pamidronate, 10,000 for zoledronic acid, and 2000 for risedronate [12]. The bioavailability of orally administered risedronate (0.63%) was also taken into account (Table 1).

The non-participants (n = 17) did not differ significantly from the study group by gender, age or OI type ($p > 0.05$). The reasons for non-participation were lack of interest, lack of time, and long distance to study center.

2.2. Control groups

A historical OI control group comprised 50 children with OI of whom DPT had been taken (Table 2). They were born between 1966 and 2002 in 48 families living in Finland. Of them 47 had not received bisphosphonates because their use in the treatment of OI did not start before 2000 in Finland. Of these children 30 had type I, eight type III, and nine type IV OI. Three boys with type I OI, born between 1990 and 2002, had not received the medication because diagnosis of OI had not been made before the time of the radiography or because of a mild phenotype. Data for two OI control patients were also included in the OI study group after the onset of their bisphosphonate treatment.

Another control group comprised randomly chosen 50 healthy children from the records of Helsinki Longitudinal Growth Study at the Institute of Dentistry, University of Helsinki [13]. From the series of DPTs taken on all participating children for analysis of normal childhood and adolescence growth and craniofacial development, we used DPTs that had been taken at ages ranging from 4.6 to 13.6 years (Table 2).

The study protocol was approved by the Research Ethics Committee, Children's Hospital, Helsinki University Hospital, and the Ethics Committee of the Institute of Dentistry, University of Helsinki. The study confirms to STROBE (STrengthening the Reporting of OBServational studies in Epidemiology) guidelines.

2.3. Radiographic analyses

All radiographic analyses were performed using DPTs. The radiographs of the study group were analyzed together by authors I.V. and H.A. The radiographs of the OI control group and healthy controls were evaluated by H.A. Blinding was not possible since most of the study group's DPTs were recent and in digital format, whereas the vast majority DPTs of untreated OI patients as well as all of the healthy controls were in film format. Moreover, blinding between the historical OI group and group of healthy controls was not undertaken since they were radiologically distinguishable by the dentinal abnormality, frequently present in subjects with OI.

Table 1
Description of the study group. Results are given as median (range).

	OI type I	OI type III & IV	Total
Number of subjects	16 (73%)	6 (27%)	22
Gender (boys/girls)	10/6	3/3	13/9
Abnormal dentin (yes/no)	1/15	4/2	5/17
Age at the time of imaging (y)	10.2 (4.8–15.7)	10.1 (3.9–14.3)	10.2 (3.9–15.7)
Age at treatment onset (y)	6.4 (1.2–13.0)	2.1 (0.1–11.8)	6.2 (0.1–13.0)
Time from treatment onset (y)	4.7 (1.1–8.3)	4.8 (1.3–10.2)	4.7 (1.1–10.2)
Cumulative BP dose ^a	2000 (900–5250)	2900 (1500–6750)	2000 (900–6750)

^a Cumulative bisphosphonate dose was calculated as (total dose received [mg]/weight [kg]) multiplied by the relative potency of the medication. OI, osteogenesis imperfecta; BP, bisphosphonate.

Table 2

Description of the control groups. Results are given as median (range). OI, osteogenesis imperfecta.

	OI controls			Healthy controls
	OI type I	OI type III & IV	Total	
Number of subjects	33 (66%)	17 (34%)	50	50
Gender (boys/girls)	20/13	6/11	26/24	20/30
Abnormal dentin (yes/no)	6/27	13/4	19/31	0
Age at the time of imaging (y)	7.5 (3.9–15.6)	7.2 (3.1–13.7)	7.4 (3.0–15.6)	8.6 (4.6–13.6)

The dental age assessment was performed using the method introduced by [14] and weighted norms for Finnish boys and girls [15]. The method determines dental age by evaluating the radiographic appearance of seven permanent left mandibular teeth, supplemented by the corresponding right side tooth if one of the index teeth was missing or could not be evaluated for any reason. In short, based on the progression of the mineralization of each index tooth, the method recognizes eight stages (A–H) where A corresponds to mineralization of the cusp tips and H marks a fully developed tooth. The dental development was considered notably delayed or advanced if it differed from the chronological age by more than twelve months.

The stage of resorption of primary teeth was assessed based on a method described by Haavikko [16]. We analyzed the five primary teeth in the left mandibular quadrant, and modified the method into a simpler form in which the stage of resorption was divided into four categories by the length of the root, and each tooth was scored accordingly: 1 = full root present, 2 = a quarter of the root resorbed, 3 = half of the root resorbed, and 4 = the root completely resorbed (Fig. 1). If a primary tooth had already exfoliated, it was scored as 4. The scores were summed up to form a resorption sum score, ranging from 5 to 20.

The two analyses above were combined to assess the relationship between the resorption stage of an individual primary tooth and the developmental stage of the succedaneous permanent tooth.

Radiographic assessment of the permanent tooth eruption, defined as alveolar eruption, also included the left mandibular teeth. A tooth was considered emerged if it had pierced the alveolar bone cortex, whether or not it had pierced the oral mucosa. As reference values we used published norms for timing of tooth eruption in healthy Finnish children [13]. The timing of tooth eruption was considered abnormal if outside the 5th or 95th percentile.

2.4. Statistical analyses

We assessed the intra-examiner error between duplicated evaluations of dental age using Dahlberg's formula. The intra-examiner error was 0.34 years which is 3.1% of the mean corresponding measurement. Thus, we considered the intra-examiner error acceptable. Wilcoxon rank-sum test was used to evaluate the difference between the chronological age and the calculated dental age within both OI groups, and

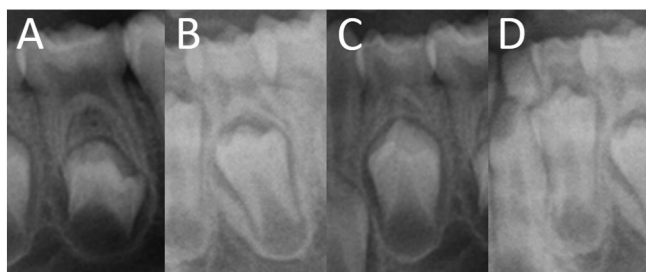


Fig. 1. Resorption stages of primary teeth. Resorption stages from left to right: A) full root present, B) a quarter of the root resorbed, C) half of the root resorbed, D) the root completely resorbed. The developing permanent premolars are seen under the primary molars and represent here Demirjian stages D in (A), E in (C), and F in (B, D). Thus, the developmental stage of the permanent tooth and the resorption stage of the above-lying primary tooth are not completely inter-related.

Mann-Whitney-*U* test to evaluate the differences between the groups. Wilcoxon rank-sum test was also used to test if the number of erupted permanent teeth in the OI groups differed from reported normal values. Mann-Whitney-*U* test was again used to evaluate the differences between the groups. Analysis of variance (ANOVA) was applied, using age as a covariate, to compare the stage of primary tooth root resorption between the groups. Spearman's correlation coefficient was used to determine the correlation between relative cumulative dose or duration of bisphosphonate treatment and above-mentioned outcome variables. *p* values <0.05 were considered statistically significant. Statistical calculations were carried out using SPSS software for Windows (version 22; SPSS Inc., Chicago, IL, USA).

3. Results

In the study group of 22 bisphosphonate-treated children with OI, the median difference between the patient's dental age and chronological age was +0.20 years (−1.49–+3.89, SD 1.26), and the difference was statistically non-significant (*p* = 0.23). In the OI control group of 50 children that had not received bisphosphonates the dental development was, however, accelerated – the median advancement was 0.63 years (−2.03–+3.77, SD 1.24), and the difference between dental and chronological age was statistically significant (*p* < 0.001). The two OI groups did not, however, differ from each other statistically significantly (*p* = 0.21) with respect to the acceleration of dental development.

The resorption sum scores for primary teeth were statistically significantly different between the three groups when age was used as a covariate (*p* = 0.042). The resorption was faster in the OI patients not treated with bisphosphonates than in the treated ones (*p* = 0.036). The difference was, however, statistically non-significant when either treated or untreated patients were compared to healthy controls (*p* = 0.23 and *p* = 0.62, respectively).

In the bisphosphonate-treated OI patients and healthy controls root resorption in the primary tooth never began until the crown of the underlying permanent tooth was complete (Demirjian stage D), whereas the resorption started earlier in 27% of the teeth in the historical OI group that had not received bisphosphonates (Fig. 2).

As a marker of permanent tooth eruption we counted the number of left mandibular permanent teeth that had radiographically pierced the alveolar bone. When this number in the bisphosphonate-treated OI group was compared to age-appropriate Finnish norms [13], the average difference was 0.05 (−2–+2, SD 0.18, *p* = 0.80) and hence statistically non-significant. The number of erupted teeth was, however, significantly higher in the untreated OI subjects than in the Finnish norms, the difference being 0.31 (−3–+3, SD 0.97, *p* = 0.029). The two OI groups did not differ significantly from each other (*p* = 0.23). The tooth count was above the 95th percentile of age-dependent reference values in 2 patients (9.0%) in the OI study group and 5 patients (10.0%) in the OI control group but it was not markedly low in any of the patients in either group.

The acceleration within dental age and eruption of permanent teeth seemed to be even more pronounced in the subgroup of OI patients with dental abnormality (Table 3). The differences between the subgroups of OI patients with and without dental abnormality were, however, non-significant (*p* = 0.19 and *p* = 0.08, respectively). The

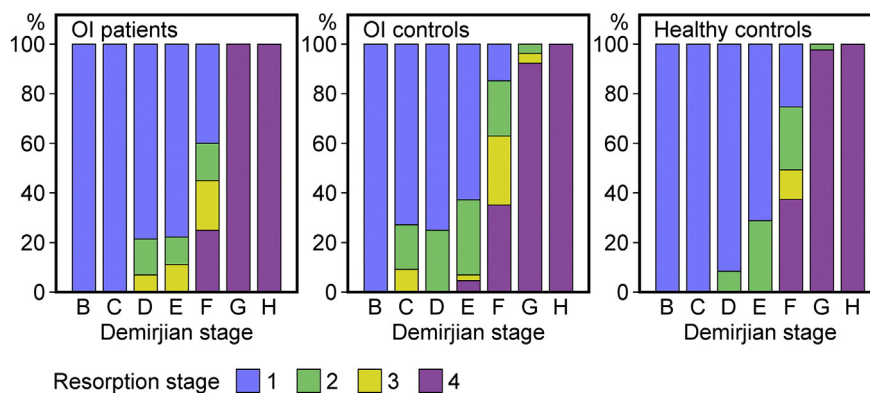


Fig. 2. Relationship between Demirjian stage of the permanent tooth and resorption stage of the deciduous tooth above it. For instance, when the permanent tooth had reached stage F (root higher than crown) the primary tooth above could show any stage of resorption from full root left to completely resorbed in all subject groups analyzed, but the resorption was more advanced in the OI patients who had not received bisphosphonates than in those who had been treated with bisphosphonates. Permanent teeth representing Demirjian stage A (initiation of the mineralization) were few and were left out from the graph.

presence of dentinal abnormality could not be found to significantly affect the rate of resorption of primary teeth.

The median time elapsed from the onset of bisphosphonate treatment to the time of radiography was 4.7 years (1.1–10.2). Neither treatment time nor relative cumulative dose correlated with the rate of dental development, resorption of primary teeth or eruption of permanent teeth ($p > 0.05$).

4. Discussion

Our study revealed that OI patients, naïve to bisphosphonates, have on average advanced dental development. As compared to healthy peers they showed acceleration in both dental age and eruption of the permanent teeth. Against this background, we were able to show, in line with our expectations and observations in animal studies, that bisphosphonates slow down dental development in humans as well, and as a new finding, we also demonstrate statistically significant delay in the resorption of primary teeth. Clinically importantly, however, the overall delay due to bisphosphonates is likely to rescue the accelerated dental development in patients with OI to a level comparable to unaffected children.

The results confirm our long-term clinical impression that especially in children with more severe types of OI it used to be common in the era before bisphosphonate treatment to see relatively early shedding of the primary teeth and replacement by permanent incisors, canines and premolars as well as eruption of the permanent molars particularly in the lower jaw. Children with OI often need extensive and complicated dental care, such as protection of teeth with abnormal dentin with stainless steel crowns or orthodontic treatment. Such treatments are easier to perform in a more mature, co-operative child, and therefore early dental development can be considered a disadvantage.

This observation on statistically significantly advanced dental development in OI is new and has not been reported in the very few previous studies focusing on dental development in OI. Malmgren and Norgren [3] reported that in 1 out of 68 patients the clinical tooth eruption was delayed, and the deviant observation concerned a child in primary tooth stage. Of their patients 32 were 5–14 year-olds and none of

them exhibited abnormal timing of tooth eruption as compared to published population norms. O'Connell and Marini [17] reported that in 40 children, with either type III or IV OI, clinical tooth eruption was within normal range for both the primary and permanent teeth for most patients. They similarly applied Demirjian method [14] to assess dental age in a subset of 27 children for whom DPTs could be obtained, ending up with a result that in 5 patients the dental age was accelerated and in 4 patients delayed by > 12 months compared to the chronological age.

To the best of our knowledge there is only one published study considering the effect of bisphosphonates on dental development in patients with OI, published by Kamoun-Goldrat et al. [9]. The study setting was notably different from ours in that only unaffected children were used as controls and that the assessment of dental age was based on the number of erupted permanent teeth, as evaluated by visual inspection. Since the tooth count was statistically significantly lower in the bisphosphonate-treated children with OI than in the matched healthy controls, the authors concluded that bisphosphonates lead to delayed eruption of permanent teeth. Yet, in lack of radiographic data, numbers were not corrected for congenitally missing or impacted teeth. The prevalence of hypodontia in patients with OI is about 20% [18], and impaction of particularly the upper second permanent molars is frequent due to lack of space and bulbous crowns [3]. Thus the calculated dental age in subjects with OI was most probably markedly underestimated.

During tooth eruption osteoclasts resorb the above-lying alveolar bone while osteoblasts form new bone at the base of the tooth, causing thereby an intra-osseous movement of the tooth towards the oral cavity [19], and the dental follicle has a decisive role in induction and regulation of these cells [20]. The importance of the role of these two cell types for dental eruption is of particular interest in patients with OI, because both osteoclastic and osteoblastic activities are characteristically accelerated in the disorder [21]. We suggest that the accelerated bone turnover might be the reason for the advanced development and eruption of permanent teeth in medically unmodified OI.

The suppressed activity of osteoclasts by bisphosphonates probably affects tooth development in a diverse pattern. Indeed, our study showed no general difference between the rate of development of the

Table 3
Results when all subjects with osteogenesis imperfecta were subgrouped according to bisphosphonate (BP) treatment and dentinal abnormality (DI). Results are given as mean (range).

	n	Difference between dental and chronological ages (y)	p-Value	Difference between number of erupted teeth and reference values	p-Value
BP +/DI -	17	+0.37 (-1.49+3.89)	0.47	-0.18 (-2+1)	0.32
BP +/DI +	5	+0.43 (-1.17+1.46)	0.35	+0.80 (0+2)	0.10
BP -/DI -	31	+0.58 (-2.03+3.77)	<0.01	+0.29 (-3+3)	0.19
BP -/DI +	19	+0.93 (-1.43+3.77)	<0.01	+0.42 (-1+2)	0.03
Total/DI -	48	+0.51 (-2.03+3.89)	0.01	+0.13 (-3+3)	0.39
Total/DI +	24	+0.82 (-1.43+3.77)	0.04	+0.50 (-1+2)	<0.01

permanent dentition in bisphosphonate-treated OI-patients and healthy individuals. Thus it seemed that bisphosphonate treatment at least at these therapeutic doses normalized the otherwise accelerated tooth development in children with OI. Nevertheless, bisphosphonates have other medical indications in pediatrics, such as glucocorticoid-induced juvenile osteoporosis [22], and a bisphosphonate-induced delay in dental development in patient groups other than OI is a concern. In an experimental mouse study, high doses of zoledronic acid, mimicking its potential therapeutic use in children and adolescents with osteosarcoma, impaired tooth development and eruption severely and irreversibly [23]. All in all, the severity of adverse effects on tooth development and eruption are likely to be dose-dependent and particularly harmful to the teeth with ongoing root formation at the time of the delivery of the medication. Third molars included, this would indicate that all patients under the age of 23 [24], with current or previous bisphosphonate treatment, should be followed up clinically and radiographically by dental specialists.

The resorption of the roots of the primary teeth is a crucial part of eruption of most permanent teeth as well. The cells responsible for that are osteoclasts, as with bone [25], and the control of these cells is mostly similar to the cells resorbing bone. For instance, RANKL (receptor activator of nuclear kappa B ligand) and osteoprotegerin (OPG) have similar effects on both osteoclast groups [26]. In contrast, parathyroid hormone affects the resorption of teeth and bone differently. It has been hypothesized that the difference is rather caused by cementoblasts covering the root and preventing osteoclastic resorption of the root [27]. Here we demonstrated a delaying effect of bisphosphonates on the resorption of primary teeth, indicating similar effects on both groups of osteoclasts. The effect of bisphosphonate on tooth resorption has not been evaluated in animal studies and the delayed resorption is therefore a completely new finding, albeit not unexpected. Clinically, an unorchestrated primary tooth resorption aggravates the effect of delayed permanent tooth development and is likely to increase the need of primary tooth extractions and follow-up of tooth eruption and occlusal development.

The limitations of this study include the fact that this is an uncontrolled cross-sectional study and the control groups consist of historical patients and healthy subjects. Differences other than medical treatment may therefore exist in the clinical management of the OI groups. The groups were also not identical. The impact of age was minimized using reference values, and using age as a co-variant only when essential. The lack of blinding of the investigators to the subjects' age was considered to have little effect on the analysis outcome as was shown by the results of the method error calculation. The fairly small number of patients did not allow us to statistically compare the effects of the different bisphosphonate preparations or types of OI. The statistical analyzes were hallmarked by notable inter-individual variation in the timing of dental development in both OI groups. Further studies with larger populations and from a longitudinal aspect are likely to show whether a delay in dental development in some individuals will reach clinical significance and whether one developmental stage more than the other is sensitive to the delaying effects of the medication.

In conclusion, the present study shows that children with OI are on average advanced in terms of dental development. It also shows that bisphosphonate treatment delays dental development in patients with OI. As a net effect, bisphosphonate treatment is not associated with elevated risk of abnormalities in the timing of secondary dentition in this patient group. We recommend, however, regular dental evaluations of pediatric OI patients regardless of the medication because of the frequent dental aberrations associated with OI.

Acknowledgements

This study was financially supported by the Sigrid Jusélius Foundation, the Foundation for Pediatric Research, the Academy of Finland

(#277843), the Folkhälsan Research Foundation, the Finnish Dental Society and its Orthodontic Section, the Swedish Research Council (#2013-2603), the Novo Nordisk Foundation, and a grant from the special governmental subsidy for health sciences research, Helsinki, Finland. We also thank RN Eira Leino and RDN Anneli Sinkkonen for their help in practical arrangements. The authors declare no potential conflicts of interest with respect to the authorship and/or publication of this article.

References

- [1] F. Rauch, F.H. Glorieux, Osteogenesis imperfecta, *Lancet* 363 (9418) (2004) 1377–1385.
- [2] J.C. Marini, A.R. Blissett, New genes in bone development: what's new in osteogenesis imperfecta, *J. Clin. Endocrinol. Metab.* 98 (8) (2013) 3095–3103.
- [3] B. Malmgren, S. Norgren, Dental aberrations in children and adolescents with osteogenesis imperfecta, *Acta Odontol. Scand.* 60 (2) (2002) 65–71.
- [4] J. Rizkallah, S. Schwartz, F. Rauch, F. Glorieux, D.D. Vu, K. Muller, J.M. Retrouvey, Evaluation of the severity of malocclusions in children affected by osteogenesis imperfecta with the peer assessment rating and discrepancy indexes, *Am. J. Orthod. Dentofac. Orthop.* 143 (3) (2013) 336–341.
- [5] V. Bradaschia-Correa, L.F. Massa, V.E. Arana-Chavez, Effects of alendronate on tooth eruption and molar root formation in young growing rats, *Cell Tissue Res.* 330 (3) (2007) 475–485.
- [6] R.L. Grier 4th, G.E. Wise, Inhibition of tooth eruption in the rat by a bisphosphonate, *J. Dent. Res.* 77 (1) (1998) 8–15.
- [7] T. Hiraga, T. Ninomiya, A. Hosoya, H. Nakamura, Administration of the bisphosphonate zoledronic acid during tooth development inhibits tooth eruption and formation and induces dental abnormalities in rats, *Calcif. Tissue Int.* 86 (6) (2010) 502–510.
- [8] V. Venkataramana, S.S. Kumar, B.V. Reddy, A.S. Cherukuri, K.R. Sigamani, G. Chandrasekhar, Administration of bisphosphonate (ibandronate) impedes molar tooth movement in rabbits: a radiographic assessment, *J. Pharm. Bioallied Sci.* 6 (Suppl. 1) (2014) S165–S170.
- [9] A. Kamoun-Goldrat, D. Ginisty, M. Le Merrer, Effects of bisphosphonates on tooth eruption in children with osteogenesis imperfecta, *Eur. J. Oral Sci.* 116 (3) (2008) 195–198.
- [10] D.O. Silience, A. Senn, D.M. Danks, Genetic heterogeneity in osteogenesis imperfecta, *J. Med. Genet.* 16 (2) (1979) 101–116.
- [11] P.-L. Lukinmaa, H. Ranta, K. Ranta, I. Kaitila, Dental findings in osteogenesis imperfecta: I. Occurrence and expression of type I dentinogenesis imperfecta, *J. Craniofac. Genet. Dev. Biol.* 7 (2) (1987) 115–125.
- [12] N.J. Shaw, N.J. Bishop, Bisphosphonate treatment of bone disease, *Arch. Dis. Child.* 90 (5) (2005) 494–499.
- [13] M. Nystrom, E. Kleemola-Kujala, M. Evalahti, L. Peck, M. Kataja, Emergence of permanent teeth and dental age in a series of Finns, *Acta Odontol. Scand.* 59 (2) (2001) 49–56.
- [14] A. Demirjian, H. Goldstein, J.M. Tanner, A new system of dental age assessment, *Hum. Biol.* 45 (2) (1973) 211–227.
- [15] N. Chaillet, M. Nystrom, M. Kataja, A. Demirjian, Dental maturity curves in Finnish children: Demirjian's method revisited and polynomial functions for age estimation, *J. Forensic Sci.* 49 (6) (2004) 1324–1331.
- [16] K. Haavikko, The physiological resorption of the roots of deciduous teeth in Helsinki children, *Proc. Finn. Dent. Soc.* 69 (3) (1973) 93–98.
- [17] A.C. O'Connell, J.C. Marini, Evaluation of oral problems in an osteogenesis imperfecta population, *Oral Surg. Oral Med. Oral Pathol. Oral Radiol. Endod.* 87 (2) (1999) 189–196.
- [18] P.-L. Lukinmaa, H. Ranta, K. Ranta, I. Kaitila, J. Hietanen, Dental findings in osteogenesis imperfecta: II. Dysplastic and other developmental defects, *J. Craniofac. Genet. Dev. Biol.* 7 (2) (1987) 127–135.
- [19] G.E. Wise, H. He, D.L. Gutierrez, S. Ring, S. Yao, Requirement of alveolar bone formation for eruption of rat molars, *Eur. J. Oral Sci.* 119 (5) (2011) 333–338.
- [20] S.C. Marks Jr., D.R. Cahill, Experimental study in the dog of the non-active role of the tooth in the eruptive process, *Arch. Oral Biol.* 29 (4) (1984) 311–322.
- [21] F. Rauch, R. Travers, A.M. Parfitt, F.H. Glorieux, Static and dynamic bone histomorphometry in children with osteogenesis imperfecta, *Bone* 26 (6) (2000) 581–589.
- [22] O. Makitie, Causes, mechanisms and management of paediatric osteoporosis, *Nat. Rev. Rheumatol.* 9 (8) (2013) 465–475.
- [23] F. Lézot, J. Chesneau, S. Battaglia, R. Brion, B. Castaneda, J.-C. Farges, D. Heymann, F. Rédini, Preclinical evidence of potential craniofacial adverse effects of zoledronic acid in pediatric patients with bone malignancies, *Bone* 68 (2014) 146–152.
- [24] S.J. AlQahtani, M.P. Hector, H.M. Liversidge, The London atlas of tooth development and eruption, *Am. J. Phys. Anthropol.* 142 (3) (2010) 481–490.
- [25] T. Sasaki, Differentiation and functions of osteoclasts and odontoclasts in mineralized tissue resorption, *Microsc. Res. Tech.* 61 (6) (2003) 483–495.
- [26] J.C. Tiffée, L. Xing, S. Nilsson, B.F. Boyce, Dental abnormalities associated with failure of tooth eruption in src knockout and op/op mice, *Calcif. Tissue Int.* 65 (1) (1999) 53–58.
- [27] S. Lindskog, L. Blomlof, L. Hammarstrom, Comparative effects of parathyroid hormone on osteoblasts and cementoblasts, *J. Clin. Periodontol.* 14 (7) (1987) 386–389.