



Concomitance of atherosclerotic lesions in arteries of the lower extremities and carotid arteries in patients with abdominal aorta aneurysm



Piotr Kaźmierski ^{a,*}, Michał Pająk ^a, Katarzyna Bogusiak ^b

^a Department of Vascular, General and Oncological Surgery, Copernicus Memorial Hospital, Lodz, Poland

^b Craniomaxillofacial and Oncological Surgery Ward, University Teaching Hospital No 1 in Lodz, Kopcińskiego 22, 90-153 Lodz, Poland

Received 23 March 2016; received in revised form 5 August 2016; accepted 15 August 2016

KEYWORDS

Abdominal aorta aneurysm;
Atherosclerosis;
Carotid arteries stenosis

Abstract Atherosclerosis was considered the main cause of abdominal aorta aneurysms. Many researchers suggest the presence of the association between these two entities. The aim of this paper was to evaluate the presence of atherosclerosis in the aorta and the arteries of the lower extremities, as well as stenoses and occlusions of carotid arteries in patients with abdominal aorta aneurysm.

One-hundred and eighty patients with abdominal aorta aneurysm (23 women and 157 men), aged 50–86 years old (mean 67.28 ± 9.95) were qualified for the study. Each patient had ultrasound of abdominal aorta, arteries of the lower extremities and extracranial carotid arteries. The patients were divided into two groups: A – isolated abdominal aorta aneurysm (AAA-92 patients), B – AAA with atherosclerotic lesions in the abdominal aorta and/or the arteries of the lower extremities (88 patients), in which four different localizations of atherosclerotic lesions were distinguished.

The statistically significant differences between the groups were observed in the prevalence of carotid arteries stenosis (CCA + ICA). No correlation was found between the aneurysm diameter and the stenosis grade of the extracranial segments of the carotid arteries.

The presented results confirm the common occurrence of atherosclerotic lesions in aorta and/or arteries of the lower extremities and carotid arteries in patients with abdominal aorta

* Corresponding author. Kolarska 87, 94-125 Łódź, Poland. Fax: +48 42 689 52 42.
E-mail address: ave151@wp.pl (P. Kaźmierski).

aneurysm, yet their etiology is different. Such patients represent a heterogeneous group in respect to the presence of carotid arteries stenoses.

© 2016 Association for Research into Arterial Structure and Physiology. Published by Elsevier B.V. All rights reserved.

Introduction

Atherosclerosis was for many years considered the main cause for the formation of abdominal aorta aneurysms.¹ According to the theory, which prevailed until recently, the basic role in the pathological aortic dilatation was attributed to the aging of the blood vessels. Such assumption was supported by clinical observation of patients with chronic aortic diseases and the examinations of pathologically changed vessels' segments. The stiffness of atherosclerotic aorta and processes taking place in its wall were to play the fundamental role in its degeneration and strength reduction. One of the rationales for such observation was the common presence of atherosclerotic plaques in the intima of the aortic aneurysm. Their formation and evolution were considered to influence the natural course of the aneurysm leading to the weakening of the wall and raising the risk of rupture.² An association between the raised elastase activity and elastin degradation and the severity of atherosclerotic plaque formation was suggested.^{3,4} The above mentioned phenomena led to the development of the atherosclerotic theory of abdominal aorta aneurysm formation.^{5,6} The studies carried out in the recent years did not, however, confirm the previous theory of atherosclerotic-based formation of AAA, indicating the morphological and immunological dissimilarities of both pathologies.^{7,8} The identification of the gene responsible for the hereditary form of AAA, being one of the most important finding of modern medicine in the recent years, seems to confirm such thesis.^{9,10}

Aim

The aim of this paper was to evaluate the presence of atherosclerotic lesions in the aorta and/or the arteries of the lower extremities, as well as stenoses and/or occlusions of carotid arteries in patients with abdominal aorta aneurysm.

Methods

The study was carried out in the Department of Vascular, General and Oncological Surgery, Copernicus Memorial Hospital, Lodz, Poland. One-hundred and eighty patients with abdominal aorta aneurysm (23 women and 157 men), aged 50–86 years old (mean 67.28 ± 9.95) were qualified for the study. Each patient had a color Doppler ultrasound of the abdominal aorta, the arteries of the lower extremities and extracranial carotid arteries performed. At the time of the study almost every patient with AAA + AS (84 out of 88) received best medical treatment for this condition (ASA + statin), whereas only approx. 50% of the patients with AAA only received ASA.

The patients were divided into two groups according to the ultrasound findings and observed flow disturbances:

GROUP A (AAA) – isolated abdominal aorta aneurysm, 92 patients, including 14 women (15.2%) and 78 men (84.8%), mean age 67.43;

GROUP B (AAA + AS) – the presence of atherosclerotic lesions in the abdominal aorta or the arteries of the lower extremities concomitant to AAA, 88 patients, including 9 women (10.2%) and 79 men (89.8%), mean age 67.13.

The extracranial segments of both carotid arteries (CCA + ICA) were assessed in each patient using 2-D presentation. The flow velocities were measured and spectral analysis (duplex Doppler) and color flow imaging were performed as well. The quantitative evaluation of atherosclerotic lesions in the assessed carotid arteries segments (CCA + ICA stenoses) was performed according to the NASCET guidelines, including the analysis of the alterations in flow spectrum as well, to confirm the stenosis grade. Once each stenosis was automatically calculated, each artery was assigned to one of the following groups:

- a – no atherosclerotic lesions (0%),
- b – low-grade stenosis (1–29%),
- c – medium-grade stenosis, hemodynamically insignificant (30–49%),
- d – medium-grade stenosis, hemodynamically significant (50–69%),
- e – high-grade stenosis (70–99%),
- f – artery occlusion (100%).

Statistics

The obtained results were subjected to statistical analysis using Excel and Statgraphics Plus v. 5.0 software. The patients' structure estimated according to the observed features was determined using percentages. The studied group of patients was described using stratum weights for the qualitative features. For quantitative features the arithmetic mean (X_m) was calculated as an average value and measure of dispersion – standard deviation (SD) and minimal and maximal values were presented. Test for two means was used to compare the calculated arithmetic means: a) for large sample size ($n_1, n_2 > 30$), b) for small sample size ($n_1, n_2 < 30$). The difference between studied parameters was considered statistically significant (incidences, arithmetic means), when the calculated test value was equal or greater than the critical value obtained from chi-square tables (normal, t-Student) with appropriate number of degrees of freedom and error probability of less than 0.05.

Results

Table 1 presents general description of both analyzed groups and the distribution of risk factors. The A group was characterized by statistically significant higher mean diameter of AAA than group B ($p < 0.001$). The prevalence of carotid lesions, smoking and ischemic heart disease was significantly more frequent in patients from group B.

Figure 1 presents the distribution of atherosclerotic lesions in the carotid arteries among the patients of group A and B. The percentage rate of over 50% carotid artery stenoses (d and e) was 10.55%, i.e. 19 patients (d – 6.67%, i.e. 12 patients, and e – 3.89%, i.e. 7 patients). The carotid artery occlusion (f) was observed in 11 patients (6.11%) and its incidence was similar in both groups: i.e. 6 patients in group A (6.52%) and 5 patients in group B (5.68%).

The difference in the distribution of carotid atherosclerotic lesions was statistically significant ($p < 0.05$) between groups A and B as a whole.

Statistically significant differences ($p < 0.05$) between groups A and B were observed for carotid stenoses 50–69% (d), cumulated non-occlusive stenoses over 50% (d + e) and such stenoses combined with occlusion group (d + e + f).

No statistically significant association was observed between the aneurysm diameter and carotid artery stenosis both for isolated aneurysm, and for AAA concomitant with atherosclerosis of aorta and/or arteries of the lower extremities (Fig. 2).

Discussion

Until recently atherosclerosis was considered the primary cause for the formation of abdominal aorta aneurysms.¹ Commonly observed atherosclerotic plaques in the intima of aneurysmatic aorta and processes associated with their

formation and evolution, such as rupture and dissection secondary to the hemorrhagic conversion may influence the natural course of aneurysm, resulting in the reduction of wall strength and raise in the risk of aneurysm rupture. One of the main phenomenon taking place during blood vessel aging is the degradation of elastic fibers, which intensifies in such conditions as atherosclerosis, arterial hypertension and diabetes.^{3,4} Some studies indicated the high elastase activity in human aorta extracts, which increased exponentially with age and correlated with the severity of atherosclerotic lesions. The impairment of elastin/laminin receptor function and its permanent stimulation (e.g. during aging) was proven responsible for the overproduction of elastases and elastin degradation.⁴ The positive correlation between the concentration of elastin degradation products and aneurysm growth rate was found.^{5,6} The atherosclerosis-like process that was previously considered responsible for pathological aorta dilatation was not confirmed in recent studies. Although numerous studies concerning the processes of vascular damage revealed many common features between atherosclerosis and aortic aneurysm, the detailed analyses proved that they are generally different pathological phenomena, showing their morphological and immunological dissimilarities.^{7,8} The proliferation of arterial intima is the dominating element in the pathology of atherosclerosis, whereas the weakening of media and adventitia contribute to the reduction in elasticity and tensile strength of the aorta. It results in the reduction of wall thickness, increase in wall tension, dilation of aortic lumen, which may eventually lead to aortic rupture. The discovery of these phenomena and processes, which contribute to the pathological aortic dilation led to common recognition of multifactorial aneurysm etiology.

One of the main issues concerning aneurysm etiology is pathological processes taking place in its wall and

Table 1 Analyzed groups characteristics.

Group characteristics	Total		A (AAA)		B (AAA + AS)		A vs B	
	N	%	N	%	N	%	Statistical analysis	p value
Mean age	67.28	± 9.95	67.43	± 10.2	67.13	± 10.3	0.202	0.840
Mean diameter of AAA	42.47	± 11.6	45.79	± 14.27	39.14	± 8.90	3.769	0.0002
Sample size	180	100	92		88			
Sex								
Men	157	87.2	78	84.8	79	89.8	1.005	0.316
Women	23	12.8	14	15.2	9	10.2		
Presence of carotid lesion	114	63.3	46	50.0	68	77.2	14.418	0.0001
Smoking	113	62.8	40	43.5	73	83.0	21.8	0.00001
Hypertension	55	30.6	26	28.3	29	33.0	0.468	0.494
Hyperlipidemia	13	7.2	4	4.3	9	10.2	2.317	0.128
Diabetes	10	5.6	6	6.5	4	4.5	0.064	0.800
Ischemic heart disease	25	13.9	8	8.7	17	19.3	4.261	0.0390
Stroke or TIA	3	1.7	2	2.2	1	1.1	0.002	0.969
Previous vascular surgery due to atherosclerosis	2	1.1	4	4.3	6	6.8	0.158	0.691

A – isolated abdominal aorta aneurysm (AAA), B – the presence of atherosclerotic lesions in the abdominal aorta or arteries of the lower extremities concomitant to AAA (AAA + AS).

TIA – transient ischemic attack.

The numbers in bold indicate statistically significant differences.

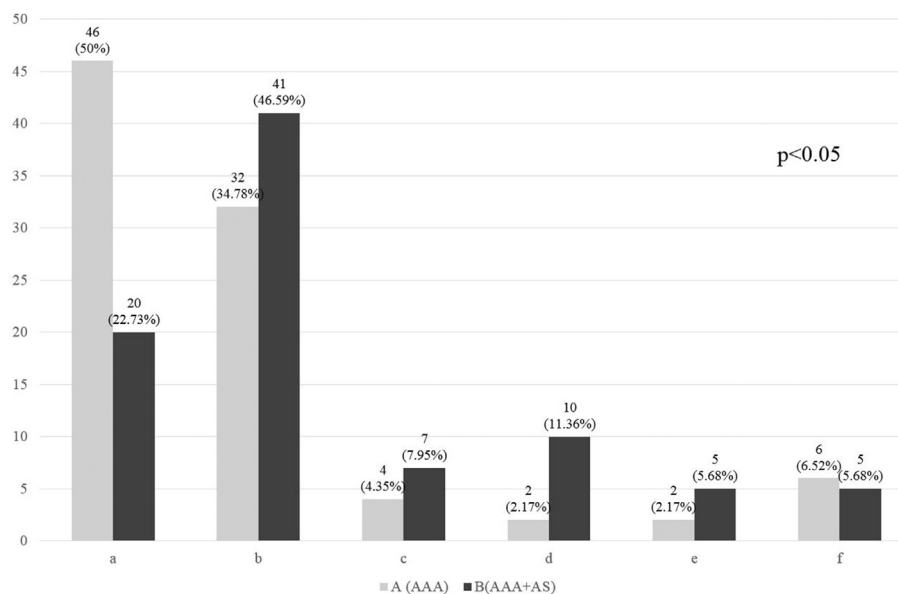


Figure 1 Distribution of atherosclerotic lesions in carotid arteries in particular groups, including stenosis grade. A – isolated abdominal aorta aneurysm (AAA), B – the presence of atherosclerotic lesions in the abdominal aorta or arteries of the lower extremities concomitant to AAA (AAA + AS). a – no atherosclerotic lesions (0%), b – low-grade stenosis (1–29%), c – medium-grade stenosis hemodynamically insignificant (30–49%), d – medium-grade stenosis hemodynamically significant (50–69%), e – high-grade stenosis (70–99%), f – artery occlusion (100%). The difference between the groups, as a whole, is statistically significant.

concomitance of various systemic diseases. The etiological factors that accompany aortic aneurysms include: degenerative diseases, congenital developmental defects, smoking, infections, vasculitides and trauma. The significant factors determining the formation of aortic aneurysm

include: inflammation, proteolytic connective tissue degradation and biomechanical factors, that alter the quality and structure of aortic wall and consequently contribute to the reduction of aortic resistance to forces associated with pulsatile blood flow.¹¹ It is favored by

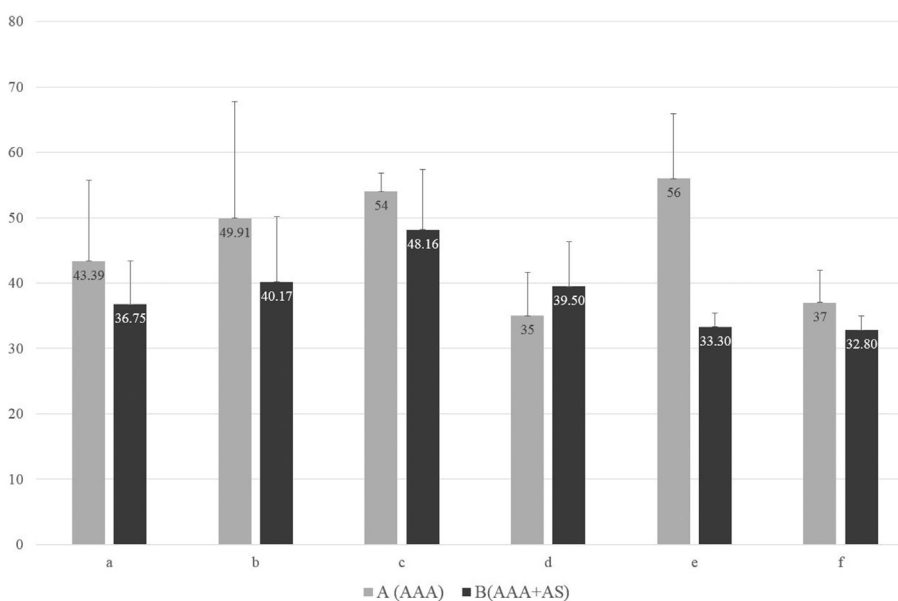


Figure 2 Aneurysm diameter (mm) and carotid lesions in groups. O – total, A – isolated abdominal aorta aneurysm (AAA), B – the presence of atherosclerotic lesions in the abdominal aorta or arteries of the lower extremities concomitant to AAA (AAA + AS). a – no atherosclerotic lesions (0%), b – low-grade stenosis (1–29%), c – medium-grade stenosis hemodynamically insignificant (30–49%), d – medium-grade stenosis hemodynamically significant (50–69%), e – high-grade stenosis (70–99%), f – artery occlusion (100%). The difference between the groups, as a whole, is not statistically significant.

factors associated with wall structure itself, characteristic of blood flow and reduction of perfusion in abdominal aortic wall supplied by supplying vessels.^{12–14}

Commonly recognized pathological phenomenon is the presence of atherosclerotic lesions in patients with abdominal aorta aneurysm in the aorta itself, and the arteries of the lower extremities, carotid arteries and coronary arteries as well.^{15–23} Frequent incidence of these two pathologies was confirmed both in clinical observation, and autopsy as well, especially among older men.^{15,24,25} Their correlation is being discussed for years and several theories were developed, aiming at explaining the mutual influence of these pathological phenomena.²⁶

The first theory of atherosclerosis-based aneurysm etiology led to the development of the term “atherosclerotic aneurysm” that is present in medicine for over 100 years and is still being used by some researchers.^{26–28} It assumes the presence of causal relationship between atherosclerotic degeneration of aortic wall and the formation of aneurysmatic dilation of its lumen. It is based on the known and well-described in the literature phenomenon of compensatory dilation of arterial lumen resulting from its wall remodeling in response to shear stress, should the lesion leading primary to stenosis of the vessel lumen, such as atherosclerosis, occur.²⁹ The degradation of intracellular matrix proteins and proteolytic elastin damage may result from chronic inflammatory process secondary to atherosclerosis and concomitant arterial thrombosis.^{22,29} As far as the remodeling may explain the marked reduction of media thickness, it has no significant influence on adventitia inflammation observed in aneurysmatic aorta. Should aneurysm have causative atherosclerotic background, the atherosclerotic lesions should be present in aortic or arterial wall of all patients. It is contradicted by published papers, which authors indicate various incidence of both pathologies in patients, yet they never reach 100% in AAA-patients.³⁰

The second theory presumes the independent occurrence of both aortic pathologies, yet common contribution of some genetic and environmental risk factors, whereas the type of the lesion being developed is associated with different pathophysiological mechanism.²¹ It is supported by the observation of many similarities in pathogenesis and pathophysiology of both diseases.^{31–34} The opponents of this theory indicate obvious differences among risk factors characteristic in patients with atherosclerosis developing in carotid, coronary and lower extremities arteries and patients with aortic aneurysm.^{35–38} The significant difference in the incidence of diabetes was found in both groups, which is negative or neutral risk factor for AAA, but positive for atherosclerosis.²² Other authors indicate different genetic factors that may be responsible for each of the mentioned vascular pathologies.³⁹ They supported their hypothesis by identifying the gene that is responsible for hereditary aortic aneurysm.¹⁰

The third possibility to explain the association between atherosclerosis and aortic aneurysm is their mutual stimulatory interaction, regardless of the fact which pathology occurs first.²⁶ Remodeling occurrence in patients with the primary atherosclerosis of aortic wall and being a result of flow disturbances in the atherosclerotic abdominal aorta, interaction with oxidized LDL and the release of

proinflammatory cytokines from mural thrombi leads to the secondary proteolysis and degradation of intracellular matrix and inflammation that may lead to wall weakening and aneurysmatic dilation of aortic lumen.

The presence of thrombi in the aneurysmal sac that contains high concentration of proteolytic enzymes and plasminogen activators contributes to the injury of the aortic wall, which leads to the aneurysm growth and rupture.^{40–42} On the other hand however, their presence hampers oxygen perfusion to the aortic wall, which increases vessel stiffness, reduces its compliance and ability to adapt to blood pressure changes, which in turn contributes to the formation of atherosclerotic plaques should certain environmental factors interact.^{43,44}

The Norwegian TROMSO Study that included 6,500 adults from general population attempted to determine the relationship between the atherosclerosis of carotid, femoral and coronary arteries and the aortic aneurysm diameter.³⁰ The results excluded the existence of such relationship, whereas the authors suggested that there are no data that could confirm the causative relationship between atherosclerosis and AAA. They suggested that atherosclerotic lesions develop in the aortic wall parallel to its aneurysmal dilation or are secondary to AAA. The SMART study, determining the thickness of intima-media complex in the common carotid artery in various patient groups revealed significant differences between patients with peripheral atherosclerosis and patients with AAA. Therefore the authors concluded that the development of aneurysmal dilation of abdominal aorta, may not simply be explained by atherosclerotic pathology of vessel wall and is determined by other pathophysiological mechanism.⁴⁵ There is insufficient evidence to confirm that AAAs are the result of atherosclerosis.⁴⁶

A positive correlation was found between both the incidence and the grade of carotid artery stenosis and the presence of chronic lesions in aorta and/or arteries of the lower extremities, although it differed in both groups. The percentage of patients with atherosclerotic lesions in carotid arteries was relatively lower (50.0) in patients with isolated abdominal aorta aneurysm and the incidence of over-50% stenoses did not exceed 5%. The significantly higher rate of carotid lesions (77.27%) and higher grade of carotid artery stenosis (17.04% stenoses over 50%) was observed in patients with AAA concomitant to atherosclerotic lesions in peripheral arteries.

The routine evaluation of extracranial segments of carotid arteries during the duplex Doppler examination of aorta and the arteries of the lower extremities in patients with chronic peripheral vascular diseases, regardless of diagnostic or therapeutic indications, may pose a valuable screening tool. The presented comparisons between study groups may allow to identify patients, in which the screening for carotid disease may be most justified and show greatest cost-effectiveness ratio. The statistical analysis revealed significant differences ($p < 0.001$) in the distribution of carotid artery lesions between the patients with isolated AAA and patients with AAA concomitant to atherosclerotic lesions in aorta and/or arteries of the lower extremities.

The above-mentioned observations may confirm the theory of differing etiology of atherosclerosis and

abdominal aorta aneurysm, and their independent incidence. The lack of statistical significance in the difference between the diameter of abdominal aorta aneurysm and the carotid artery stenosis that was observed both for isolated aneurysm, as well as for aneurysm concomitant to atherosclerosis of aorta and/or arteries of the lower extremities seems to additionally confirm such conclusion.

Conclusions

The presented results confirm the common occurrence of atherosclerotic lesions in aorta and/or arteries of the lower extremities and carotid arteries in patients with abdominal aorta aneurysm, yet their etiology is different. Such patients represent a heterogeneous group in respect to the presence of carotid arteries stenoses.

Conflict of interest

None.

References

- Creager MA, Halperin JL, Whittmore AD. Aneurysmal disease of the aorta and its branches. In: Dzau VJ, editor. *Vascular medicine: a textbook of vascular biology and diseases*. Boston: Little, Brown and Company; 1996. p. 901.
- Harris JA, Kostaki G, Glover JL. Penetrating atherosclerotic ulcers of the aorta. *J Vasc Surg* 1994;19:90.
- Tanno T, Yoshinaga K, Sato T. Alteration of elastin in aorta from diabetics. *Atherosclerosis* 1993;101:129.
- Robert L. Mechanism of aging of the extracellular matrix: role of elastin-laminin receptor. *Gerontology* 1998;44:307.
- Lindholt JS, Heickendorf L, Henneberg EW, Fasting HL. Serum-elastin-peptides as a predictor of small abdominal aortic aneurysms. *Eur J Vasc Endovasc Surg* 1997;14:12.
- Nackman GB, Karkowski JK, Halpern VJ, Gaetz HP, Tilson MD. Elastin degradation products induce adventitial angiogenesis in the Anidjar/Dobrin rat aneurysm model. *Surgery* 1997;122:39.
- McMillan WD, Patterson BK, Keen RR, Pearce WH. In situ localization and quantification of seventy-two-kilodalton type IV collagenase in aneurysmal, occlusive, and normal aorta. *J Vasc Surg* 1995;22:295.
- Reilly JM, Sicard GA, Lucore CL. Abdominal expression of plasminogen activators in aortic aneurysmal and occlusive disease. *J Vasc Surg* 1994;19:865.
- Hinterseher I, Tromp G, Kuivaniemi H. Genes and abdominal aortic aneurysm. *Ann Vasc Surg* 2011 Apr;25(3):388–412.
- Golledge J, Kuivaniemi H. Genetic of abdominal aortic aneurysm. *Curr Opin Cardiol* 2013;28(3):290–6.
- Wassef M, Baxtr BT, Chisholm RL, Dalman RL, Fillinger MF, Heinecke J, et al. Pathogenesis of abdominal aortic aneurysms: a multidisciplinary research program supported by the National Heart, Lung, and Blood Institute. *J Vasc Surg* 2001;34:730.
- Wolinsky H, Glagov S. Comparison of abdominal and thoracic aortic medial structure in mammals: deviation of man from the usual pattern. *Circ Res* 1969;25:677.
- Benjamin HD, Becker AB. Etiologic incidence of thoracic and abdominal aneurysms. *Surg Gynecol Obstet* 1967;125:1307.
- Moore Jr JE, Ku DN, Zarins CK, Glagov S. Pulsatile flow visualization in the abdominal aorta under differing physiologic conditions: implications for increased susceptibility to atherosclerosis. *J Biochem Eng* 1992;114:391.
- Barba A, Estallo L, Rodriguez L, Baquer M, Vega de Céniga M. Detection of abdominal aortic aneurysm in patients with peripheral artery disease. *Eur J Vasc Endovasc Surg* 2005;30(5):504–8.
- Johnsen SH, Forsdahl SH, Solberg S, Singh K, Jacobsen BK. Carotid atherosclerosis and relation to growth of infrarenal aortic diameter and follow-up diameter. The Tromso study. *Eur J Vasc Endovasc Surg* 2013 Feb;45(2):135–40.
- Giugliano G, Laurenzano E, Rerngo C, De Rosa G, Brevetti L, Sannino A, et al. Abdominal aortic aneurysm in patients affected by intermittent claudication: prevalence and clinical predictors. *BMC Surg* 2012;12(Suppl. 1):S17 [Epub 2012 Nov 15].
- Varenne O, Touze E, Collet JP, Raoux F, Boissier C, Carpentier PH, et al. Screening strategies for the diagnosis of asymptomatic arterial lesions in patients with atherothrombosis. *Arch Mal Coeur Vaiss* 2005 Oct;98:5–14. Spec No 4.
- Kurvers HA, van der Graaf Y, Blankensteijn JD, Visseren FL, Eikelboom B, SMART Study Group. Screening for asymptomatic internal carotid artery stenosis and aneurysm of the abdominal aorta: comparing the yield between patients with manifest atherosclerosis and patients with risk factors for atherosclerosis only. *J Vasc Surg* 2003 Jun;37(6):1226–33.
- Axelrod DA, Diwan A, Stanley JC, Jacobs LA, Henke PK, Greenfield LJ, et al. Cost of routine screening for carotid and lower extremity occlusive disease in patients with abdominal aortic aneurysms. *J Vasc Surg* 2002 Apr;35(4):754–8.
- Pasierski T, Kostewicz W, Roston J, Paczwa P. Prevalence of abdominal aortic aneurysm and peripheral arteria diseases in ambulatory patients with coronary disease. *Pol Arch Med Wewn* 2004 Feb;111(2):199–203.
- Golledge J, Muller J, Daugherty A, Norman P. Abdominal aortic aneurysm: pathogenesis and implications for management. *Arterioscler Thromb Vasc Biol* 2006;26:2605–13.
- Cornuz J, Sidoti pinto C, Tevaerai H, Egger M. Risk factors for asymptomatic abdominal aortic aneurysm: systemic review and meta-analysis of population-based screening studies. *Eur J Public Health* 2004;14:343–9.
- Savji N, Rockman CB, Skolnick AH, Guo Y, Adelman MA, Riles T, et al. Association between advanced age and vascular disease in different arterial territories: a population database of over 3.6 million subjects. *J Am Coll Cardiol* 2013; 23;61(16):1736–43.
- Dupont A, Elkalioubie A, Juthier F, Tagzirt M, Vincentelli A, Le Tourneau T, et al. Frequency of abdominal aneurysm in patients undergoing coronary bypass grafting. *Am J Cardiol* 2010; 1;105(11):1545–8.
- Golledge J, Norman P. Atherosclerosis and abdominal aortic aneurysm: cause, response or common risk factors? *Arterioscler Thromb Vasc Biol* 2010;30(6):1075–7.
- Eiseman B, Hughes RH. Repair of an abdominal aortic vena cava fistula caused by rupture of an atherosclerotic aneurysm. *Surgery* 1956;39:498–504.
- Kaschina E, Scholz H, Steckelings UM, Sommerfeld M, Kemnitz UR, Artuc M, et al. Transition from atherosclerosis to aortic aneurysm in human coincides with an increased expression of RAS components. *Atherosclerosis* 2009;205:396–403.
- Ward MR, Pasterkamp G, Yeung AC, Borst C. Arterial remodeling. Mechanisms and clinical implications. *Circulation* 2000; 102:1186–91.
- Johnsen SH, Forsdahl SH, Singh K, Jacobsen BK. Atherosclerosis in abdominal aortic aneurysms: a causal event or a process running in parallel? The Tromso study. *Arterioscler Thromb Vasc Biol* 2010;30(6):1263–8.
- Golledge J, Tsao PS, Dalman RL, Norman PE. Circulating markers of abdominal aortic aneurysm presence and progression. *Circulation* 2008;118:2382–92.

32. Helgadóttir A, Thorleifsson G, Magnússon KP, Grétarsdóttir S, Steinhórsdóttir V, Manolescu A, et al. The same sequence variant on 9P21 associates with myocardial infarction, abdominal aortic aneurysm and intracranial aneurysm. *Nat Genet* 2008;40:217–24.
33. Deng GG, Martin-McNulty B, Sukovich DA, Freay A, Halks-Miller M, Thinnis T. Urokinase-type plasminogen activator plays a critical role in angiotensin II-induced abdominal aortic aneurysm. *Circ Res* 2003;92:510–7.
34. Brummer D, Collins AR, Noh G, Wang W, Territo M, Arias-Magallona S, et al. Angiotensin II-accelerated atherosclerosis and aneurysm formation is attenuated in osteopontin-deficient mice. *J Clin Invest* 2003;112:1318–31.
35. Palazzuoli A, Gallotta M, Guerrieri G, Quatrini I, Franci B, Campagna MS, et al. Prevalence of risk factors, coronary and systemic atherosclerosis in abdominal aortic aneurysm: comparison with high cardiovascular risk population. *Vasc Health Risk Manag* 2008;4(4):877–83.
36. Golledge J, van Bockxmeer F, Jamrozik K, McCann M, Norman PE. Association between serum lipoproteins and abdominal aortic aneurysm. *Am J Cardiol* 2010; 15;105(10):1480–4.
37. Luttun A, Lutgens E, Manderveld A, Maris K, Collen D, Carmeliet P, et al. Loss of matrix metalloproteinase-9 or matrix metalloproteinase-1 protects apolipoprotein E-deficient mice against atherosclerotic media destruction but differentially affects plaque growth. *Circulation* 2004;109:1408–14.
38. Golledge J, Cullen B, Rush C, Moran CS, Secomb E, Wood F, et al. Peroxisome proliferator-activated receptor ligands reduce aortic dilatation in a mouse model of aortic aneurysm. *Atherosclerosis* 2010;210(1):51–6.
39. Golledge J, Biros E, Cooper M, Warrington N, Palmer LJ, Norman PE. Apolipoprotein E genotype is associated with serum C-reactive protein but not abdominal aortic aneurysm. *Atherosclerosis* 2010;209(2):487–91.
40. Wang DH, Makaroun MS, Webster MW, Vorp DA. Effect of intraluminal thrombus on wall stress in patient-specific models of abdominal aortic aneurysm. *J Vasc Surg* 2002;36:598.
41. Thubrikar MJ, Robicsek F, Labrosse M, Chervenkov V, Fowler BL. Effect of thrombus on abdominal aortic aneurysm wall dilation and stress. *J Cardio Vasc Surg (Torino)* 2003;44:67.
42. Fontaine V, Jacob MP, Houard X, Rossignol P, Plissonnier D, Angles-Cano E, et al. Involvement of the mural thrombus as a site of protease release and activation in human aortic aneurysms. *Am J Pathol* 2002;161:1701.
43. Heistad DD, Marcus ML, Larsen GE, Armstrong ML. Role of vasa vasorum in nourishment of the aortic wall. *Am J Physiol* 1981; 240:H781.
44. Strefandis C, Vlachopoulos C, Karayannacos P, Boudoulas H, Stratos C, Filippides T, et al. Effect of vasa vasorum flow on structure and function of the aorta in experimental animals. *Circulation* 1995;91:2669.
45. Simons PC, Algra A, Bots ML, Banga JD, Grobbee DE, van der Graaf Y. Common carotid intima-media thickness in patients with peripheral arterial disease or abdominal aortic aneurysm: the SMART study. Second manifestations of ARterial disease. *Atherosclerosis* 1999;146(2):243–8.
46. Nordon IM, Hinchliffe RJ, Holt PJ, Loftus IM, Thompson MM. Review of current theories for abdominal aortic aneurysm pathogenesis. *Vascular* 2009 Sep–Oct;17(5):253–63.