

Improvement of radiation-induced xerostomia with acupuncture: A retrospective analysis[☆]



Kris A. Homb^a, Hong Wu^{a,b,*}, Sergey Tarima^c, Dian Wang^d

^a Department of Physical Medicine and Rehabilitation, Medical College of Wisconsin, Milwaukee, WI 53226, USA

^b Department of Anesthesiology, Medical College of Wisconsin, Milwaukee, WI 53226, USA

^c Institute for Health and Society, Medical College of Wisconsin, Milwaukee, WI 53226, USA

^d Department of Radiation Oncology, Medical College of Wisconsin, Milwaukee, WI 53226, USA

ARTICLE INFO

Article history:

Received 16 December 2013

Accepted 18 February 2014

Keywords:

Acupuncture
Head and neck cancer
Radiation therapy
Xerostomia

ABSTRACT

Objective: Our previous case study introduced combination acupuncture (manual, auricular and electro-acupuncture) as a treatment for radiation-induced xerostomia. The present retrospective study evaluates the effect of combination acupuncture on the severity of dry mouth and activities of daily living as related to radiation-induced xerostomia.

Design: Data was retrospectively collected from twenty-two patients with xerostomia related to radiotherapy for head and neck cancer (HNC). Sixteen patients who met the inclusion and exclusion criteria were analyzed for this report. The intervention was weekly 20 min sessions of combination acupuncture. Upon reaching a plateau in symptom improvement the length in time between treatments was increased as tolerated without return of symptoms. Outcome measures included a self-reported quality of life xerostomia questionnaire completed prior to each acupuncture session and quantitative data from documented Modified Schirmer's tests.

Results: Significant improvement in dry mouth and pain occurred during the initial six weeks of treatment ($p < 0.05$). During this period, the mean severity of dry mouth and pain decreased by 35% and 50%, respectively ($p < 0.001$). After six weeks, the improvement in dry mouth and pain symptoms plateaued. This effect was maintained with intermittent acupuncture treatments.

Conclusions: Combination acupuncture significantly decreases the severity of dry mouth and pain with long lasting effects, up to six months (at the end of data collection), in patients with radiation-induced xerostomia.

© 2014 Elsevier GmbH. All rights reserved.

1. Introduction

Xerostomia is a well-known side effect in patients who have undergone radiotherapy with or without chemotherapy for head and neck cancer (HNC) [1]. Radiation-induced fibrosis and/or scarring of the salivary glands causes decreased salivary secretion [2]. Xerostomia may result in significant morbidity with impairments in speaking, eating, and swallowing, decreased sense of taste, and increased risk of dental caries [3,4]. Despite advancements of dose-delivering technologies such as intensity-modulated radiotherapy (IMRT) to protect a portion of parotid glands from high-dose radi-

ation, xerostomia continues to be common in patients with HNC after radiation [5–7]. IMRT's use is also limited due to its increased expense, risk of marginal miss, and lack of universal availability [5,6]. Currently, xerostomia is often treated with saliva substitutes and/or cholinergic agonists, such as pilocarpine hydrochloride. These treatments are short acting requiring frequent dosing and in the case of pilocarpine the reported response rate is 31–54% [8]. In addition, HNC patients are often unable to tolerate long-term use of pilocarpine secondary to its associated side effects such as sweating, rhinitis, chills, nausea, urinary frequency, and cardiac arrhythmias [8,9].

Several studies have examined the use of acupuncture on cancer related symptoms including xerostomia with mixed results [10–12]. Furthermore, the techniques used in these studies vary in type of acupuncture, acupuncture points, and number of treatments performed. These studies frequently involved manual and/or auricular acupuncture without the use of electro acupuncture.

[☆] Research previously presented as a poster at the 2013 American Academy of Physical Medicine and Rehabilitation National Meeting in Washington, DC.

* Corresponding author at: 9200 West Wisconsin Avenue, Milwaukee, WI 53226, USA. Tel.: +1 414 805 7368; fax: +1 414 955 0104.

E-mail addresses: hongwu@mcw.edu, wu.128@yahoo.com (H. Wu).

Table 1
Demographics characteristics.

Patient	Age	Sex	Cancer	Irradiation (Gy)	Chemo
1	53	M	T3N2b SCC of the right tonsil	70	Yes
2	63	F	T4aN0M0 SCC of the Left Posterior Alveolar Ridge	59.4	No
3	56	M	T1N2aM0 SCC of the left tongue base	70	Yes
4	68	F	T1N0M0 SCC of the right tonsil	66	Yes
5	56	F	T1N2aM0 SCCA left oropharynx (pharyngeal wall)	70	Yes
6	56	M	T2N2bN0 SCC of base of tongue	70	Yes
7	64	M	TxN2M0 SCC in right neck	70	No
8	48	M	T1N1M0 SCC of R base of tongue	66	Yes
9	70	F	Recurrent B cell diffuse lymphoma stage IIA, neck lymph node, received re-irradiation	70	Yes
10	49	M	T2N2bM0 SCC of the oropharynx	70	Yes
11	74	M	SCC of the right tongue	70	Yes
12	46	F	T1N1M0 SCCA left oral tongue	70	No
13	54	M	T1N0M0 SCC of the left tonsil	72	No
14	56	M	T4N2a SCC of the tonsil	70	Yes
15	66	M	T4N1M0 nasopharyngeal carcinoma	66	Yes
16	66	M	T1N1Mx SCC of the right oropharynx	70	Yes

SCC, squamous cell cancer; SCCA, squamous cell cancer antigen.

According to the meridian principle described in traditional Chinese medicine, the mechanism and efficacy of the various acupuncture techniques are different [13]. We hypothesize that combination acupuncture (manual, auricular, and electro acupuncture) provides maximal stimulation to salivary glands in HNC patients treated with radiation. We previously demonstrated the feasibility of combination acupuncture as a treatment for radiation-induced xerostomia [14]. In the present study, we retrospectively reviewed a series of cases and report the effect of combination acupuncture on radiation-induced xerostomia and associated quality of life.

2. Materials and methods

This study was approved by an accredited health sciences' Institutional Review Board. The charts of twenty-two HNC patients with a diagnosis of radiation-induced xerostomia and referred for acupuncture between January 1st 2006 and October 16th 2012 were reviewed. Inclusion criteria, for this study, included adult HNC subjects with radiation-induced xerostomia secondary to parotid radiation, at least three months after the completion of definitive or adjuvant radiation and/or chemotherapy, cancer in a cured or remission status, failure of previous conservative treatments for xerostomia, and between 18 and 90 years of age. Exclusion criteria included those with concurrent use of pilocarpine or a history of Sjogren's syndrome.

Sixteen subjects (11 male and 5 female) met the inclusions and exclusion criteria. Demographic data included age, sex, form of cancer, total dose of radiation, and whether they received chemotherapy (Table 1). All patients received definitive IMRT with more than 50% parotid gland sparing from high dose radiation (30 Gy or more). Subjective data was obtained from documented self-reported xerostomia quality of life questionnaires completed prior to each acupuncture session (Table 2).

Objective data was obtained from documented Modified Schirmer's tests (MST) [15]. All tests were performed by one examiner. The patients were asked to avoid eating, drinking, or sucking on any candy 1 h prior to their appointment. The examiner, using a forceps, placed a test strip (Eagle Vision, Memphis, TN) against the floor of the patient's mouth, over the sublingual salivary gland [15]. The test strip, a 4-cm strip of filter paper impregnated with blue dye at the 0-mm mark and calibrated in 1-mm intervals from 5 to 35 mm along its length, diffused dye up the strip proportionately to the amount of saliva absorbed. The scale was read and documented after 1 and 2 min. If the reading was less than 5 mm it was documented as <5 mm. If the reading was greater than 35 mm it was documented as >35 mm.

Acupuncture was performed by one physician who is certified in Physical Medicine and Rehabilitation and Pain Medicine and trained in acupuncture. Acupuncture sessions were held weekly until patients reached a plateau in symptom improvement. Time between sessions was then extended in one week increments, as long as symptoms did not worsen. Combination acupuncture was performed in the same technique as previously reported [14]. Briefly, the first session included manual and auricular acupuncture; subsequent sessions included manual, auricular, and electro-acupuncture. Treatment points (Fig. 1) included stomach (ST) points 3, 4, 5, 6, and 7; small intestine (SI) points 18 and 19; gallbladder (GB) points 2 and 3; large intestine (LI) points 4 and 11; spleen (SP) point 6; dumai (DU) point 20, renmai (RN) points 23 and 24, and the ear points Shen Men and Point Zero. The acupuncture points used in this study were selected on the basis of the meridian principle described in traditional Chinese medicine [13]. Electrical stimulation was applied to ST 5, 6, and 7 bilaterally. Stimulation was set to an intensity that the patient was able to feel and tolerate. Needles for manual and electro acupuncture remained in place for 15–20 min. Auricular acupuncture needles were left in place for up to three days, and patients were advised to massage these points multiple times daily.

Table 2
Xerostomia quality of life survey questions used for statistical analysis.

1.	Overall, how severe is your dry mouth?	1 → 10 (1 = less severe, 10 = severe)
2.	Overall, how severe is your pain?	1 → 10 (1 = less severe, 10 = severe)
3.	How many hours are you able to sleep at night?	1 = never (>7 h), 2 = hardly ever (5–6 h), 3 = occasional (3–4 h), 4 = fairly often (2 h), 5 = very often (1 h or less)
4.	Do you have difficulties swallowing any foods?	1 = never, 2 = hardly ever, 3 = occasional, 4 = fairly often, 5 = very often
5.	Does your mouth feel dry when eating a meal?	1 = never, 2 = hardly ever, 3 = occasional, 4 = fairly often, 5 = very often
6.	Do you feel difficulty in speaking?	1 = never, 2 = hardly ever, 3 = occasional, 4 = fairly often, 5 = very often

Pain is in reference to facial and throat pain.

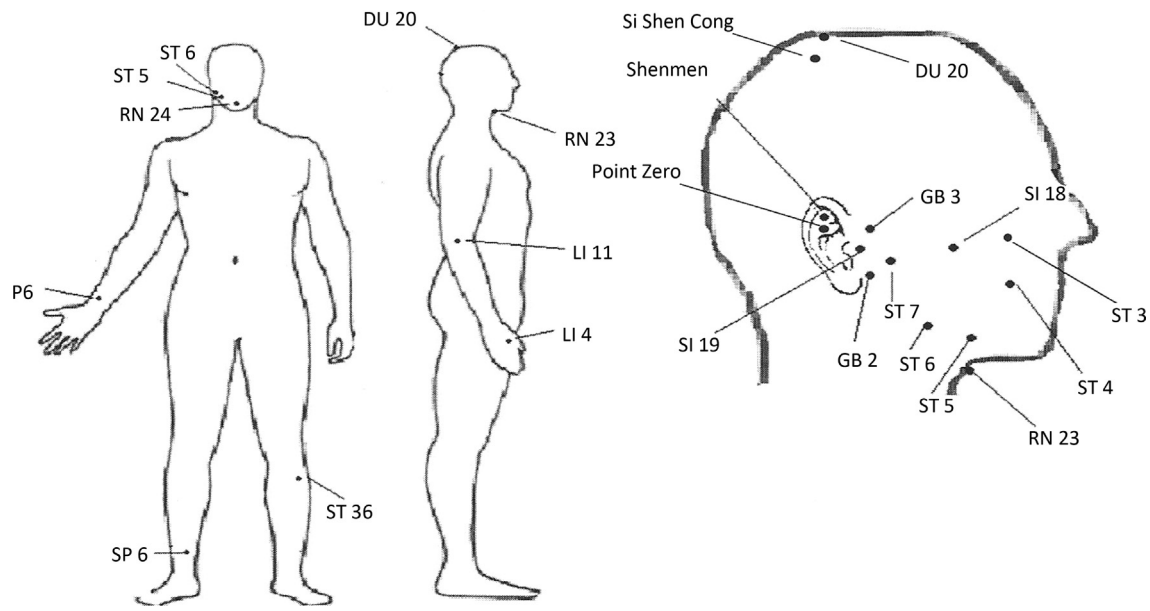


Fig. 1. Acupuncture treatment points.

Data was analyzed using linear mixed model analysis with random subject effect. Our regression models used four regression parameters to approximate over time a linear trend during the first six weeks and a linear trend after the six week cutoff.

Graphic representation of over time progression of severity of dry mouth (Fig. 2), severity of pain (Fig. 3) and the MST (Fig. 4) were based on available observations ignoring potential within person dependence. The scatter plots of these pictures were “jittered” by adding a random noise to separate overlapping points. Mean response was estimated by a non-parametric regression with manually selected bandwidth.

Due to a transition of electronic medical records and poor documentation, between January 1, 2006 and June 1, 2011, multiple surveys were not available, limiting statistical analysis. Additionally some patients were lost to follow up after three treatments of acupuncture.

3. Results

The baseline severity of dry mouth (Fig. 2) was estimated as 8.21 and improved to 5.33 during the initial six weeks of treatment ($p < 0.001$). The estimated rate of improvement was 0.44 units per week. After six weeks, the rate of improvement plateaued to 0.006 units per week and was not significant ($p = 0.116$). The baseline severity of pain (Fig. 3) was 3.14 and improved to 1.56 during the initial six weeks of treatment ($p < 0.001$). After six weeks, the improvement plateaued ($p = 0.134$).

During the initial six weeks of treatment, there was not significant statistical improvement in sleep. There was a significant increase in difficulty sleeping between six weeks and six months ($p = 0.008$).

Data analysis on difficulties swallowing, speaking, and dry mouth with eating trended towards improvement, however were

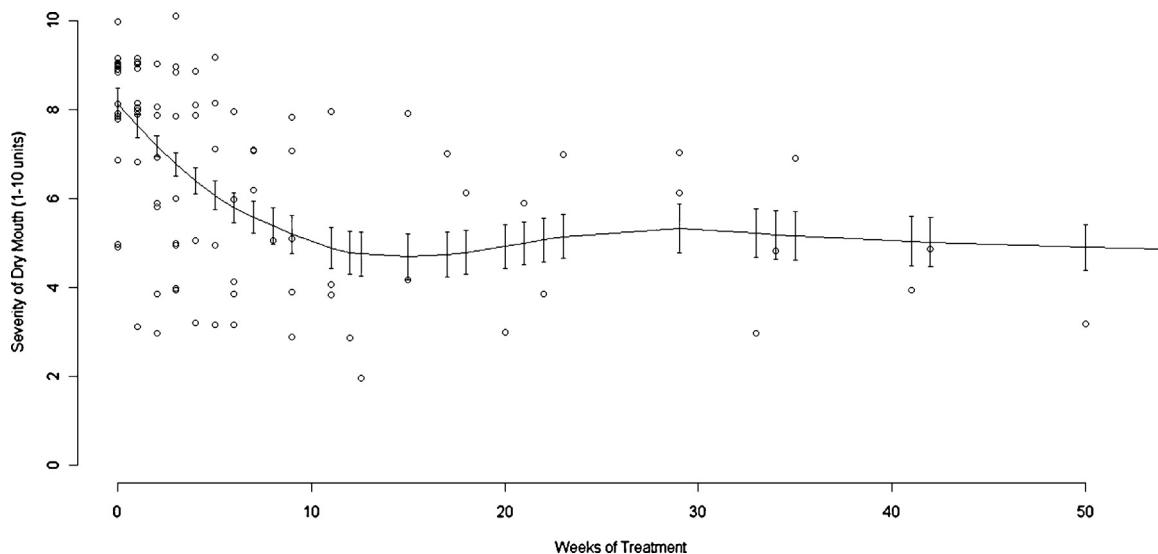


Fig. 2. Severity of dry mouth over the course of acupuncture treatment.

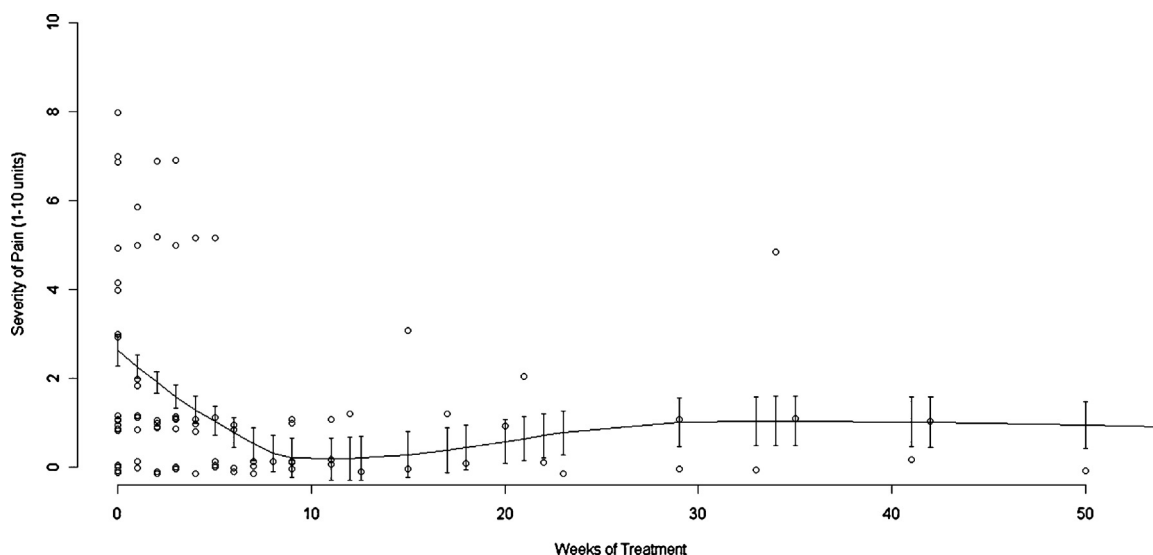


Fig. 3. Severity of pain over the course of acupuncture treatment.

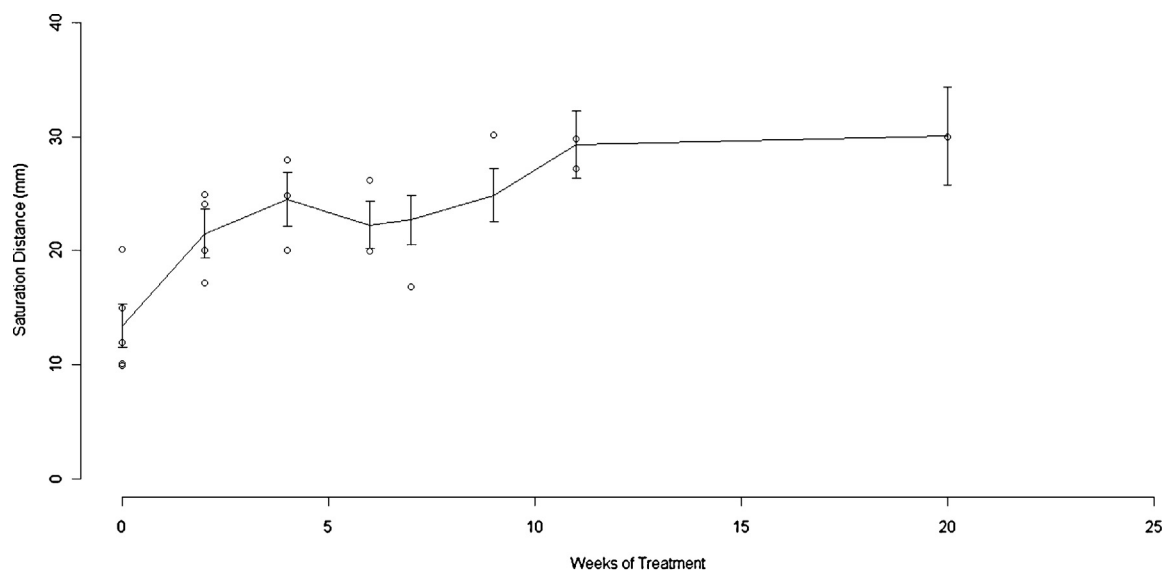


Fig. 4. Saliva production as measured using the Modified Schirmer's test over the course of acupuncture treatment.

not statistically significant ($p > 0.05$). The change in taste did not have a specific trend ($p > 0.05$).

Limited data was available for the MST, five subjects with a total of 18 data points. The average MST (Fig. 4) improved from 14.9 mm to 24.9 mm during the initial six weeks of treatment ($p < 0.001$). After six weeks, the MST average continued to trend upwards, however the improvement was not significant ($p = 0.059$).

4. Discussion

Results from this study demonstrated that combination acupuncture is a feasible and effective treatment for radiation-induced xerostomia. The severity of dry mouth and pain was reduced by 35% and 50%, respectively. Symptom improvement peaked at six weeks of treatment. This result was expected as the length of time between treatments was increased once patients reached a plateau in improvement, usually within the first four to eight weeks. Continued improvement of symptoms was observed with increasing time intervals between treatments, up to six months at the end of the data collection. Blom et al. reported similar

improvements six months after acupuncture treatment in patients with primary Sjogren's syndrome and secondary Sjogrens due to irradiation [16].

Previous studies on the effect of acupuncture on subjects with radiation-induced xerostomia have shown improvements in xerostomia and quality of life when compared to sham acupuncture and untreated groups [3,6,17]. Wong et al. recently published similar results in a study examining acupuncture-like transcutaneous electrical nerve stimulation versus pilocarpine in patients with radiation induced xerostomia [18].

This study observed a significant trend towards improvement in dry mouth when eating and difficulty swallowing and speaking. These findings may become statistically significant with a larger sample size. This observation is similar to previously reported studies using acupuncture to treat radiation-induced xerostomia in HNC patients [7,14]. In the initial six weeks of treatment, a moderate improvement of sleep was observed, however not statistically significant. After six weeks, a significant impairment of sleep was observed. This was unexpected and reasons for this finding are unknown.

The treatments effects of acupuncture on saliva production are inconsistently correlated with clinical improvement of xerostomia; however two studies performed on patients receiving active ongoing radiation treatment reported significant improvement in saliva production [6,7,17]. It has been acknowledged that the accuracy of MST measurement of saliva production is influenced by stress, hydration, stimulation, season, and time of day [9]. In this study, all acupuncture treatments were performed in the morning and patients were requested to refrain from eating or drinking the hour prior to their appointment. Saliva production plateaued after improving 42% during the first six weeks of treatment.

The mechanism of acupuncture in xerostomia is unclear and likely multifactorial. Acupuncture stimulation is known to affect both the central and peripheral nervous systems [4]. One theory is that acupuncture activates visceral sensory afferent and motor efferent neurons. The activation of these neurons releases neuropeptides that increase blood flow to salivary glands, increasing salivary production and possibly aiding gland tissue regeneration [4,7,19]. Our study utilized electrical and auricular acupuncture in addition to manual acupuncture to further enhance this effect. Electrical stimulation has been shown to significantly improve salivary production via proposed increases in local blood flow and mitogenic responses [18,20]. Auricular acupuncture is proposed to activate the parasympathetic nervous system increasing salivary flow. The above theories are explained using western medicine, however according to the acupuncture principle of traditional Chinese medicine, improvement of “Chi” in one or more of 12 main meridians is hypothesized to stimulate saliva production [13]. We suggest that the differences and possible additive benefit between manual, auricular and electro acupuncture account for combination acupuncture maximizing saliva production.

Limitations of this study include its retrospective nature and small sample size. Further studies with a control group, larger sample sizes, consistent duration of follow up, and the use of a validated xerostomia quality of life survey are needed to further investigate the use of combination acupuncture in the treatment of radiation induced xerostomia.

5. Conclusion

Results of this study demonstrate that combination acupuncture is feasible and effective in the treatment of radiation-induced dry mouth and pain in HNC patients. A long lasting relief of xerostomia, up to six months at the end of the data collection, was observed in this case series.

Funding

None.

Financial disclosures

None.

Acknowledgements

The authors acknowledge the Medical College of Wisconsin Physical Medicine and Rehabilitation Research Advisors for Cellular, Translational, and Outcomes Research (REACTORS) for their guidance in this research study.

References

- [1] Bernier J, Domenge C, Ozsahin M, Matuszewska K, Lefebvre JL, Greiner R, et al. Postoperative irradiation with or without concomitant chemotherapy for locally advanced head and neck cancer. *N Engl J Med* 2004;350:1945–52.
- [2] Guchelaar HJ, Vermes A, Meerwaldt JH. Radiation-induced xerostomia: pathophysiology, clinical course and supportive treatment. *Support Care Cancer* 1997;5:281–8.
- [3] Meng Z, Garcia MK, Hu C, Chiang J, Chambers M, Rosenthal DI, et al. Sham-controlled, randomised, feasibility trial of acupuncture for prevention of radiation-induced xerostomia among patients with nasopharyngeal carcinoma. *Eur J Cancer* 2012;48:1692–9.
- [4] Dawidson I, Angmar-Månsson B, Blom M, Theodorsson E, Lundeberg T. Sensory stimulation (acupuncture) increases the release of calcitonin gene-related peptide in the saliva of xerostomia sufferers. *Neuropeptides* 1999;33:244–50.
- [5] Pow EH, Kwong DL, McMillan AS, Wong MC, Sham JS, Leung LH, et al. Xerostomia and quality of life after intensity modulated radiotherapy vs. conventional radiotherapy for early-stage nasopharyngeal carcinoma: initial report on a randomized controlled trial. *Int J Radiat Oncol Biol Phys* 2006;66:981–91.
- [6] Meng Z, Garcia MK, Hu C, Chiang J, Chambers M, Rosenthal DI, et al. Randomized controlled trial of acupuncture for prevention of radiation-induced xerostomia among patients with nasopharyngeal carcinoma. *Cancer* 2012;118:3337–44.
- [7] Simcock R, Fallowfield L, Monson K, Solis-Trapala I, Parlour L, Langridge C, et al. ARIX: a randomized trial of acupuncture v oral care sessions in patients with chronic xerostomia following treatment of head and neck cancer. *Ann Oncol* 2013;24:776–83.
- [8] Johnson JT, Ferretti GA, Nethery WJ, Valdez IH, Fox PC, Ng D, et al. Oral pilocarpine for post-irradiation xerostomia in patients with head and neck cancer. *N Engl J Med* 1993;329:390–5.
- [9] O’Sullivan EM, Higginson IJ. Clinical effectiveness and safety of acupuncture in the treatment of irradiation-induced xerostomia in patients with head and neck cancer: a systematic review. *Acupunct Med* 2010;28:191–9.
- [10] Towler P, Molassiotis A, Brearley SG. What is the evidence for the use of acupuncture as an intervention for symptom management in cancer supportive and palliative care: an integrative overview of reviews. *Support Care Cancer* 2013;21:2913–23.
- [11] Garcia MK, McQuade J, Haddad R, Patel S, Lee R, Yang P, et al. Systematic review of acupuncture in cancer care: a synthesis of evidence. *J Clin Oncol* 2013;31:952–60.
- [12] O’Regan D, Filshie J. Acupuncture and cancer. *Auton Neurosci* 2010;157:96–100.
- [13] Xinnong C. Chinese acupuncture and moxibustion. 1st ed. Beijing: Foreign Languages Press; 1987.
- [14] Wu H, Wong K, Wang D. Relief of radiation-induced xerostomia with acupuncture treatment: a case presentation. *PM R* 2011;3:85–7.
- [15] Chen A, Wai Y, Lee L, Lake S, Woo SB. Using the modified schirmer test to measure mouth dryness, a preliminary study. *J Am Dent Assoc* 2005;136:164–70.
- [16] Blom M, Lundeberg T. Long-term follow-up of patients treated with acupuncture for xerostomia and the influence of additional treatment. *Oral Dis* 2000;6:15–24.
- [17] Braga FP, Lemos Junior CA, Alves FA, Migliari DA. Acupuncture for the prevention of radiation-induced xerostomia in patients with head and neck cancer. *Braz Oral Res* 2011;25:180–5.
- [18] Wong RK, James JL, Sagar S. Phase 2 results from radiation therapy oncology group study 0537: a phase 2/3 study comparing acupuncture-like transcutaneous electrical nerve stimulation versus pilocarpine in treating early radiation-induced xerostomia. *Cancer* 2012;118:4244–52.
- [19] Jedel E. Acupuncture in xerostomia: a systematic review. *J Oral Rehabil* 2005;32:392–6.
- [20] Blom M, Lundeberg T, Dawidson I, Angmar-Månsson B. Effects on local blood flux of acupuncture stimulation used to treat xerostomia in patients suffering from Sjögren’s syndrome. *J Oral Rehabil* 2007;20:541–8.