

## Management of Oral Lesions in Lesch-Nyham Syndrome

Romero Maroto M\* / Ruiz Duque C\*\* / Vincent G\*\*\* / Garcia Recuero I\*\*\*\* / Romance A\*\*\*\*\*

*Lesch-Nyhan Syndrome is a hereditary disorder that affects the way in which the body handles the production and breakdown of purines. One of its main characteristic is self-mutilation. We present a new appliance which allows healing to occur.*

**Keywords:** Lesch–Nyhan syndrome , self-harm ,self mutilation, appliance , prevention.

### INTRODUCTION

Lesch–Nyhan syndrome is a hereditary disorder that affects the way in which the body handles the production and decomposition of purines, one of the chemical agents that shape RNA and DNA molecules. Although the disorder had been observed previously, it was not until 1964 that Lesch and Nyhan first described the complete syndrome in two brothers.<sup>1</sup> This syndrome is characterized by an increase of uric acid levels in urine and blood and hypoxanthine-guanine phosphoribosyltransferase (HPRT) production deficiency.<sup>2</sup> This X-linked disorder, which has an incidence of 1/100,000 – 380,000, primarily affects males, whereas females are carriers. Despite this, some cases have been reported in woman.<sup>3,4</sup> There is no variation by race.<sup>3</sup>

Physical examination may show hyperreflexia, spasticity, choreoathetoid movements, compulsive self-destructive behavior, increased serum uric acid, increased excretion of uric acid in urine and decreased levels of HGP in cultured fibroblasts. The syndrome is sometimes not diagnosed until self-harm has begun at an age of one and a half or two years.<sup>2</sup> Recurrent infections and renal failure are the most common causes of death, with life expectancy limited to the second or third decade of life.<sup>5,6</sup>

An enzymatic study of cutaneous fibroblasts or amniotic fluid

cells can be used for diagnosis, and an ability to identify the hemizygote and heterozygote will provide a basis for a therapeutic approach.<sup>7</sup>

The self-harm or self-mutilation characteristic of Lesch–Nyhan syndrome has been defined as a deliberate destruction or alteration of the body without suicidal intention. Moreover, it tends to occur in conjunction with a variety of psychiatric disorders, as is also the case in other syndromes or developmental problems.<sup>8</sup> Thus, pediatric patients may also present self-harm in other syndromes such as Cornelia de Lange, Gilles de la Tourette's syndrome, Rett's syndrome, XXY syndrome,<sup>8</sup> autism, mental retardation, infections such as encephalitis or congenital malformations, multiple sclerosis<sup>9</sup> or congenital insensitivity to pain.<sup>10</sup> The area most frequently injured is the lower lip, though self-harm to the upper lip, tongue, fingers and shoulders is also common.<sup>5</sup>

The therapeutic aim in Lesch–Nyhan syndrome is to control self-harm by means of drugs such as allopurinol, carbamazepine and xanthine oxidase inhibitors, which prevent the renal formation of uric acid.<sup>5</sup> Other self-harm reducing treatments include physical restraint. In this regard, corporal restriction devices such as gauntlets and plastic boards for the arms do not eliminate lesions but reduce the potential for self-harm.<sup>5,6</sup> Moreover, dental extractions of temporary and permanent dentition,<sup>11</sup> rounding sharp teeth edges and devices with different designs have been used to avoid bite injuries.<sup>10,12,13</sup> In this regard, MacPherson has described the possibility of orthognatic surgery to generate an open bite in patients with chronic self-harm of the lip.<sup>14</sup>

### Case Report

A two-year-old boy previously diagnosed with Lesch–Nyhan syndrome with general symptomatology and fever (>38 C) for 3 days presented at the Emergency Department of the Pediatric Oral and Maxillofacial Surgery Department at the Hospital Universitario 12 de Octubre (Madrid, Spain).

Clinical examination showed bleeding ulcerative lesions, loss of substance and supuration on the tongue and lower left lip. The reason reported by the parents was repeated self-biting secondary to the metabolic disease. Likewise, self-harm injuries to the distal phalanges of both upper limbs and choreoathetoid movements with

\* Martin Romero Maroto, MD, DDS, PhD Professor and Chair, Department of Pediatric Dentistry and Orthodontics, Rey Juan Carlos University, Alcorcón, Madrid, Spain.

\*\* Carolina Ruiz Duque, DDS, Department of Pediatric Dentistry and Orthodontics Rey Juan Carlos University, Alcorcón, Madrid, Spain.

\*\*\* German Vincent, Laboratory Technician Madrid Spain

\*\*\*\* Ignacio García Recuero, MD, Hospital 12 de Octubre Department of Maxillofacial Surgery, Madrid, Spain

\*\*\*\*\* Ana Romance, MD, Hospital 12 de Octubre Department of Maxillofacial Surgery, Madrid, Spain

Send all correspondence to: Martin Romero Maroto, Science Health Faculty, Rey Juan Carlos University, Avda de Atenas S/N, 28922 Alcorcón, Madrid, Spain

Phone:+34 629444801

E-mail:: martin.romero@urjc.es

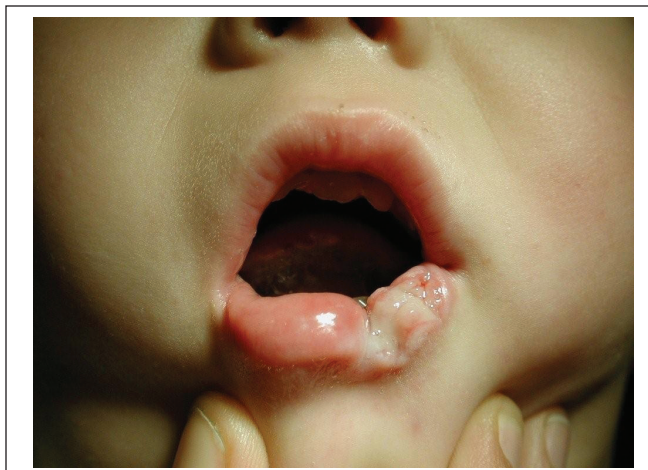


Figure 1. Lip wounds

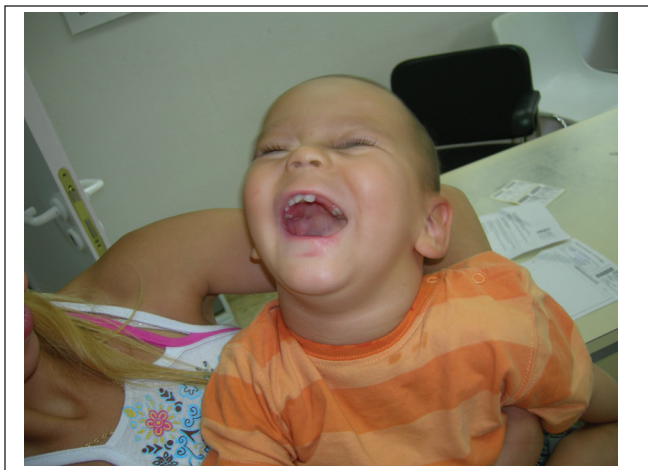

Figure 5. Wounds healed



Figure 2. Appliance Design

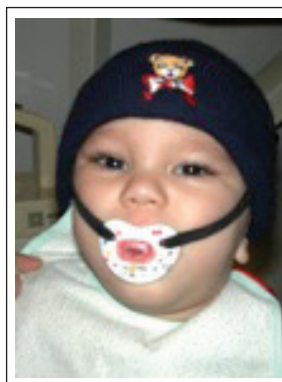


Figure 3. Appliance placed in the mouth

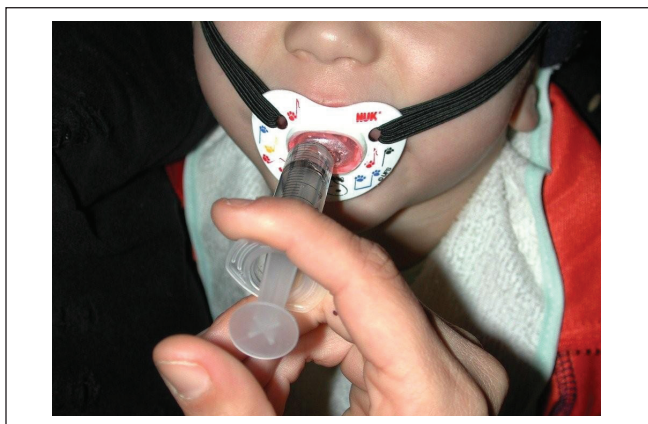

Figure 4. The appliance allows food intake

In order to prevent self-biting, and in cooperation with the Department of Pediatric Dentistry and Orthodontics at the University Rey Juan Carlos (Madrid, Spain), a device was designed using the external frame of a pacifier and fixing a transparent silicone splint (Odontoseal, Drève) to it with resin to cover both the upper and lower arch (Fig. 3). An anterior opening was made in the silicone splint to allow the ingestion of liquids and crushed food during treatment without having to remove the appliance (Fig. 4). In order to maintain the device in place, it was necessary to fix the device to the occipital region by adding two elastic bands sewn into a hat (Fig. 5). Once the family had been trained in using the device, the patient was discharged from hospital.

After one year of clinical follow-up no recurrence of the self-harm had been observed. Minimal aesthetic sequelae and no functional limitation (Fig. 6) were observed after wound healing.

### DISCUSSION

The child presented with a diagnosis of Lesch-Nyhan syndrome and an on-going treatment for this type of patient<sup>3,5</sup> established by the Department of Pediatric Neurology. The main reason for concern for the parents and physicians treating the child was the injuries to the tongue and especially the lower lip that were taking place and had not been prevented by medical treatment. These injuries coincided with those described by other authors for this syndrome.<sup>5,15</sup>

There are various treatment options for patients presenting self-harm behaviors, including extraction of the temporary dentition or, on occasions, opening of the incisal angles or use of oral devices. In this case it was not necessary to perform extractions as described by other authors<sup>5,16,17</sup> or to apply other treatments, such as crown amputations or pulpotomies, as reported by Lee, Berkowitz and Choi.<sup>18</sup>

None of the complications, such as fungal infections or demineralization of the enamel, previously reported by other authors were observed during use of our intraoral device with external attachments.<sup>3</sup> Furthermore, this device made the use of occlusal splints or restriction of the extremities described in other patients unnecessary,<sup>2,4</sup> thereby decreasing our patient's stress. The appliance designed by us performs the same functions as the buccal protector and lip bumper used by Cauwels and Martens,<sup>6,16</sup> thereby avoiding the possibility of soft tissue injury by the child.

hyperextension of the trunk were noted during examination in the Emergency Department.

The patient was being treated in the Department of Pediatric Neurology with allopurinol (50 mg/24 h), ural and urate (4-5 g/24 h), diazepam (2 mg/ml: 0.4 ml x 4 doses), ranitidine (75 mg/12 h), carbamazepine (200 mg/24 h), L-5-hydroxytryptophan (5 ml / 5 doses / 24 h) and levodopa/carbidopa (7 mg/kg/24 h) to prevent the self-harm injuries, with little therapeutic success. Prophylactic intravenous antibiotic treatment (amoxicillin and clavulanic acid) and rehydration were started, with successful resolution of the feverish symptoms.

Similarly to the occlusal resin plane device described by Fabbiano *et al*,<sup>9</sup> our device does not restrict mandibular movement, thereby facilitating its removal and allowing for good oral hygiene. Furthermore, no cooperation of the patient, which in this case would have been impossible, is required.

It was not necessary to use a denture fixative as in the case of Littlewood and Mitchell,<sup>10</sup> which lowered the risk of decalcification of the enamel and, like the buccal protector described by Sugahara and Mishima,<sup>13</sup> covered the teeth but with a harder material. The added advantage of our device is that the anterior opening allows food intake without the need to remove the appliance, thereby preventing injuries during chewing. It also allows the parents to easily remove the appliance to perform oral hygiene. The extraoral helmet, which is similar to that described by Evans *et al*<sup>16</sup> and Chen and Liu,<sup>19</sup> improved retention, thereby making removal by the child very difficult.

The design of these appliances for such patients must be personalized. In our case the treatment was successful and the wounds healed in a short period of time. As such, we believe that this device could be used to treat similar cases.

### CONCLUSION

Self-harm or self-mutilation is one of the main characteristics of Lesch-Nyhan syndrome. Injuries may be prevented using special devices to avoid self-biting. These devices may avoid the extractions of temporary and permanent teeth.

### REFERENCES

1. Lesch M, Nyhan WL. A familiar disorder of uric acid metabolism and central nervous system function. *Am J Med*; 36:561-70. 1964.
2. Smith BM, Cutilli BJ, Fedele M. Lesch-Nyhan syndrome. A case report. *Oral Surg Oral Med Oral Pathol*;78(3):317-8. 1994.
3. Fardi K, Topouzelis N, Kotsanos N. Lesch-Nyhan syndrome: a preventive approach to self mutilation. *Int J Paediatr Dent*;13:51-6. 2003.
4. Steadman RH, McIntosh G. Lesch-Nyhan Syndrome. *J Oral Maxillofac Surg*;40:750-2. 1982.
5. Cusumano FJ, Penna KJ, Panossian G. Prevention of self-mutilation in patients with Lesch-Nyhan syndrome: review of literature. *ASDC J Dent Child*;68(3):175-8. 2001.
6. Cauwels R, Martens LC. Self-mutilation behaviour in Lesch-Nyhan syndrome. *J Oral Pathol Med*;34:573-5. 2005.
7. Gorlin RJ, Cases AJ, Pindborg JJ, Cohen MM Editors. *Síndromes de la cabeza y del cuello*. 1<sup>st</sup> ed. Spain: Toray;:602-4. 1979.
8. Saemundsson SR, Roberts MW. Oral self-injurious behavior in the developmentally disabled: review and a case. *ASDC J Dent Child*;64(3):205-9, 228. 1997.
9. Fabbiano JA, Thines TJ, Margarone JE. Management of self-inflicted oral trauma: report of case. *Spec Care Dentist*;4(5):214-5. 1984.
10. Littlewood SJ, Mitchell L. The dental problems and management of a patient suffering from congenital insensitivity to pain. *Int J Paediatr Dent*;8(1):47-50. 1998.
11. LaBanc J, Epker BN. Lesch-Nyhan Syndrome: surgical treatment in a case with lip chewing. *J Max-Fac Surg*;9:64-7. 1981.
12. Romero M, Simón R, Garcia-Recuero JL, Romance A. Dental management of oral self-mutilation in neurological patients: a case of congenital insensitivity to pain with anhidrosis. *Med Oral Patol Oral Cir Bucal*;13(10):644-7. 2008.
13. Sugahara T, Mishima K, Mori Y. Lesch-Nyhan syndrome: successful prevention of lower lip ulceration caused by self-mutilation by use of mouth guard. *Int J Oral Maxillofac Surg*;23:37-8. 1994.
14. Macpherson DW, Wolford LM, Kotebein MJ. Orthognathic surgery for the treatment of chronic self-mutilation of the lips. *Int J Oral Maxillofac Surg*;21:133-6. 1992.
15. Dyck JL. Lesch-Nyhan syndrome: a treatment-planning dilemma. *Pediatr Dent*;4(2):127-30. 1982.
16. Evans J, Sirikumara M, Gregory M. Lesch-Nyhan syndrome and the lower lip guard. *Oral Surg Oral Med Oral Pathol*; 76:437-40. 1993.
17. Rashid N, Yusuf H. Oral self-mutilation by a 17-month-old child with Lesch-Nyhan syndrome. *Int J Paediatr Dent*; 7:115-7. 1997.
18. Lee JH, Berkowitz RJ, Choi BJ. Oral self-mutilation in the Lesch-Nyhan syndrome. *ASDC J Dent Child*; 69:66-9. 2002.
19. Chen LR, Liu JF. Successful treatment of self-inflicted oral mutilation using an acrylic splint retained by a head gear. *Pediatr Dent*;18(5):408-10.1996.

